

Skeletal Biology of Human Remains  
from La Tolita,  
Esmeraldas Province, Ecuador

*Douglas H. Ubelaker*



SMITHSONIAN INSTITUTION PRESS

Washington, D.C.

1997

## ABSTRACT

Ubelaker, Douglas H. *Skeletal Biology of Human Remains from La Tolita, Esmeraldas Province, Ecuador. Smithsonian Contributions to Anthropology*, number 41, 53 pages, 28 figures, 31 tables, 1997.—Although much of the archeological site of La Tolita has been destroyed by decades of looting, excavations begun in 1982 by the Banco Central of Quito, Ecuador, located undisturbed areas and recovered relatively large samples of human remains representing both primary and secondary burials from various areas of the site. These generally can be dated within the La Tolita Temprano (600 BC to 200 BC), La Tolita Clásico (200 BC to 90 AD), and the La Tolita Tardío (90 AD to 400 AD) periods.

Analysis indicated at least 88 individuals to be present: 7 Temprano, 32 Clásico, and 49 Tardío. Evidence for limited cranial deformation, flesh removal and dismemberment, and manufacturing artifacts from human bone were detected. The temporal transition from Clásico to Tardío involved reduction of trauma, dental caries, the ratio of immatures to adults, the male mean age at death, and periosteal lesions, coupled with increases in living stature, porotic hyperostosis, congenital disorders, and enamel hypoplasia. Compared to other archeologically recovered samples from early Ecuador, the La Tolita remains indicate a well-nourished, healthy population who experienced high levels of skeletal trauma.

OFFICIAL PUBLICATION DATE is handstamped in a limited number of initial copies and is recorded in the Institution's annual report, *Annals of the Smithsonian Institution*.

---

### Library of Congress Cataloging-in-Publication Data

Ubelaker, Douglas H.

Skeletal biology of human remains from La Tolita, Esmeraldas Province, Ecuador / Douglas H. Ubelaker.

p. cm.—(Smithsonian contributions to Anthropology ; no. 41)

Includes bibliographical references.

1. Tumaco La Tolita Sites (Colombia and Ecuador) 2. Indians of South America—Anthropometry—Ecuador—Esmeraldas (Province) 3. Indians of South America—Ecuador—Esmeraldas (Province)—Antiquities. 4. Human remains (Archaeology)—Ecuador—Esmeraldas (Province) 5. Esmeraldas (Ecuador : Province)—Antiquities. I. Title. II. Series.

GN1.S54 no. 41

[F3721.L1E75]

599.9'4/0986635—dc21

97-12972

CIP

© The paper used in this publication meets the minimum requirements of the American National Standard for Permanence of Paper for Printed Library Materials Z39.48—1984.

# Contents

	<i>Page</i>
Preface . . . . .	vi
Introduction . . . . .	1
Excavated Areas within La Tolita . . . . .	4
Area La Tola Mango (600 BC to 200 BC) (Temprano) . . . . .	4
Area La Tola del Pajarito (600 BC to 75/90 AD) . . . . .	4
Area El Mango Montaña (200 BC to 400 AD) . . . . .	8
Pozo Iglesia (200 BC to 90 AD) (Clásico) . . . . .	25
Pozo Letrina Wagner (Clásico) . . . . .	29
Sector H9 (Clásico) . . . . .	29
Area Tola de la Balsa (Temprano and Clásico) . . . . .	29
Area Cabezas (Clásico) . . . . .	29
Undated Material . . . . .	29
Demographic Profiles . . . . .	31
Antemortem Cultural Influences of the Skeleton . . . . .	33
Cranial Deformation . . . . .	33
Metatarsophalangeal Alterations . . . . .	35
Postmortem Skeletal Alterations . . . . .	35
Rodent Tooth Marks . . . . .	35
Cut Marks . . . . .	35
Bones as Tools . . . . .	35
Measurements and Developmental Characteristics . . . . .	35
Cranium and Mandible . . . . .	35
Stature . . . . .	37
Pathology . . . . .	39
Antemortem Trauma . . . . .	39
Infectious Disease . . . . .	39
Porotic Hyperostosis . . . . .	40
Degenerative Changes . . . . .	40
Congenital Disorders . . . . .	42
Deciduous Dentition . . . . .	43
Permanent Dentition . . . . .	43
Isotope Analysis . . . . .	47
Summary . . . . .	49
Literature Cited . . . . .	52

## FIGURES

1. Location of La Tolita site, Esmeraldas Province, Ecuador . . . . .	2
2. Pathological cervical vertebrae of Tola Pajarito 2a . . . . .	5
3. Abnormal porosity on the superior surface of the centrum of the fourth cervical vertebra from Tola Pajarito 2a . . . . .	5
4. Abnormal porosity on the superior surface of the centrum of the seventh cervical vertebra from Tola Pajarito 2a . . . . .	5
5. Moderately remodeled periosteal lesion on right tibia, Tola Pajarito 4a . . . . .	6
6. Superior view of cranium from Tola Pajarito 4a . . . . .	7
7. Pointed bone fragment from Tola Pajarito V-6, Prof. 243 . . . . .	8

8. Well-remodeled Colles fracture on distal left radius compared to normal distal right radius, Mango Montaña, Feature 3 . . . . .	10
9. Extensive occlusal attrition, Mango Montaña, Feature 3 . . . . .	10
10. Superior view of calvarium from Mango Montaña, E-7 . . . . .	12
11. Lateral view of calvarium from Mango Montaña, E-7 . . . . .	13
12. Posterior view of calvarium from Mango Montaña, E-7 . . . . .	14
13. Fused talus and calcaneus, Mango Montaña, D-2 . . . . .	16
14. Cut edge of tibia from N4-3, Prof. 180 . . . . .	16
15. Exposed trabeculae of sheared surface, N4-3, Prof. 180 . . . . .	17
16. Secondary deposit of bones within the Cama, Mango Montaña . . . . .	20
17. Secondary deposit of bones within the Cama, Mango Montaña . . . . .	20
18. Artifact made from human bone, Mango Montaña Cama, 161 . . . . .	22
19. Incised design on distal end of human bone artifact, Mango Montaña Cama, 161 . . . . .	23
20. Perimortem incision on ventral surface of cervical vertebra centrum, Mango Montaña Cama, 96 . . . . .	25
21. Parallel incisions on the inferior aspect of a cervical vertebra, spinous process, Mango Montaña Cama, 96 . . . . .	26
22. Incisions on left femur, Mango Montaña Cama, 127 . . . . .	27
23. Patterned fracture on femoral head, Mango Montaña Cama, 119 . . . . .	28
24. Lesion of left femur of Mango Montaña Cama, 164 . . . . .	30
25. Cribra orbitalia in orbits of child, Mango Montaña Cama, 120 . . . . .	31
26. Location of archeological sites in Ecuador yielding samples of human remains . . . . .	34
27. Inverted maxillary right third molar, Mango Montaña Cama, 189 . . . . .	43
28. Moderate calculus on maxillary right deciduous second molar and hypoplasia on permanent first premolar . . . . .	47

## TABLES

1. Demographic information derived from the La Tolita samples . . . . .	32
2. Archeologically recovered samples of human skeletal remains from Ecuador . . . . .	32
3. Demographic characteristics of samples from Ecuador . . . . .	33
4. Measurements (in mm) of metatarsals and proximal first foot phalanges lacking alterations in La Tolita samples . . . . .	35
5. Cranial and mandibular measurements (in mm), Temprano period . . . . .	36
6. Nonmetric observations, Temprano period . . . . .	36
7. Cranial and mandibular measurements, Clásico period . . . . .	36
8. Nonmetric observations, Clásico period . . . . .	36
9. Cranial and mandibular measurements (in mm), Tardío period . . . . .	37
10. Nonmetric observations, Tardío period . . . . .	37
11. Estimates of living stature (in cm) in La Tolita samples . . . . .	38
12. Comparison of stature estimates (in cm) derived from samples from Ecuador . . . . .	38
13. Antemortem trauma from La Tolita samples . . . . .	38
14. Trauma and periosteal lesions: Ratios of number of bones with lesions to numbers of adults and all individuals . . . . .	39
15. Periosteal lesions in the La Tolita samples . . . . .	40
16. Ratio of bones with porotic hyperostosis to the number of individuals in the sample . . . . .	40
17. Vertebral osteophytosis at La Tolita . . . . .	41
18. Arthritic lipping of joint-surface margins in La Tolita samples . . . . .	41
19. Arthritic porosity in joint surfaces of the tibia, fibula, and calcaneus in La Tolita samples . . . . .	42

20. Arthritic porosity in joint-surface margins of the humerus, radius, ulna, and femur in La Tolita samples . . . . .	42
21. Spicule formation in La Tolita samples . . . . .	42
22. Inventory of permanent teeth present in La Tolita samples . . . . .	44
23. Antemortem permanent tooth loss in La Tolita samples . . . . .	44
24. Permanent teeth with carious lesions in La Tolita samples . . . . .	45
25. Frequencies of permanent teeth with carious lesions, associated abscesses, and hypoplasia and those lost antemortem in samples from Ecuador . . . . .	46
26. Permanent teeth with associated alveolar abscesses in La Tolita samples . . . . .	46
27. Calculus on the lingual surfaces of permanent maxillary teeth in La Tolita samples . . . . .	48
28. Calculus on the lingual surfaces of permanent mandibular teeth in La Tolita samples . . . . .	48
29. Calculus on the buccal surfaces of permanent maxillary teeth in La Tolita samples . . . . .	49
30. Calculus on the buccal surfaces of permanent mandibular teeth in La Tolita samples . . . . .	50
31. Permanent teeth with hypoplasia in La Tolita samples . . . . .	50

## Preface

In 1986, I accepted the invitation of Dr. Francisco Valdez of the Banco Central of Ecuador to study the recently excavated remains from La Tolita. At the time, I already had completed analysis of many other Ecuadorean samples mostly from the coast and highland area around Quito and was interested in learning how the new data from the northern coast would fit into the emerging pattern.

The initial work in 1986 was conducted outside of Quito in family property where I was able to convert a functioning sculpture studio into a skeletal laboratory. Analysis in later years on La Tolita materials took place in family property within Quito (1988) and in the archeological laboratories of the Banco Central (1989). I am especially grateful to the families of the late Jaime Andrade Moscoso and Jaime Andrade Heyman of Quito for making their property available for my work and for their continual assistance on the project. The staff of the Banco Central of Quito also provided facilities, perspective, and archeological information needed for interpretation. The following staff of the La Tolita project were especially helpful: Francisco Valdez, Maria Soledad Leiva, Alexandra Yopez, Eugenia Rodriguez, and Maria Clara Montaña. Maria Teresa Pareja R. of Quito assisted with the analysis in 1988 and facilitated the fluoride analysis of water samples in 1988 and 1989. I also acknowledge research assistant Erica Jones of the Department of Anthropology, National Museum of Natural History, Smithsonian Institution, Washington, D.C., for her assistance in data analysis and manuscript preparation. Marcia Bakry, also of the Department of Anthropology, skillfully prepared the artwork and related illustrations.

My family, Maruja Andrade de Ubelaker, Max, and Lisa also helped immeasurably by allowing me the time away from them to complete this work and facilitating in many other ways. In particular, Max helped sift, wash, and sort much of the material from La Tolita.

In 1988, I published a preliminary report on the La Tolita analysis completed during 1986. The concern in publishing such a report is that the later complete report will contradict or differ from the earlier one in embarrassing ways. Thus, it is somewhat gratifying to note that the biological perspective presented in the preliminary report is largely substantiated by the fuller data reported here.

As noted above, the initial analysis in 1986 (reported on in 1988) was conducted on family property outside of Quito. When the analysis was completed, the remains were repacked into the original boxes and transported back to Quito with the intention of delivering them back to the Banco Central in Quito. Realizing that personnel at the Bank likely would not be there to receive them in midday, I decided to stop in Quito for lunch with the family. I returned to the vehicle after lunch to discover that in my absence someone had broken in through the rear door and stolen all of the boxes. The remains had been packed in used cardboard boxes that carried the labels of various electronic equipment. Undoubtedly the thief thought he was stealing electronics. Despite various formal public appeals, sadly the remains were never recovered. Our only consolation was to imagine the look on the faces of the culprits when they opened the boxes.

# Skeletal Biology of Human Remains from La Tolita, Esmeraldas Province, Ecuador

*Douglas H. Ubelaker*

## Introduction

The central archeological site of La Tolita is located on an island at the mouth of the Santiago river in Esmeraldas Province, Ecuador, about three kilometers from the Pacific Ocean. The immediate environment consists primarily of mangrove near the water and tropical forest elsewhere (Valdez, 1987). According to Valdez (1986:83), the geographic position of the site is north latitude 1 degree 10' and west longitude 79 degrees (Figure 1).

The importance of the archeological site of La Tolita, as a center for trade, metal-working, and mortuary ritual has long been recognized (Saville, 1910; Uhle, 1927; Ferdon, 1940-1941). Unfortunately, artifacts of precious metals and ceramics at the site have for decades lured looters who have destroyed many of the archeological resources. Thousands of human skeletons have been removed in the last few decades in the search for saleable artifacts. In 1982, the Museum of the Banco Central of Quito, Ecuador, initiated archeological excavations in the area as part of a plan to create an archeological park and to learn as much as possible about the precolumbian history of the area (Valdez, 1987). These excavations succeeded in locating and excavating undisturbed areas of the site, recovering artifacts and human remains. In 1986, the author was invited by staff of the La Tolita project of the Banco Central to study the human remains and to integrate the recovered biological information with the emerging cultural picture of life at La Tolita in ancient times.

Analysis of the human remains began in August of 1986 and continued during August of 1988, July of 1989, and August of

1990. In March of 1988, a preliminary report of the analysis completed by that time was published (Ubelaker, 1988a). Data from that report are included herein, along with information gathered during 1988, 1989, and 1990. By the time of analysis, most of the materials had been cleaned by project personnel and were transported to Quito. In 1986, all materials were further processed and studied in a makeshift laboratory outside of Quito. In subsequent years, all this work was completed in Quito, mostly at the project laboratory in the Banco Central.

Once the remains were cleaned (usually washed) and dried, an inventory was conducted of the skeletal content of each designated feature. Data were then collected on age at death, sex, evidence of disease, and other morphological information using procedures outlined by Ubelaker (1981, 1989). Photographs and radiographs were taken of selected bones and details.

According to project staff, the human remains were mostly recovered from four areas tested by the excavations: Tola Mango, Tola Pajarito, Mango Montañón, and Pozo Iglesia. Remains from these areas are associated with three chronological periods: Tolita Temprano (600 BC to 200 BC), Tolita Clásico (200 BC to 90 AD), and Tolita Tardío (90 AD to 400 AD). Small quantities of human remains also were recovered from additional geographical areas within La Tolita. These areas also are summarized and discussed in this monograph. Within each geographical area, the archeologists recognized and defined individual cultural units (features) of interest. This monograph reports only on the burial features. Each burial feature is labeled here with the summary information provided about it by the responsible archeologists.

The earliest occupation at La Tolita producing samples of human remains is termed La Tolita Temprano and represents the Late Formative. On the island of La Tolita, this early occupation marks the beginning of a ceramic tradition and is otherwise characteristic of coastal Late Formative culture (Valdez, 1987:14).

---

*Douglas H. Ubelaker, Department of Anthropology, National Museum of Natural History, Smithsonian Institution, Washington, DC 20560. Review Chairman: Dennis Stanford, Smithsonian Institution. Reviewers: Doug Owsley, Department of Anthropology, Smithsonian Institution, and two anonymous reviewers.*

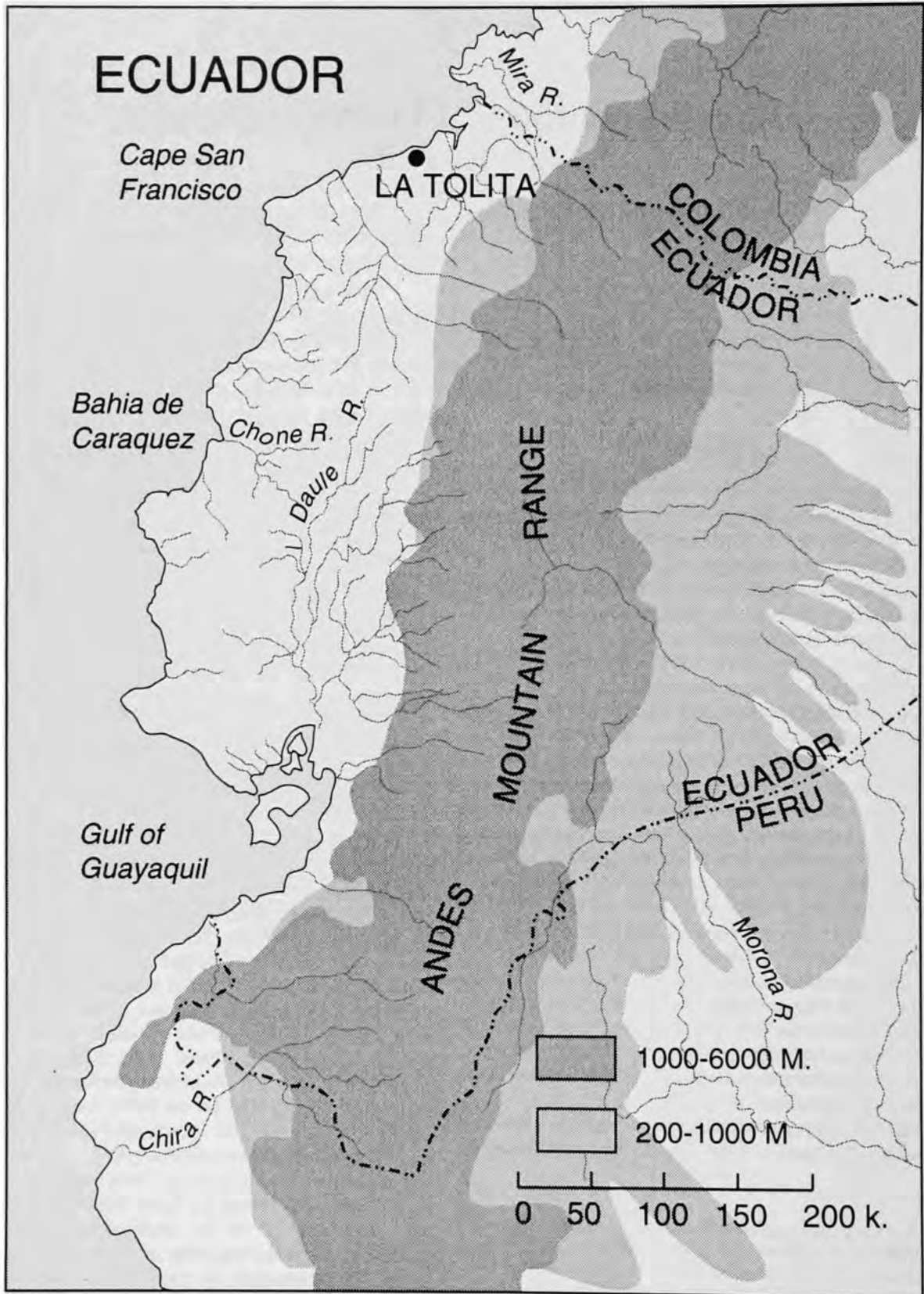


FIGURE 1.—Location of La Tolita site, Esmeraldas Province, Ecuador.



According to Valdez (1987:17; 1989), La Tolita Clásico represents a period of increased population density, urban specialization, agricultural intensification, and expanding cultural influence within the region. La Tolita likely functioned as a ceremonial center during this period. The burial features associated with this period probably date from about 200 BC to 75/90 AD.

The burial features of La Tolita Tardío likely date from about 90 AD to 400 AD (Valdez, 1986; 1987:33). Valdez (1987, 1989) regards this period as one of decline, culminating in abandonment of the site.

Remains linked culturally to Tolita Temprano (600 BC to 200 BC) are confined to one burial feature from Tola Pajarito (U1.2 Prof. 2, 98–3.05 m), one from Tola de la Balsa (1-TB-T1), and those from Tola Mango. ("Prof." refers to depth, and the numbers are reported in centimeters, unless otherwise noted. "Nivel" refers to the level at which specimens were found.) Those dated to the Tolita Clásico period (200 BC to 90 AD) are all features from Tola Pajarito except the earlier one listed above, some features from Mango Montaña, and those from Pozo Iglesia, Pozo Letrina Wagner, Sector H9, one feature from Area Tola de la Balsa, and Area Cabezas. Features dating to the Tolita Tardío period (90 AD to 400 AD) are confined to those from Mango Montaña that have not been assigned to the earlier Clásico period.

This analysis presents information on each of the burial features and compares biological data from the major site areas. For broader comparisons with other samples from Ecuador, these data are grouped chronologically.

The listing of each feature presents the summary information available on associated labels, as observed at the time of analysis. This information is followed by the chronological assessment, provided by project archeologists. If all features and labels within an area of the site are chronologically assessed the same, then the chronological assessment follows the name given to the area of the site and is not repeated with each individual description. Such is the case with La Tola Mango (Temprano), Pozo Iglesia (Clásico), Pozo Letrina Wagner (Clásico), Sector H9 (Clásico), and Cabezas (Clásico). The remaining areas contained materials of mixed chronology, thus the chronological assessment of each feature, or bone lot, is listed individually.

Note also that a separate numbering system is included at the end of the label of most features. In this three-component numbering system, the first number is that assigned to the feature or bone assemblage. The second number refers to the area of the site in which the materials were excavated. The third number indicates the chronological period to which the bones are assigned. Period T1 corresponds to "Temprano," T2 to "Clásico," and T3 to "Tardío." The new classification labels were developed in 1994 by La Tolita Project personnel and were provided to the author in August of 1994. New labels were not available for all features, but are listed in the text as appropriate.

Detailed archeological information about the burial features, the dating, recovered artifacts, and the site are available elsewhere (Leiva and Montaña, 1994) and are largely not repeated herein. In 1986, Valdez published an article in *Miscelánea Antropológica Ecuatoriana* summarizing research results at La Tolita at the time. The report discussed the history of work at the site, the goals of the archeological project, the archeological approach utilized, and the stratigraphic context of human remains, especially at the artificial mounds of "El Mango" and "La Tola del Pajarito." Figures in Valdez, 1986, present a map of the site, showing areas investigated in 1983, the site map made by Max Uhle in 1925, the site map made by Edwin Ferdon in 1940, and eight others depicting drawings of various archeological site details.

In 1987, Valdez published a small monograph on the archeological project at La Tolita. This publication included more detailed site maps than published previously, as well as descriptions, photographs, and interpretations of individual features and artifacts recovered. All features were dated through careful stratigraphic control, assessment of artifacts, and radiocarbon dates. Five previously recorded radiocarbon dates were considered, along with 19 new dates generated for the project by the laboratory of Geochron, Krueger Enterprises, Inc. of Cambridge, Massachusetts, in the chronological dating of the site.

In 1989, the Museo del Banco Central in Quito published a public-oriented volume (Valdez et al., 1989) on La Tolita in association with an exhibition of materials recovered from the site. This publication includes articles by Valdez on chronological interpretation of the site, Rosángela Adoum and Valdez on metallurgy at La Tolita, María Soledad Leiva on motifs of religious symbolism at La Tolita, and Eugenia Rodríguez and Valdez on the history of the area.

Responsibility for the production of a final archeological report in the La Tolita project was assigned to María Clara Montaña and María Soledad Leiva of the Banco Central staff in Quito. Their final report, presented for publication to authorities of the Banco Central del Ecuador in Quito, further supplements the archeological information available in the previously cited publications (Leiva and Montaña, 1994).

The data presented herein include detailed inventory of human remains present. Techniques of estimating age at death and sex follow those recommended by Bass (1987) and Ubelaker (1989). All observations and measurements follow guidelines established by Ubelaker (e.g., 1980a,b; 1981; 1983; 1988b) in previous studies of Ecuadorean samples.

All estimates of living stature from long bone lengths of the tibia and femur were made utilizing the regression equations and procedures of Genovés (1967:76). These formulae were derived from studies of Mexican cadavers classified as "indigenous." Stature estimates from all other bones were generated using the Trotter formulae for Mexican males (Ubelaker, 1989:61).

### Excavated Areas within La Tolita

#### AREA LA TOLA MANGO (600 BC to 200 BC) (TEMPRANO)

*Prof. 275 (3-TM-T1):* Only one complete mandible of a 35- to 55-year-old female is present.

*Prof. 262-267 (2-TM-T1):* Only one fragmentary eroded adult tibia and one infant (newborn) right tibia are present.

*Unidad A, Prof. 305-310 (6-TM-T1):* Only a right scapula and right talus from a 20- to 30-year-old female are present.

*Unidad A, Prof. 289-294, (5-TM-T1):* A thoracic vertebra from a 25- to 30-year-old adult is present.

*Pozo Control, Prof. 228-254, piso tiestos (1-TM-T1):* Only a distal tibia fragment from a 20- to 40-year-old adult of undetermined sex is present.

*Prof. 276-281 (4-TM-T1):* Present are a tibia fragment and a left clavicle from a 20- to 35-year-old male. The tibia fragment shows well-remodeled periosteal apposition on a 38 mm area of this fragment measuring 118 mm in length.

*Unidad F-G, Prof. 309, Ent. Niño (7-TM-T1):* This feature is represented by a fragmentary cranium and the following bones: left ulna, tibia, right temporal, left mandible, fragments of nine ribs, and three vertebral arches (one first cervical, one other cervical, and one thoracic).

The extent of dental formation suggests an age at death of about 18 months.

The tibia displays an incomplete layer of periosteal new bone over most of the shaft.

*Mixed/Disturbed (8-TM-T1):* Only the following fragmentary adult bones are present: left and right femur and left tibia. The maximum head diameter of the left femur of 45 mm suggests male sex. The size of the bones and lack of arthritic changes suggest an age at death between 20 and 26 years. The estimated length of the left femur of 423 mm suggests a living stature of about 162 cm (5 ft, 4 in) using the male formula of Genovés (Ubelaker, 1989:62).

Three animal bones also are present. Two of these are vertebrae and are modified by incisions extending around the circumference of the bones.

#### AREA LA TOLA DEL PAJARITO (600 BC to 75/90 AD)

*U1-2 (298-305 cm) (Temprano) (1-TP-T1):* Most of these remains represent an adolescent or young adult male, probably about 19 years old at death. A second adult is represented only by one left femur. The following bones are present: a calvarium, mandible, both humeri, right radius, both ulnae, two left and one right femur, one left and one right tibia, fibula fragments, both clavicles, both scapulae, the gladiolus, manubrium, both innominates, both patellae, all seven cervicals, ten thoracics, five lumbar, the sacrum, left hand navicular, both lunates, both greater multangulars, right lesser multangular, left capitate, left hamate, all five left metacarpals, right second and fifth metacarpals, seven proximal hand phalanges, eight middle hand phalanges, three distal hand phalanges, both calcanea,

both tali, right cuboid, both foot naviculars, the left second cuneiform, both first metatarsals, right third metatarsal, left fifth metatarsal, one proximal first foot phalanx, three other proximal foot phalanges, one distal first foot phalanx, and 12 ribs.

Most of the iliac crest is not united. The epiphyses for the femoral heads are united, but with a well-marked line of union. The epiphysis for the distal humerus is united, but the proximal epiphysis is not. Collectively, the data suggest an age at death of about 19 years.

The form of the pubis suggests male sex.

The right tibia midshaft shows fine porosity and new unre modeled bone deposits over an area of the medial surface approximately 10 by 30 mm.

Estimated length of a femur of the 19 year old individual of 400 mm suggests a living stature of about 157 cm (5 ft, 2 in). The extra femur appears to represent an adult male. The length of this femur of 460 mm suggests a living stature of about 170 cm (5 ft, 7 in). Both estimates were calculated using Genovés' formula for Mexican males (Ubelaker, 1989:62).

*Feature 1a (RQ2, 714 cm) (Clásico) (1-TP-T2):* This skeleton of a child is generally complete with excellent preservation. Nearly all bones are present with minimal fragmentation. The stage of dental formation suggests an age at death of between 4.5 and 5.0 years. The cranial occipital shows some flattening, suggesting deformation. No reliable estimate of sex can be made and no evidence of disease is present. The teeth lack evidence of caries, but they do show a blackish stain. The crowns of the maxillary canines show buccal pitting that appears to represent a form of hypoplasia. Slight dental calculus occurs on one maxillary molar and one mandibular molar. Maximum lengths (mm) of the following bones were recorded: left ilium, 76; right ilium, 76; left femur, 203; left tibia, 166; left radius, 109; left humerus, 150; left ulna, 122; left clavicle, 73; and right clavicle, 74. Other measurements (mm) are height of the ascending ramus of the mandible, 37; corpal length, 60; minimum breadth of the ascending ramus, 28; height of the mandibular symphysis, 21; bigonial diameter, 79; and bicondylar diameter, 99.

One adult premolar tooth also is present. The tooth lacks dental caries but shows large calculus deposits on its buccal surface and moderate deposits on its lingual surface. The occlusal surface of the tooth shows some initial dentin exposure due to attrition.

*Feature 2a (RQ2, 3-715 cm) (Clásico) (2-TP-T2):* This adult skeleton is generally complete and well preserved. Maximum diameters of the heads of the femora and humeri of 48 mm, as well as morphological data on the pubis and skull, strongly suggest male sex.

Maximum lengths of the left ulna (260 mm), right ulna (264 mm), and left radius (240 mm) suggest a living stature of about 167 cm (5 ft, 6 in), using Trotter's formulae for Mexican males (Ubelaker, 1989:61). Muscle markings on the bones further suggest the individual was quite robust.



FIGURE 2.—Pathological cervical vertebrae of Tola Pajarito 2a.

Morphology of the pubic symphysis, extent of dental attrition, closure of cranial sutures, and extent of osteophytosis and joint changes collectively suggest an age at death of between 32 and 37 years.

Evidence of skeletal disease is confined to the cervical vertebrae (Figure 2). Slight degenerative pitting is present on the inferior body surface of the third cervical vertebra, the superior body surface of the fourth cervical vertebra (Figure 3), and the superior body surface of the seventh cervical vertebra (Figure 4). Marked destruction and remodeling occurs on the inferior body of the fifth cervical vertebra and the superior surface of the sixth cervical vertebra. Although the thoracic and

lumbar vertebrae appear normal, the bony changes in the cervicals produce a marked kyphosis in that area. The appearance of the bony changes both in the gross bone and in the radiographs suggest a traumatic origin, at least several years before death.

The 25 teeth present lack dental caries but show moderate to large calculus deposits. Some dentin exposure resulting from

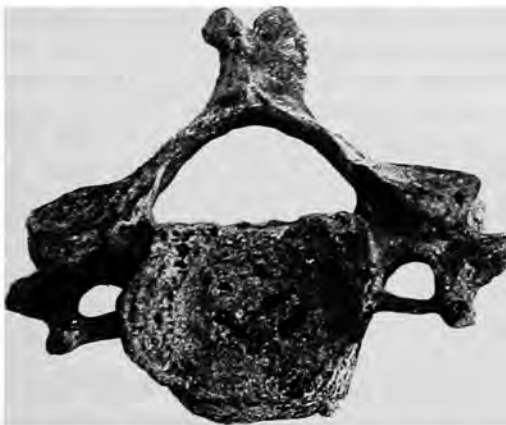

FIGURE 3.—Abnormal porosity on the superior surface of the centrum of the fourth cervical vertebra from Tola Pajarito 2a.

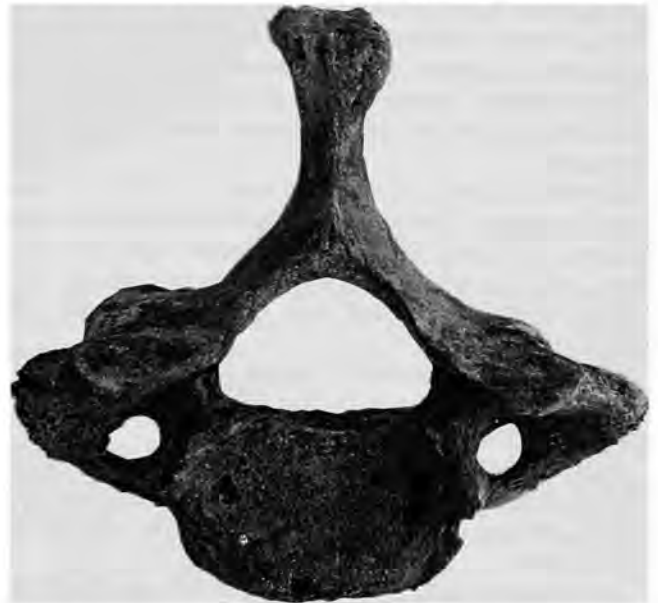

FIGURE 4.—Abnormal porosity on the superior surface of the centrum of the seventh cervical vertebra from Tola Pajarito 2a.



FIGURE 5.—Moderately remodeled periosteal lesion on right tibia, Tola Pajarito 4a.

attrition occurs on most teeth. A large well-remodeled depression on the lingual alveolus in the area of the missing mandibular right lateral incisor and canine probably results from an alveolar abscess at that site. No hypoplastic teeth are present; however, the maxillary right first molar appears anomalous, rounder than normal with a slight division through its longitudinal axis.

The skull lacks evidence of disease and deformation. The following measurements (mm) were recorded: auricular height, 113; porion-bregma, 112; cranial length, 183; cranial breadth, 145; minimum frontal breadth, 97; bicondylar breadth, 111; bigonial breadth, 96; height of ascending ramus, 64; minimum breadth of ascending ramus, 29; height of mandibular symphysis, 34; and corpal length, 80. A mylohyoid bridge was present on the right but not on the left. The following features were all absent: accessory mental foramen, frontal grooves, supra-orbital foramen, wormian bones, parietal process of temporal squama, squamoparietal synostosis, auditory exostoses, marginal foramen of the tympanic plate and tympanic dehiscence.

*Feature 3a (PQ3, 725 cm) (Clásico) (3-TP-T2):* This secondary deposit consists of the following adult bones: right humerus, both radii, left ulna, both femora, right tibia, one fibula, right clavicle, both scapulae, both innominates, two lumbar vertebrae, the skull and mandible, and the left calcaneus.

Female sex is suggested by femoral head diameters of 42 mm, a wide sciatic notch on one innominate, and general gracility of the long bones.

An age at death of between 27 and 32 years is suggested by the lack of union of the cranial sutures, lack of osteophytosis, and the presence of some dentin exposure of the teeth due to dental attrition.

An estimated length of the left femur of 394 mm suggests a living stature of about 152 cm (5 ft) using the formulae for females provided by Genovés (1967:76).

The fibula shows a well-remodeled periosteal lesion at the

midshaft. A slight, well-remodeled depressed fracture is located on the midline of the frontal, about 40 mm below bregma. There also is a small reactive lesion about 11 mm in diameter on the right parietal 15 mm from the sagittal suture and 70 mm from the coronal suture.

The nine teeth present lack dental caries and show slight to medium deposits of calculus. No examples of hypoplasia or alveolar abscess were observed.

The following measurements (mm) were recorded from the undeformed skull and mandible: cranial length, 170; cranial breadth 141, minimum breadth of the ascending ramus, 31. The following features were absent: mylohyoid bridge, accessory mental foramen, frontal grooves, supra-orbital foramen, infraorbital suture, wormian bones, parietal process of temporal squama, squamoparietal synostosis, auditory exostosis, marginal foramen of tympanic plate, and tympanic dehiscence.

*Feature 4a (QR1, 760 cm) (Clásico) (4-TP-T2):* This large secondary deposit contains the skeletal remains of at least five adults, as suggested by the presence of five left femora and five left scapulae. Other bones are present in the following numbers: four left and three right humeri, four left radii, four left and four right ulnae, two right femora, three left and four right tibiae, at least six fibulae, two left and one right clavicle, two right scapulae, two left and two right temporals, three mandibles, three left and two right innominates, one left and one right patella, three first cervical vertebrae, three other cervical vertebrae, 13 thoracic vertebrae, 15 lumbar vertebrae, one sacrum, one right second metacarpal, one proximal hand phalanx, three right calcanea, and several rib fragments. Note the almost complete lack of small bones of the feet and hands, and the irregular representation of the larger bones of the skeleton.

All of the five individuals represented here appear to be female. The five left femora are all gracile. The innominates show wide sciatic notches, deep preauricular sulci, and elevated auricular areas. Female sex also is supported by femoral head diameters of 39, 40, and three of 42, and by humeral head



FIGURE 6.—Superior view of cranium from Tola Pajarito 4a.

diameters of 38, 38, 38, 39, and 39.

Data from long bone cortical thickness, pubic symphysis morphology, cranial suture closure, and dental attrition suggest that one of the females was elderly, probably between 45 and 50 years, one was between 38 and 45 years, two were between 25 and 35 years, and one was between 20 and 25 years.

Only one long bone was complete enough to allow an estimation of living stature. The maximum length of a left radius of 234 mm suggests a living stature of about 164 cm (5 ft, 4 in).

Several of the bones show evidence of disease. One right tibia fragment (Figure 5) shows a well-remodeled periosteal lesion at the lateral surface of the midshaft. Another right tibia

shows an area of remodeled periosteal apposition on the medial surface of the shaft about 45 mm from the distal end. In addition, two fibula shaft fragments show areas of well-remodeled periosteal apposition.

One of the crania present (Figure 6) was sufficiently intact to enable some measurements and observations. Those (mm) from one undeformed skull are as follows: auricular height, 121; porion-bregma, 120; cranial length, 184; cranial breadth, 146; orbital height, 33; orbital breadth, 37; bigonial breadth, 103; height of ascending ramus, 54; minimum breadth of ascending ramus, 25; height of mandibular symphysis, 31; corpal length, 86; absence of mylohyoid bridge, accessory mental foramen, frontal grooves, wormian bones, parietal

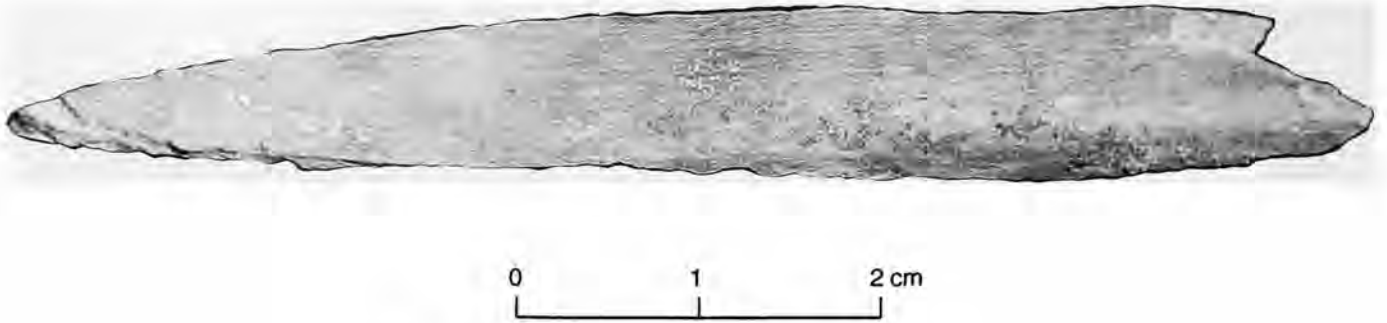


FIGURE 7.—Pointed bone fragment from Tola Pajarito V-6, Prof. 243.

process of temporal squama, squamoparietal synostosis, auditory exostoses, marginal foramen of tympanic plate and tympanic dehiscence, and presence of supra-orbital foramen.

Measurements (mm) and observations of a mandible and additional skull are as follows: bicondylar breadth, 118; bigonial breadth, 80; height of ascending ramus, 54; minimum breadth of ascending ramus, 29; height of mandibular symphysis, 33; and corpal length, 80. Absent were mylohyoid bridge, auditory exostoses, marginal foramen of tympanic plate and tympanic dehiscence. Accessory mental foramen and supra-orbital foramina are present on the left but not on the right.

One mandible shows antemortem loss of 12 teeth with only the left second molar remaining and alveolar abscesses at the sites of the three right molars and the left second molar.

Another mandible shows five teeth present. The left second premolar has a carious lesion 5 mm in length on the mesial root. All teeth show slight calculus deposits.

*Estrato Homogéneo, Prof. 2M. Ur (Clásico) (6-TP-T2)*: The following fragmentary bones of a 30- to 40-year-old of undetermined sex are present: right radius, right tibia, proximal hand phalanx, and ribs. Old remodeled slight periosteal deposits are located on the medial inferior surface of the tibia.

*Estrato Homogéneo, Neo. V6, Prof. 242-254 (Clásico) (7-TP-T2)*: Bones present of a young adult 20-35 years of age are only a right tibia and left fourth metatarsal.

*R2 (Clásico) (8-TP-T2)*: Only an adult left calcaneus is present.

*V-6, Prof. 243 (Clásico) (?-TP-T2)*: An isolated hand was found during excavation. Bones present are the following from the left hand: navicular, triquetral, five metacarpals, three proximal phalanges, four middle phalanges, and three distal phalanges. A polished pointed fragment of bone (Figure 7) also is present measuring 10 mm by about 78 mm.

The left navicular shows a planar sheared surface. No incisions are present, but the sheared surface extends through the articular surface for the lunate. Field photographs reveal that the navicular was broken into two sections when found, but both sections were in place. A wedge-shaped cut is present at

the posterior surface. It appears to have been inflicted with a sharp-pointed bone awl, which was then twisted to fracture the navicular. A triquetral also is present but was not affected.

*E.S.E., 7, 28 × 85, p.1 al 5 (Clásico) (9-TP-T2)*: The following fragmentary adult bones are present: right humerus, a fibula, right innominate, left and right talus, right first metatarsal, left third metatarsal, left fourth metatarsal, and right fifth metatarsal. The bones likely represent a 45- to 50-year-old female. Bones (right humerus, right temporal, right mandible) of two children, three and seven years old, also are present.

*V-3, Prof. 307.5 (Clásico) (10-TP-T2)*: Only the head of a femur of a 20- to 40-year-old adult male is present.

*C.E. 3.70 m (Clásico) (11-TP-T2)*: Fragmentary adult bones present are a left humerus, left radius, and left femur. The left femur shows a very thick cortex (7 to 11.5 mm thick). A femoral head diameter of 41 mm indicates female sex.

*E.S.E. 9-393 cm (Clásico) (12-TP-T2)*: The following bones of a 35- to 40-year-old female are present: both humeri, both femora, left temporal, and both innominates. A tibia shaft fragment of a 10- to 11-year-old child also is present.

*E.S.E. G-532 cm (Clásico) (13-TP-T2)*: Only a fragmentary right radius and right innominate are present. Both are likely from an adult female.

*S/P (Clásico)*: Only one adult left talus is present.

*Corte W. VIII (Clásico) (14-TP-T2)*: Two teeth, a left innominate and a right third metacarpal, are present. The innominate is female, but the metacarpal probably originated from an adult male.

*E.S.E. (Clásico)*: Only an adult left mandible and first cervical vertebra are present.

#### AREA EL MANGO MONTAÑO (200 BC to 400 AD)

*Feature 1 (CD3-4, 60 cm) (Tardío) (3-MM-T3)*: This feature was labeled "decapitado" because the postcranial skeleton was largely articulated, but the skull was separate. The following bones are present: the right humerus, both radii, ulnae, femora, fibulae, clavicles, the left scapula, the sternum, both innominates, both patellae, the first, second and four other cervical vertebrae, 12 thoracic vertebrae, five lumbar vertebrae,

the sacrum, both hand naviculars, lunates, triquetrals, capitates, hamates, the left greater and lesser multangulars, all metacarpals, 11 proximal hand phalanges, six middle hand phalanges, eight distal hand phalanges, both calcanea, the left talus, both cuboids, the right foot navicular, both first and second cuneiforms and the left third cuneiform, both first, second, third, and fifth metatarsals, two proximal first foot phalanges, two other proximal foot phalanges, and one distal first foot phalanx.

Morphology of the pubic bones and other aspects of the skeleton suggest male sex.

The extent of cranial suture closure, dental attrition, morphology of the symphyseal face of the pubis and other factors suggest an age at death of between 33 and 38 years.

The maximum length of the right tibia of 367 mm suggests a living stature of about 166 cm (5 ft, 5 in), using the formulae of Genovés (1967:76). No evidence of disease was detected on the skeleton.

All teeth are present except the maxillary right third molar, missing postmortem. Only the mandibular right third molar shows a carious lesion, 2 mm in diameter on the occlusal surface. Calculus deposits vary from small to medium.

The skull shows some frontal flattening. Measurements (mm) are as follows: auricular height, 124; porion-bregma, 120; cranial length, 171; cranial breadth, 142; basion-bregma, 140; basion-porion, 18; minimum frontal breadth, 104; upper facial height, 76; facial width, 141; nasal height, 54; nasal breadth, 27; orbital height, 37; orbital breadth, 42; maxillary alveolar length, 55; maxillary alveolar breadth, 64; palatal length, 32; palatal breadth, 38; bicondylar breadth, 124; bigonial breadth, 98; height of ascending ramus, 54; minimum breadth of ascending ramus, 34; height of mandibular symphysis, 33; total facial height, 124; and corpal length, 87. The following traits were absent: mylohyoid bridge, accessory mental foramen, frontal grooves, supraorbital foramen, squamoparietal synostosis, auditory exostoses, pharyngeal fossa, marginal foramen of tympanic plate, and tympanic dehiscence. Wormian bones were present.

*Feature 2 (C2-3-4, 70/80 cm) (Tardío) (4-MM-T3):* This feature is from cuadro CD2.3.4., Nivel 2a. The feature also was labeled "decapitado" because the skull was found separated from the postcranial skeleton. Bones present include the left humerus, both radii, the left ulna, both femora, both tibiae, both fibulae, both clavicles, both scapulae, the right temporal, the mandible, both patellae, all seven cervical vertebrae, 11 thoracic vertebrae, the five lumbar vertebrae, the sacrum, the left hand navicular, both triquetrals, the left greater and lesser multangulars, both capitates, the left hamate, the left second, third, fourth, and fifth metacarpal, three proximal, three middle, and four distal hand phalanges, both calcanea, both tali, both cuboids, both foot naviculars, the first and second cuneiforms, the right third cuneiform, the left metatarsals, the right first, second, and fourth metatarsals, two proximal first foot phalanges, four other proximal foot phalanges, three middle

foot phalanges, and one distal first foot phalanx.

Male sex is suggested by a narrow pubis, a flat auricular area, and general morphology of the skeleton.

Morphology of the symphyseal face of the pubis suggests an age at death of between 30 and 35 years. This age estimate is supported by the extent of cranial suture closure, dental attrition, and other age indicators on the skeleton.

The maximum length of the left tibia of 364 mm suggests a living stature of 165 cm (5 ft, 5 in), using the formulae of Genovés (1967:76).

The fifth lumbar vertebra displays a separate neural arch. No other abnormalities or evidence of disease was noted.

No evidence of cut marks suggestive of intentional defleshing or decapitation was found on this skeleton or that of Feature 1. In spite of this, the fact that the skulls and mandibles were articulated with each other but not with the rest of the skeleton argues for decapitation. If natural decomposition had advanced to the extent that the skull separated naturally, then other joints would have separated as well. It is possible that the heads were severed without the instrument used striking bone or that due to the poor preservation, the marks were not detected.

Twenty-six teeth were present with only one mandibular right third molar absent antemortem. Only the maxillary right third molar has a carious lesion. This measures 2 mm in length and is located in the mesial root. No evidence of hypoplasia or alveolar abscess was noted, but considerable alveolar resorption is present apparently resulting from periodontal disease. Calculus deposits vary from small to large.

The following measurements (mm) and observations were collected from the undeformed skull and mandible: auricular height, 103; porion-bregma, 98; cranial breadth, 137; bicondylar breadth, 123; bigonial breadth, 97; height of ascending ramus, 55; minimum breadth of ascending ramus, 28; and height of mandibular symphysis, 30. The following features were absent: accessory mental foramen, frontal grooves, wormian bones, auditory exostoses, marginal foramen of tympanic plate, and tympanic dehiscence. Mylohyoid bridge was bilaterally present and supraorbital foramen was present on the left, but absent on the right.

*Feature 3 (F5-6, 70 cm) (Tardío) (16-MM-T3):* Most major bones of this adult are present. Absent are the sternum, left carpal bones, both calcanea, and the right talus. A second individual is represented by an additional first cervical vertebra, right fourth metatarsal, and left fifth metatarsal.

A maximum diameter of the left femoral head of 43 mm, a maximum diameter of the head of the left humerus of 42 mm, a wide sciatic notch, irregular auricular area, and a large preauricular sulcus all suggest female sex.

A maximum length of the right radius of 243 mm suggests a living stature of 167 cm (5 ft, 6 in), using the formula of Trotter (Ubelaker, 1989:61).

The vertebral bodies show little arthritic change. The basilar synchondrosis is well united, and the bone internal cortex shows little porosity. The extent of dental attrition is extensive



FIGURE 8 (left).—Well-remodeled Colles fracture on distal left radius compared to normal distal right radius, Mango Montaña, Feature 3.

with considerable dentin exposure. Collectively, these observations suggest an age at death of between 32 and 38 years.

The distal end of the left radius diaphysis shows a well-remodeled Colles fracture (Figure 8). Typically, this type of fracture is produced by forward falls, where the individual lands on his/her hands.

The 32 teeth present lack dental caries and show calculus deposits ranging from slight to moderate. Extensive attrition has produced alveolar abscesses through exposure of the pulp cavity in the maxillary right second premolar and second molar, and the six mandibular molars (Figure 9).

Unfortunately, the skull had been coated with preservative in situ and could not be reconstructed for detailed measurements.

The following measurements (mm) were recorded: nasal breadth, 27; maxillary alveolar length, 56; maxillary alveolar breadth, 63; bicondylar breadth, 131; bigonial breadth, 107;

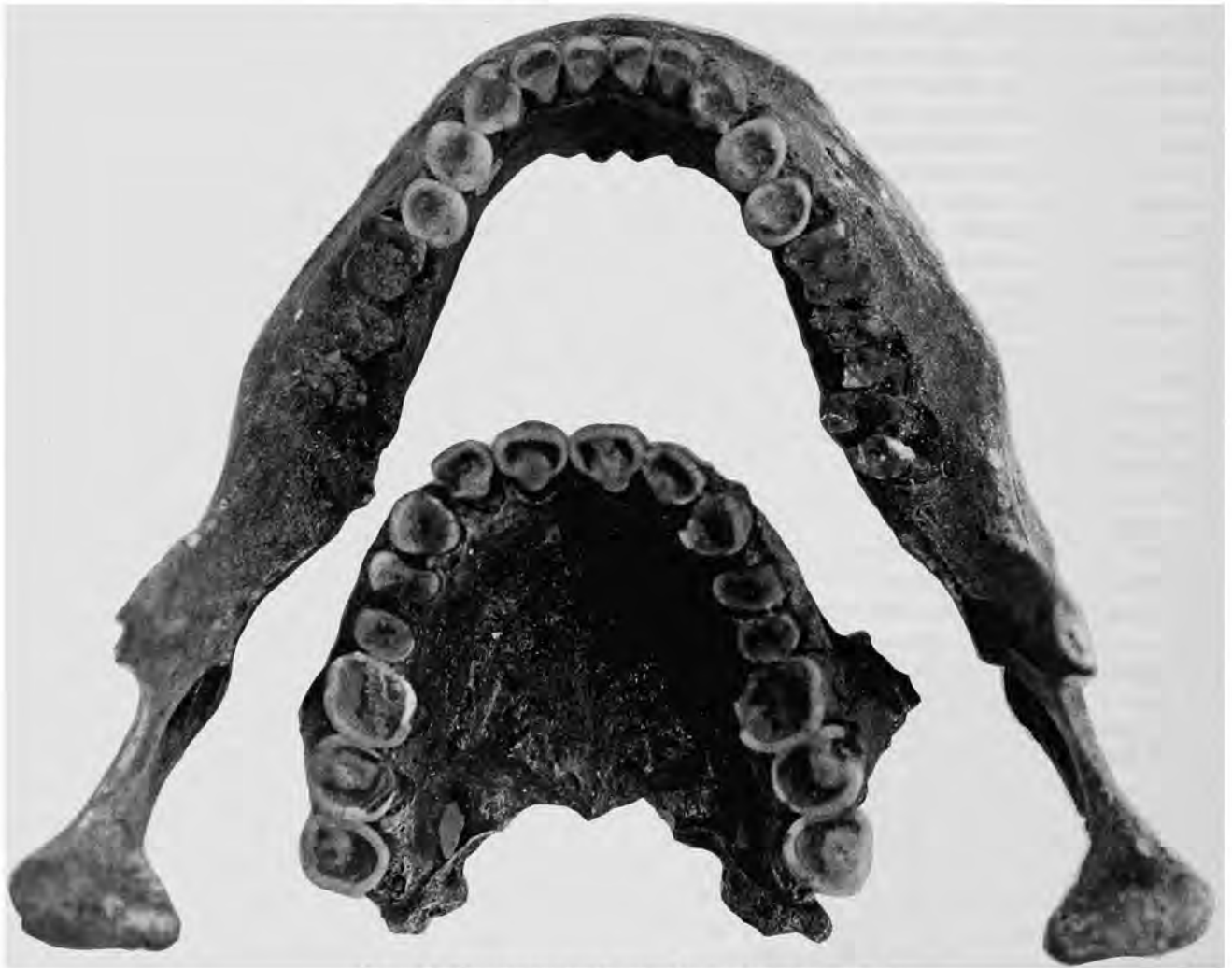

FIGURE 9.—Extensive occlusal attrition, Mango Montaña, Feature 3.



height of ascending ramus, 55; minimum breadth of ascending ramus, 32; height of mandibular symphysis, 34; and corpal length, 88. The following features were all absent bilaterally: mylohyoid bridge, accessory mental foramen, parietal process of temporal squama, squamoparietal synostosis, auditory exostoses, and tympanic dehiscence. Marginal foramen of tympanic plate was absent on the left but present on the right.

*Feature 4 (D2-3, 78 cm) (Tardío) (15-MM-T3):* The disturbed primary burial consists of the following bones: one left and one right humerus, one femur fragment, one left and one right clavicle, one left and one right scapula, two skulls, one mandible, one right innominate, one right patella, one left and one right hand navicular, one left and one right lunate, one right capitate, one right third metacarpal, and various rib fragments.

Various morphological criteria suggest both individuals represented here are females. One skull and most other bones appear to belong to an individual aged between 40 and 50 years. The skull of this individual shows extensive cranial suture closure and obliteration, extreme osteoporosis on all bones, and extreme dental wear. The vertebral bodies are extremely compressed and porous. The head of the femur shows arthritic changes with extensive remodeling. Well-remodeled periosteal apposition occurs on the posterior surface of the distal femur shaft.

The second skull is much younger. Very slight dentin exposure on the first two molars suggests an age at death of between 25 and 30 years. No evidence of disease is present.

The older skull and mandible contain 19 teeth, which lack dental caries but show extensive wear and only slight calculus deposits. Lesions and deposits may once have been present and not detected now because nearly all of the crowns have been destroyed by attrition. Alveolar abscesses are located at the sites of the maxillary right lateral incisor and canine, the maxillary left lateral incisor, and the mandibular left first molar.

The following measurements (mm) and observations were recorded from the older skull: minimum frontal breadth, 97; nasal breadth, 27; minimum breadth of ascending ramus, 26; accessory mental foramen, absent; supraorbital foramen, present bilaterally; squamoparietal synostosis, absent; auditory exostoses, absent; and tympanic dehiscence, absent.

The younger skull contains 12 teeth that lack carious lesions and have calculus deposits ranging from small to moderate. No alveolar abscesses were present.

The following measurements (mm) were recorded on the undeformed skull: auricular height, 103; porion-bregma, 99; cranial length, 169; cranial breadth, 140; minimum frontal breadth, 90; upper facial height, 69; nasal height, 51; nasal breadth, 26; orbital height, 39; orbital breadth, 44; maxillary alveolar length, 51; and maxillary alveolar breadth, 63. The following features were all absent: supraorbital foramen, infraorbital suture, squamoparietal synostosis, auditory exostoses, marginal foramen of tympanic plate, and tympanic dehiscence.

*E-4, Prof. 183 (flexed child) (Clásico) (1-MM-T2):* This feature is represented by the incomplete remains of an adolescent with a few adult bones as well. The immature remains are the right humerus, right radius, both femora, both tibiae, both fibulae, both ilia, both ischia, right pubis, right patella, both tali, eight rib fragments, 14 carpal and tarsal bones, and nine vertebrae. No cranium, mandible, or teeth are present. Lack of union of the bones of the pelvis, and the lengths of the long bones indicate an age at death of about 9.5 years.

Several bones show skeletal evidence of infectious disease. Both tibiae show periosteal new bone deposition over much of the shafts. This deposition is especially prominent on a 50 mm area of the medial surface of the lower midshaft of the left tibia. A less extreme deposition measuring 70 mm in length is located on the central lateral surface. The right tibia also shows slight periosteal deposition 55 mm long on the medial surface of the lower midshaft. Slight periosteal deposition also is located in a 55-mm long area located on the lower midshaft of the fibula.

Adult bones present consist of a right tibia fragment, a left first cuneiform of the foot, the proximal 75 mm of a right radius, and a right second metatarsal. The size of the tibia fragment suggests it may originate from an adult male.

*Feature 5 (CD2,D3) (Tardío) (13-MM-T3):* This feature consists of an incomplete skeleton with an extra right humerus. Bones present consist of two right humeri, one left and one right radius, one left ulna, one left femur, one left tibia, one left and one right temporal, one left and one right maxilla, one right innominate, four thoracic vertebrae, one lumbar vertebra, and one right third metacarpal.

Morphology of the right ilium suggests female sex.

The extent of dental attrition and cranial suture closure suggests an age at death of between 30 and 35 years.

Maximum length of a left ulna of 243 mm suggests a living stature of about 161 cm (5 ft, 3 in), using the Mexican formula of Trotter (Ubelaker, 1989:61).

Fourteen maxillary teeth are present with only one right third molar showing carious lesions. Dental calculus varies from slight to moderate.

The following observations and measurements (mm) were recorded from the skull: auricular height, 102; porion-bregma, 105; cranial breadth, 137; absence of supraorbital foramina, parietal process of temporal squama, squamoparietal synostosis, marginal foramen of tympanic plate, and tympanic dehiscence; and presence of auditory exostoses.

The inside surface of the left temporal shows a small 6 × 4 mm bony nodule extending over a groove for a blood vessel. No other abnormalities or disease processes were detected.

*Feature 6 (D2, D3, 110 cm) (Tardío) (9-MM-T3):* This feature consists of a few bones of one adult with a second adult indicated by two left scapulae, two first and two second cervical vertebrae. Other bones present include a left and right humerus, a left and right clavicle, left and right temporal, left



FIGURE 10.—Superior view of calvarium from Mango Montaña, E-7.

and right maxilla, left and right mandible, left innominate, 9 additional cervical vertebrae, two lumbar vertebrae, and several rib fragments.

Small mastoid processes on the temporals and general gracility of the skeleton suggest female sex for one individual.

Marked osteophytosis in the cervical vertebrae and extensive dental attrition suggest an age at death of between 40 and 45 years.

Maximum length of the left humerus of 297 mm suggests a living stature of about 156 cm (5 ft, 1 in).

No evidence of disease is present.

Twenty-six teeth are present showing no carious lesions and only slight dental calculus. Alveolar abscesses occur at the sites of the maxillary left second molar and mandibular right first and second molars, and the mandibular left first molar.

One partial skull is present, presenting the following

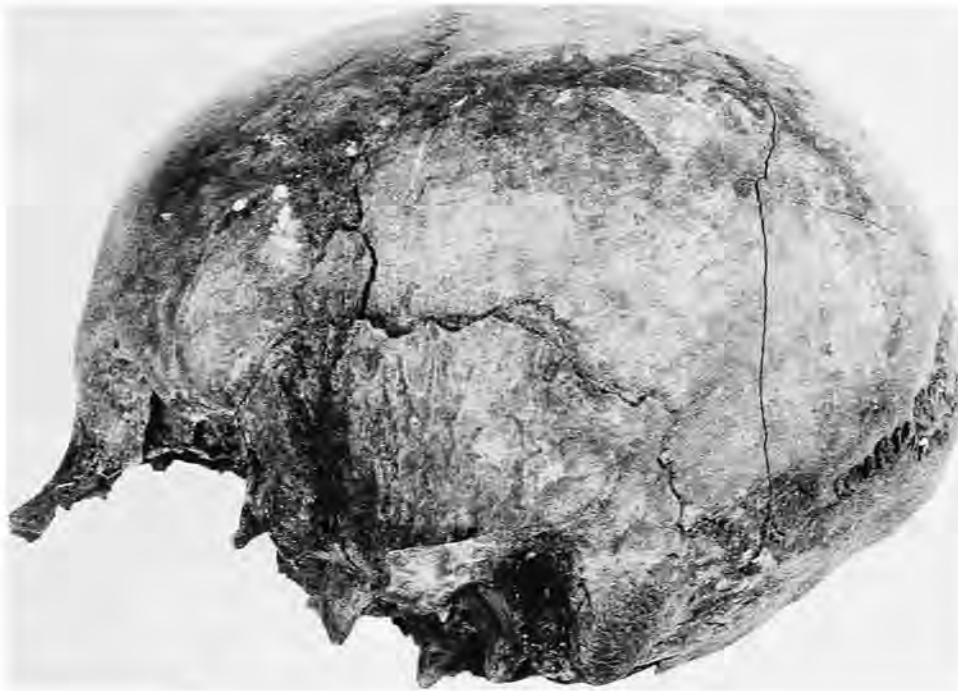

FIGURE 11.—Lateral view of calvarium from Mango Montaña, E-7.

measurements (mm): auricular height, 108; porion-bregma, 102; cranial length, 162; cranial breadth, 138; minimum frontal breadth, 92; upper facial height, 69; nasal height, 48; nasal breadth, 24; orbital height, 33; orbital breadth, 43; maxillary-alveolar length, 50; maxillary alveolar breadth, 58; bigonial breadth, 101; height of ascending ramus, 54; minimum breadth of ascending ramus, 29; height of mandibular symphysis, 29; corpal length, 79. The following features were absent: mylohyoid bridge, accessory mental foramen, supraorbital foramen, auditory exostoses, pharyngeal fossa, and tympanic dehiscence. Marginal foramen of the tympanic plate was absent on the left but present on the right.

A small circular button osteoma approximately 18 mm in diameter is present on the left parietal.

*Feature 7 (Tardio) (14-MM-T3):* Only a calvarium (Figures 10, 11, 12) and a few other bones represent this feature. Specific bones present include the right humerus, left radius, left femur, right fibula, both temporals, left maxilla, right mandible, left patella, second cervical vertebra, one lumbar vertebra, the sacrum, one proximal hand phalanx, the right second and third cuneiforms, the right first, second, fourth, and fifth metatarsals, and one first proximal foot phalanx.

Size of the skull and long bones suggests female sex.

Lack of union of the cranial sutures, lack of osteophyte formation on the vertebrae, and the extent of dental attrition suggest an age at death of between 28 and 33 years.

No evidence of disease is present.

Fourteen teeth are present and none are missing antemortem. The teeth are caries free with calculus deposits ranging from small to medium.

The following measurements (mm) were recorded: auricular height, 115; porion-bregma, 112; cranial length, 177; cranial breadth, 147; minimum frontal breadth, 94. The following traits were absent: accessory mental foramen, squamoparietal synostosis, auditory exostosis, and marginal foramen of tympanic plate. The following were present: frontal grooves, supraorbital foramen, and wormian bones. Tympanic dehiscence is absent on the left and present on the right. The skull shows a large inca bone approximately 40 mm in length.

*Feature 8 (Tardio) (8-MM-T3):* This feature consists of one adult skeleton with some infant remains also present. The adult bones are as follows: right humerus, both radii, right ulna, both femora, left tibia, right scapula, the mandible, left innominate, right patella, the first, second, and four other cervical vertebrae, eight thoracic vertebrae, five lumbar vertebrae, one right greater multangular, and various rib fragments.

Morphology of the innominate and other bones suggests female sex.

An age at death of between 45 and 50 years is suggested by extensive dental attrition and by extensive osteophytosis and porosity of the cranial vault.



FIGURE 12.—Posterior view of calvarium from Mango Montaña, E-7.

An estimated length of the right femur of 380 mm suggests a living stature of about 148 cm (4 ft, 10 in), using the formula of Genovés (1967:76) for females.

Well-remodeled periosteal apposition occurs on one ulna midshaft. In addition, both mandibular condyles are flattened with considerable pitting, indicating problems of the temporomandibular joint.

Fifteen teeth are present with only two missing antemortem. No dental caries were observed. An alveolar abscess occurs at the site of the mandibular right second molar. Calculus deposits range from small to large.

Measurements (mm) of the mandible are as follows: bicondylar breadth, 118; bigonial breadth, 94; height of ascending ramus, 51; minimum breadth of ascending ramus,

28; and height of mandibular symphysis, 35. Mylohyoid bridge was lacking on both sides and accessory mental foramen was absent on the left but present on the right.

Subadult remains from this feature consist only of cranial fragments and one right mandible. Three deciduous teeth and one permanent tooth are present. The deciduous mandibular first molar has a complete crown with the root 25% formed. The deciduous mandibular second molar and canine have a complete crown with no root formation. This stage of dental formation suggests an age at death of about 10 months.

*Feature 9 (Clásico) (3-MM-T2):* This feature consists of most major bones of an adult male with an additional right femur of an adult. Specific bones present are as follows: right humerus, left and right radius, left and right ulna, one left and

two right femora, one left and one right tibia, one left and one right fibula, one right clavicle, one right scapula, one left temporal, one left and one right maxilla, one right side of a mandible, one sternum, one left and one right innominate, all vertebrae, the sacrum, one left hand navicular, one left lunate, one left capitate, one left hamate, one left first, second, fourth, and fifth metacarpal, one right fifth metacarpal, six proximal hand phalanges, six middle hand phalanges, three distal hand phalanges, one left and one right calcaneus, one left and one right talus, the left cuboid, one left and one right foot navicular, one left first cuneiform, one right fifth metatarsal, and various rib fragments.

Male sex is suggested by a narrow pubis, large mastoid processes, and other morphological features.

An age of about 20 years is suggested by incomplete closure of the third molar root tips, extent of dental attrition, and general lack of degenerative change in the skeleton.

Measurements of both femora (left, 386 mm and right, 384 mm) and the left tibia (318 mm) suggest a living stature of 155 cm (5 ft, 1 in), using the formulae of Genovés (1976:76) for males.

Of the 27 teeth present, none show carious lesions and calculus deposits vary from absent to moderate. No teeth were observed to be missing antemortem, and no alveolar abscesses were detected.

The skull was fragmentary but undeformed. Maxillary-alveolar breadth was 62, and the minimum breadth of the ascending ramus of the mandible was 32. The following traits were absent: mylohyoid bridge, accessory mental foramen, supraorbital foramen, squamoparietal synostosis, auditory exostoses, marginal foramen of the tympanic plate, and tympanic dehiscence. Wormian bones were present bilaterally.

*D-2, Prof. 115 (Tardio) (9-MM-T3):* This burial consists of many postcranial bones of a young adult female. All the long bones are present except the right humerus. The scapulae, sternum, innominates, and patellae are present, but not the bones of the cranium and mandible. All vertebrae but three cervicals are present. All hand bones are present but one pisiform, the left triquetral, right first metacarpal, one proximal hand phalanx, and six distal hand phalanges. Other bones present are the left calcaneus, left talus, both second metatarsals, right fourth metatarsal, and 10 ribs. No teeth are present.

Various features of the pubis indicate female sex.

Lack of vertebral osteophytes and other features suggest an age at death of between 24 and 29 years.

The left calcaneus and left talus are fused together (Figure 13). The line of union is completely obliterated on the medial surface but is open on the lateral surface. No other evidence of pathology is present.

Length of the right tibia of 334 mm suggests a living stature of about 155 cm (5 ft, 1 in), using Genovés' (1967:76) formula for females.

*D-2, D-3, F-2, F-3 (accumulation of bones) (Tardio):* This feature consists only of a calvarium and first cervical vertebra.

The calvarium is well preserved but is missing the mandible, maxilla, and most of the face. No teeth are present. Both temporals of the calvarium are present.

*D-3 29. Ent. sur II (Tardio) (17-MM-T3):* This feature contains the incomplete remains of three adults. Bones present are one left and three right humeri, one left and two right radii, two right ulnae, two left and one right femora, one left and two right tibiae, one left and one right fibula, two left and one right clavicle, one left and one right scapula, one mandible, one gladiolus and manubrium, two left and one right innominate, one first and one second cervical vertebrae, three other cervicals, eight thoracics, five lumbar, one sacrum, two left hand naviculars, one left lunate, two left capitates, one left first and fourth metacarpal, one left and one right second, third and fifth metacarpal, seven proximal hand phalanges, four middle hand phalanges, one distal hand phalanx, one right foot navicular, one right third cuneiform, one left second metatarsal, and 13 ribs.

One of the three adults represents a young adult female. An age at death of between 26 and 29 years is suggested by very slight osteophytosis on the lumbar, no visible lines of union on the various epiphyses, beginning formation of a ventral rampart on the pubic symphysis. Various features of the pubis suggest female sex including moderate to deep scars of parturition on the dorsal surface.

A second adult appears to represent a young adult male, aged between 25 and 35 years. A third adult appears to represent an adult female between 25 and 35 years.

Stature can be estimated only for one adult female. One left femur, with a maximum head diameter of 39 mm, shows a maximum length of about 398 mm. This suggests a living stature of about 153 cm (5 ft, 1/2 in), using Genovés' (1967:76) formula for females.

*Ent. 1 (4.1), E5-6, Prof. 35 (Tardio) (11-MM-T3):* This secondary deposit was found to the side of Ent. 1. Adult bones present include cranial fragments, a right tibia, vertebrae fragments, three proximal hand phalanges. Teeth and cranial fragments of a six- to seven-year-old child also are present. The adult bones appear to relate to an adult between the ages of 20 and 40 years of undetermined sex.

Only four measurements (mm) of the adult cranial fragment were obtained: nasal height, 51; nasal breadth, 27; orbital breadth, 45; and height of the mandibular symphysis, 32. The following observations were recorded: accessory mental foramen, absent on the left; supraorbital foramina, notch on both sides; auditory exostoses, absent on the right, marginal foramen of tympanic plate, absent on the right, and tympanic dehiscence absent on the right.

*Ent. No. 1, EF5-6, Prof. 35 (Tardio) (11-MM-T3):* Field notes indicate a complete skeleton extended on stomach missing right lower arm and lower legs. The following bone fragments were noted: both humeri, left ulna, left femur, left tibia, both clavicles, both scapulae, both innominates, the left patella, the first and second cervical vertebrae, nine thoracic

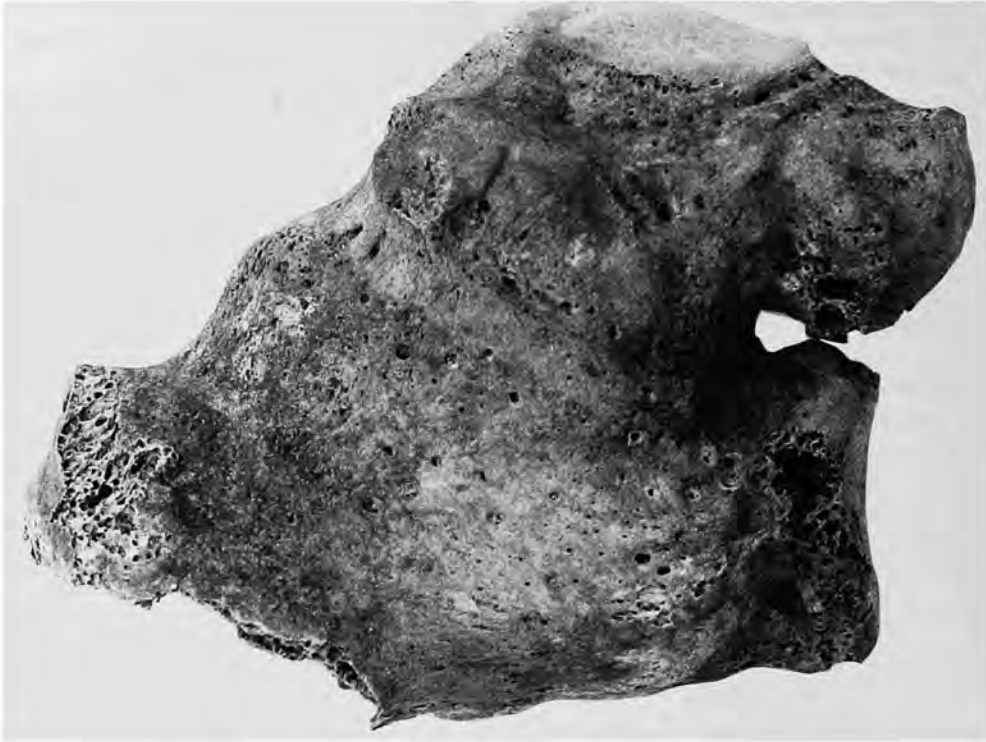


FIGURE 13.—Fused talus and calcaneus, Mango Montaña, D-2.

vertebrae, and 10 rib fragments. The bones appear to originate from a female between the ages of 35 and 45 years of age.

*Ent. 1.1, EF5-6, Prof. 35 (Tardio) (11-MM-T3):* Field notes indicate these bones represent a secondary burial found near Ent. 1. Bones present consist of fragments from a

humerus, both radii, left femur, a tibia, fibula, and clavicle. The long bones show a thin and porotic cortex and evidence of arthritic problems. The bones likely represent an adult female between the ages of 50 and 60 years. Teeth of a child approximately 10 years of age are also present.



FIGURE 14.—Cut edge of tibia from N4-3, Prof. 180.



FIGURE 15.—Exposed trabeculae of sheared surface, N4-3, Prof. 180.

*N4-3, Prof. 180 (Clásico) (5-MM-T2):* Only a proximal adult tibia fragment is present. The bone (Figure 14) shows planar shearing through the metaphysis. No individual cut marks are present, but the planar nature of the surface indicates the bone was sheared by a large blade. The exposed trabeculae (Figure 15) are cut and imbedded with soil indicating that the cut is not of recent origin.

*J2-3-4, Prof. 144 (Clásico) (6-MM-T2):* Only an immature left talus likely representing a 8- to 11-year-old child is present.

*I3 2, Prof. 20-45 cm (Tardío) (37-MM-T3):* Only fragments from an adult femoral head, right frontal, and left tibia are present. The bones likely originate from a young adult female. The tibia shaft appears to represent an artifact because it is polished and filed to a sharp point at the proximal end. The tibia fragment is about 135 mm in length.

*I2, 2 (Clásico) (7-MM-T2):* The following bones of an adult, 22 to 28 years of age are present: lumbar vertebra and left calcaneus.

*DC No. 1, Pared Este (Clásico):* Only the fragmentary proximal end of a left radius originating from an 18- to 40-year-old female is present.

*Pozo Cont. 1, Prof. 221, ampliacion (Clásico) (8-MM-*

*T2):* Only one right innominate of a 25- to 30-year-old female is present.

*Pozo Cont. 2, Prof. 170-175 (Clásico) (9-MM-T2):* Only a distal right femur, slightly charred with epiphysis united and no arthritic change, is present. The bone originates from a 20- to 40-year-old adult of undetermined sex.

*Unidad 2, Prof. 117-123, C.D/2-3-4 (Clásico) (10-MM-T2):* Only the fragmentary right humerus and the right first metatarsal of a 20- to 40-year-old adult of undetermined sex is present.

*Unidad 3, Prof. 120-124, EF/2-3-4 (Clásico) (11-MM-T2):* Only the left innominate of a male age 30 to 35 years is present.

*Unidad 1, Prof. 122-124, AB/2-3-4 (Clásico) (12-MM-T2):* Bones present are the left humerus, left radius, and right patella of an adult of undetermined sex. The patella shows extensive arthritic pitting on the medial posterior surface.

*Glt-4.5, Prof. 20-25 (Tardío):* Field notes indicate these bones originate from a secondary burial. Only fragments of the femur and tibia survive. The bones likely originate from an adult 20 to 40 years of age of undetermined sex.

*DE 6-7, Prof. 60 (Tardío) (10-MM-T3):* Field notes

indicate this feature was a primary skeleton lacking the feet that was found face down. Bones present consist of the left humerus, both radii, both ulnae, left femur, both tibiae, both fibulae, both clavicles, both scapulae, both maxillae, the mandible, both innominates, both patellae, all cervical vertebrae, eight thoracics, four lumbar, the right hand navicular, right lunate, right triquetral, right capitate, one first metacarpal, left third metacarpal, one middle and one distal hand phalanx, and fragments from the ribs. The bones likely represent an adult male between the ages of 25 and 28 years. Estimated length of the left femur of 420 mm indicates a living stature of about 161 cm, using Genovés' formula (1967:76). The right tibia shows slight well-remodeled periosteal deposition. A mylohyoid bridge is present on the right mandible. Accessory mental foramen is absent on the right side.

*C2-3, Prof. 40-44 (Tardío) (2-MM-T3):* This primary skeleton was missing bones below the lumbar vertebrae. Fragmentary bones present are the left humerus, both radii, both ulnae, the right femur, right clavicle, right scapula, both innominates, three cervical vertebrae, one lumbar, one left navicular, one right navicular, one left first metacarpal, three proximal hand phalanges, four middle hand phalanges, two distal hand phalanges, one left talus and two right tali, the left first cuneiform, right second cuneiform, and ribs. Most of the bones appear to originate from a 38- to 42-year-old female. The extra right talus is larger than the other two and likely originates from an adult male. Estimated length of the right femur of 420 mm indicates a living stature of about 159 cm (5 ft, 3 in), using the formula of Genovés (1967:76) for females. Observations recorded are accessory mental foramen, absent; wormian bones absent on both sides, squamoparietal synostosis absent on both sides, auditory exostoses absent on both sides, marginal foramen of tympanic plate absent on both sides, and tympanic dehiscence absent on both sides.

*D.2, Prof. 1.21 m (Clásico) (13-MM-T2):* Bones present are a right humerus, right radius, left tibia, and fibula. The tibia cortex is very thin and porous, indicating it originates from an older adult, likely greater than 40 years. The humerus cortex is thick with no indication of advancing age, suggesting it perhaps originates from a younger adult.

*D2 N.2a (Tardío) (22-MM-T3):* Only one proximal hand phalanx is present. The bone likely originates from an adult of undetermined sex between the ages of 17 and 35 years.

*D3, Prof. 29 (Tardío) (23-MM-T3):* Only the following foot bones of an adult of undetermined sex are present: right calcaneus, left talus, right cuboid, right navicular, right first cuneiform, both second cuneiforms, right third cuneiform, all metatarsals, two proximal first phalanges, six other proximal phalanges, two middle phalanges, two distal first phalanges, and two other distal phalanges.

*D3-E3, Prof. 145.5-148 (Clásico) (14-MM-T2):* Only the right humerus and left radius of a young adult of undetermined sex are present. The length of the left radius of 234 mm suggests a living stature of about 164 cm (5 ft, 5 in), using the

formula of Trotter for Mexican males (Ubelaker, 1989:61).

*E-4-F4-G4, VI (Prof. 60-70) (Tardío) (24-MM-T3):* Only one right humerus fragment from an adolescent or young adult is present.

*L2 (Prof. 20 cm) 20-XI-85 (Tardío) (25-MM-T3):* Only one tooth and one cranial fragment from a young adult are present.

*KL 3-4-5, Prof. 20-40 cm (Tardío) (26-MM-T3):* Bone fragments present are three left humeri, one left ulna, two right femora, one right tibia, and one left and one right innominate. The proximal epiphysis on one humerus is not united, indicating it originates from an adolescent. Parietal and frontal fragments also are present and originate from a mature adult (35 to 45 years of age). A right innominate is from a child six to nine years of age.

*KL 2-3, Nivel 2, Prof. 93 (Tardío) (27-MM-T3):* Adult bones present are a left tibia, lumbar vertebra, and a femoral head. The bones originate from a young adult male.

*MN 5-6, Prof. 110 cm (Tardío) (28-MM-T3):* Bones present are a right femur, left tibia, and one left rib. The femur is from an adolescent. The epiphysis is not present on the head and greater trochanter. The left tibia shows periosteal reactive bone on the midshaft medial inferior surface that was active at the time of death.

The fragmentary distal third of a femur of an adolescent is polished. The bone likely represents an artifact but is very small and incomplete. One adult and one adolescent are represented by all of the bones in this feature.

*MN 5-6, N.2, Prof. 83 cm Basura (Tardío) (29-MM-T3):* Bones recognized include a fragmentary right ulna, left femur, fibula, right innominate, occipital, and two animal bones. The human bones are probably those of a young adult of undetermined sex.

*Pozo de Control, Prof. 143 cm, 1.46 (Clásico) (15-MM-T2):* Bones present include the right humerus, left radius, two right radii, one left and one right ulna, a femur, two clavicles, right scapula, right innominate, three thoracic vertebrae, one left and one right first and second metacarpal, one left third metacarpal, two ribs, and most of an occipital. Most bones originate from a very small female, 45 to 50 years of age. One right proximal radius likely originates from an adult male.

*Pozo de Control, N5, Prof. 128 cm (Clásico) (4-MM-T2):* Bones present are a right humerus, left femur, right tibia, left scapula, thoracic vertebra, and three left and three right ribs. The bones likely originate from a young adult female. Estimated length of a left femur suggests a living stature of 141 cm (4 ft, 8 in).

*Pozo de Control, Prof. 98 cm (Tardío) (36-MM-T3):* Bones present are one humerus, two left tibiae, one right clavicle, one right scapula, one second cervical, two thoracics, one left navicular, one right fourth metacarpal, two middle hand phalanges, two left first cuneiforms, and four rib fragments. The bone fragments represent a mature adult, a child of about five years, and an adolescent.

*Pozo de Control, Prof. 43 cm (Tardío) (30-MM-T3):* Only



the left half of a human frontal is present. The bone appears to originate from an female between 30 and 45 years of age. A fine cut mark is located about 7 mm above nasion. The incision is about 10 mm long. A recent origin of the incision can not be ruled out morphologically.

*Pozo de Control 1. VIII-85 (Tardío) (31-MM-T3):* Bone fragments present consist of both femora, a right innominate, a right calcaneus, and ribs. The size of the femoral head indicates female sex, whereas the large calcaneus is likely male.

*Pozo No. 1, N.1, Prof. 7 cm (Tardío) (32-MM-T3):* Only a left mastoid process (temporal bone) of a small adult female or adolescent is present.

*F4 AIV (Tardío) (19-MM-T3):* These remains were found as a secondary deposit but appear to represent a single individual. Bones present consist of the right radius, both ulnae, right femur, right clavicle, left scapula, left temporal, the mandible, four thoracic vertebrae, three lumbar vertebrae, one proximal hand phalanx, both calcanea, right talus, all 10 metatarsals and an extra right third metatarsal, and four rib fragments. The bones appear to represent a 24- to 26-year-old male. Estimated length of a right femur of 420 mm suggests a living stature of about 161 cm (5 ft, 3 in), using the formula of Genovés for males (1967:76).

The height of the mandibular symphysis is 31 mm. Accessory mental foramen are absent on both sides. Auditory exostoses are absent on the left, a marginal foramen of the tympanic plate is present on the left, and a tympanic dehiscence is absent on the left.

*F2-G2, Nivel 2 (Tardío) (20-MM-T3):* Bones from this secondary deposit consist of a right humerus, both ulnae, a left and two right femora, a tibia, two right scapulae, one left temporal, two right temporals, one left and one right maxilla, one left and one right innominate, one second cervical vertebra, three other cervical vertebrae, four thoracic vertebrae, two lumbar, one left second metacarpal, two proximal hand phalanges, one left talus, two right tali, one left fourth metatarsal, and two ribs.

One femur, a right pubic bone, and a right temporal likely originate from a male of about 30 years of age. Another femur likely represents a female 17 to 25 years old. Teeth present appear to originate from individuals of the following ages: 5, 10, 14, 19-20, 23, 25-35.

*FG 2, Nivel 2A (Tardío) (21-MM-T3):* Bones present consist of a right radius, right tibia, right fourth metacarpal, and cranial fragments. The tibia (estimated length of 370 mm) appears to originate from a male, age 20 to 40 years, with an estimated living stature of about 166 cm (5 ft, 6 in), using the male tibia formula of Genovés (1967:76). The other bones likely represent a 17 to 18 year old.

*F2, Nivel 3 (Clásico) (16-MM-T2):* Bones present consist of a right humerus, right tibia, right clavicle, right maxilla, first cervical, two other cervicals, two lumbar, and seven ribs. The bones originate from a very robust male likely between the ages of 30 and 35 years. Length of the right humerus of 310 mm

indicates a living stature of 164 cm (5 ft, 5 in), using Trotter's formula for Mexican males (Ubelaker, 1989:61).

*BCDE, Prof. 7-29 (Tardío) (33-MM-T3):* Only a left humerus is present from an adolescent or young adult of undetermined sex.

*Bolsa 1 (Tardío):* Only one young adult fragmentary right tibia is present.

*N 4-5, 1 (Tardío) (34-MM-T3):* Only one adult left humerus and animal bones are present.

*E-2, 170.7 (Clásico) (2-MM-T2):* Only two adult-size rib fragments are present.

*E-2, Prof. 190 (Clásico) (2-MM-T2):* Bones present are a left humerus, right ulna, four thoracic vertebrae, one left first metacarpal, and two left and two right ribs. The humerus appears to be from an adolescent or young adult, whereas the vertebrae appear to represent a more mature adult.

*E3, Nivel 3 (Clásico) (17-MM-T2):* Bones present are fragments from a right humerus, right radius, right femur, fibula, a tibia, left clavicle, right maxilla, right innominate, left and right patellae, right hamate, left and right second metacarpals, left third metacarpal, two proximal hand phalanges, one middle hand phalanx, one left first cuneiform, one left fourth metatarsal, and ribs. One clavicle fragment appears to originate from a 9- to 10-year-old child. Most of the bones are from a 40- to 45-year-old female. The tibia diaphysis fragment shows evidence of a slight well-remodeled periosteal deposit.

*E2, Prof. 29, Temp. 85 (Tardío) (35-MM-T3):* Only the following fragmentary bones of a 30- to 40-year-old adult of undetermined sex are present: femur, thoracic vertebra, proximal hand phalanx, and ribs.

*E3, Prof. 170-177 cm (Clásico) (2-MM-T2):* Only a right temporal of a female age 17 to 30 years is present.

*E-4, Prof. 192 cm (Clásico) (1-MM-T2):* Only a left clavicle and frontal fragment of an 18- to 40-year-old female are present.

*E-4, Prof. 190 cm (Clásico) (1-MM-T2):* Only two adult cranial fragments and one right frontal are present. The bones likely represent an 18- to 40-year-old female.

*Miscellaneous Bones from Mango Montaña:* Various bones were listed as originating from Mango Montaña, but the exact provenience could not be identified. Adult bones in this category include one left and two right humeri, one right radius, two left and two right ulnae, two left and three right femora, one left and two right tibiae, one right clavicle, one left and one right temporal, one left and right maxilla, three left and two right mandibles, one left innominate, one right patella, one first and one second cervical vertebrae, two other cervical vertebrae, three thoracics, three lumbar, one sacrum, one left third metacarpal, one proximal hand phalanx, one left and three right calcanea, and one right talus. A calvarium also is present.

At least one of the adults is male with a stature of about 157 cm (5 ft, 2 in), calculated from a maximum right femur length

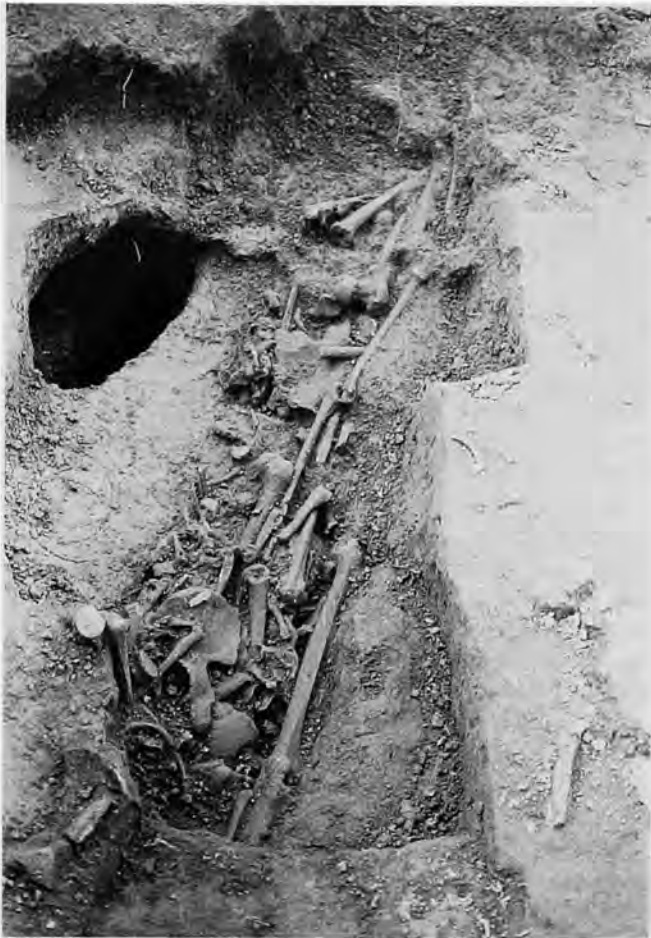

FIGURE 16 (left).—Secondary deposit of bones within the Cama, Mango Montaña.

of 400 mm, using Genovés' (1967:76) formula for Mexican males.

Immature remains from disturbed areas consist of one left humerus, one right radius, one right ulna, one left and one right femur, and two left and two right tibiae. Estimated maximum length of a right femur of 195 mm suggests an age at death of about 3.5 years. Lengths of a left and right tibia suggest an age of about 2.0 years. Another set of left and right tibiae indicate that they originate from an infant who died at or about the time of birth.

*Cama de Huesos (Tardío) (16-MM-T3)*: This feature consists of a complex secondary burial (Figures 16 and 17). At the time of excavation, many of the individual bones had been labeled individually. The following analysis first summarizes the overall representation of all bones in the feature. Each individual bone number is then identified and the bone numbers that relate to different individuals are discussed.

At least 16 individuals are represented in the feature, 11 adults and five immature individuals. The adults are represented by the following bones: eight left and seven right humeri, six left radii, seven left and five right ulnae, eleven left and eight right femora, seven left and eleven right tibiae, four left, three right, and nine other fibulae, four left and three right clavicles, four left and two right scapulae, six left and six right temporals, five left and four right maxillae, nine left and eight right mandibles, two gladioli, three manubriums, seven left and six right innominates, one left patella, two right patellae, two

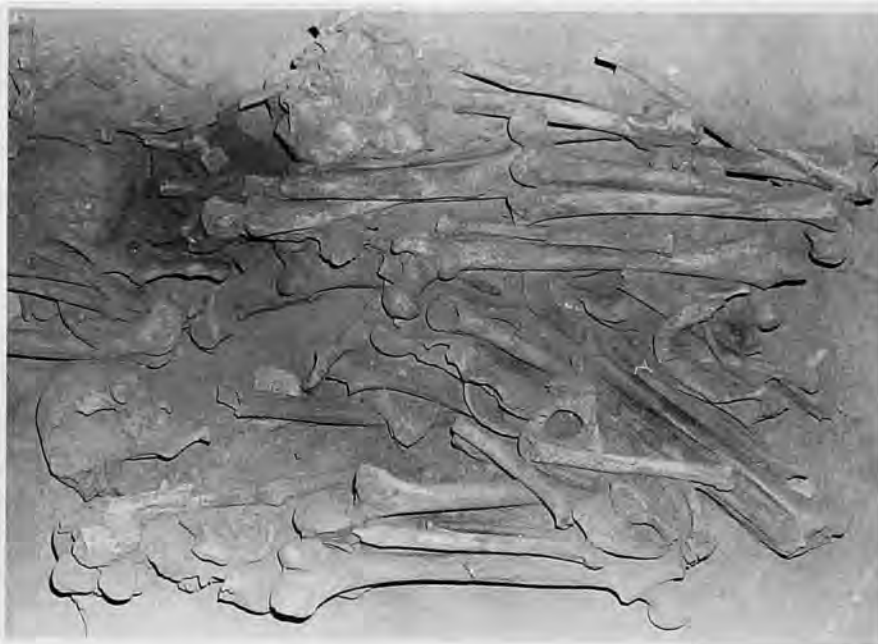

FIGURE 17.—Secondary deposit of bones within the Cama, Mango Montaña.

second cervical vertebrae, seven other vertebrae, 22 thoracic vertebrae, 13 lumbar vertebrae, three sacra, one left lunate, one left triquetral, one left greater multangular, one right hamate, one left first metacarpal, one second right metacarpal, three left and one right third metacarpal, one left fourth metacarpal, one right fifth metacarpal, seven proximal hand phalanges, five middle hand phalanges, two distal hand phalanges, five left and three right calcanea, two left and three right tali, one right cuboid, one left and one right navicular, one left first cuneiform, one right second cuneiform, one left third cuneiform, one left and four right first metatarsals, four left and two right second metatarsals, two left and two right third metatarsals, one left and one right fourth metatarsals, one left and one right fifth metatarsal, one proximal first foot phalanx, five other proximal foot phalanges, one distal first foot phalanx, and 14 left and 18 right ribs. Teeth from multiple individuals also are present.

Note that at least 11 adults are represented by left femora and right tibiae. Many of these are complete enough to allow calculation of adult stature and general estimates of age at death. Collectively they offer information about 11 of the adults present, nine males and two females. The nine males are (1) age 25 to 35 years, stature 170 cm (5 ft, 7 in) (left femur length, 458 mm); (2) young adult age 20 to 35 years, stature 170 cm (5ft, 7in) (right femur length, 462 mm); (3) age 25 to 35 years, stature 164 cm (5ft, 5 in) (left femur length, 430 mm); (4) age 25 to 40 years, stature unknown; (5) age 25 to 35 years, stature 166 cm (5ft, 5 in) (left femur length, 442 mm); (6) age 25 to 35 years, stature 154 cm (5 ft, 1 in) (left femur length, 388 mm); (7) age 25 to 35 years, stature 163 cm (5 ft, 4 in) (left femur length, 428 mm); (8) age 25 to 35 years, stature unknown; (9) age 25 to 35 years, stature 162 cm (5ft, 4in) (right femur length, 422 mm). Stature could not be estimated for the two females present. One was about 20 years old and the other was between 26 and 32 years. All male statures were estimated using the Genovès (1967:76) formula for the male femur.

The following bones of immature individuals are present: one left and one right humerus, one left and one right radius, one left and one right ulna, two left and two right femora, two right tibiae, three fibulae, one left clavicle, one left and two right scapulae, two left and one right temporal, one maxilla, three left and one right mandible, one left and two right ilia, one sternum, one left ischium, one left and one right pubis, 10 left and eight right ribs, two right carpals and tarsals, and 12 vertebrae. Sorting of the immature bones by size and development suggests the presence of at least five individuals, ages 14–17, 9, 7–7.5, 6, and 1.5 years.

Many of the bones within the "cama de huesos" were individually numbered during the excavation. The following is a detailed account of those bones that were labeled.

- 16 one adult lumbar vertebra
- 28 one right talus
- 68 one adult left rib
- 71 one adolescent right ilium

- 72 one adult male right femur
- 73 one adult right fibula
- 74 one adult male left innominate
- 75 one adult left first rib
- 76 one adult occipital and left parietal
- 77 one adult left ulna
- 78 one adult female left pubis
- 79 one fragment from an adult right ischium
- 80 one adult rib fragment and one permanent first maxillary molar
- 81 group of fragments from a distal right radius, distal left fibula, and cranial vault; complete bones are also present of two proximal hand phalanges, one middle hand phalanx, and one distal hand phalanx, all adult
- 83 adult male right innominate
- 85 one adult female lumbar vertebra
- 86 one adult mandible and one adolescent vertebra
- 87 one adult lumbar vertebra
- 88 one adult cervical vertebra and one mandibular fragment
- 89 one left scapula fragment and one cranial fragment from an adult
- 90 one adult right fibula and two adult metacarpals
- 91 epiphysis from an adolescent left femur
- 92 one second cervical vertebra and one lumbar vertebra, both adult
- 93 one complete adult male left femur
- 94 one adult right tibia
- 95 one immature calcaneus fragment of adult size, but missing posterior epiphyses, four proximal hand phalanges, one medial hand phalanx, one right fifth metacarpal, and one left fourth metacarpal, all adult
- 96 one adult cervical vertebra
- 100 adult male complete calvarium
- 101 one adult left humerus missing extreme ends
- 102 second cervical vertebra of young adult female
- 103 one complete right femur of adult male and distal half of left femur
- 104 right rib fragment and adult complete right femur
- 105 adult complete right tibia
- 106 one adult thoracic vertebra and one adult male left femur
- 107 one adult male right humerus missing extreme proximal end and one adult male left femur missing extreme distal end
- 108 one immature left humerus and one complete adult left radius
- 109 one adult right rib and one adult male right femur
- 110 one right rib fragment, two right ilium fragments, and one iliac crest fragment of an immature adolescent
- 111 one adult female complete sacrum
- 112 one adult complete right talus, one adult thoracic vertebra, one adult cervical vertebra, three rib fragments, and one fragment from a child occipital
- 113 one adult lumbar vertebra and one adult left second metatarsal
- 114 one adult male left innominate, missing only the ischium, one adult fibula midshaft, one immature left talus, adolescent sacral vertebrae, and one adult right first rib
- 115 one adult complete left temporal
- 116 one adult left humerus, one adult left first rib, and one adult complete left fibula
- 117 one adult complete right fibula and one complete mandible
- 118 one young adult right femur, missing only the proximal end, and one adult female left mandible
- 119 one adult male left ulna missing extreme distal end and one adult male right femur
- 120 young adult left distal humerus and immature calvarium of a 7- to 10-year-old child
- 121 one adult proximal phalanx of the hand and the following bones of a 9-year-old child: right greater wing of sphenoid, right maxilla, mandible missing only left ascending ramus, left maxilla, left scapula
- 122 vertebrae of a small mammal
- 123 one adult complete right fifth metatarsal, one complete right clavicle of an adolescent, and one adult rib fragment




FIGURE 18.—Artifact made from human bone, Mango Montañó Cama, 161.

- |     |  |     |   |
|-----|--|-----|---|
| 124 | adolescent right humerus, adult male left innominate   |     | distal end is 28 mm and 18 mm at the proximal end. Also present is a right tibia of an adolescent.)   |
| 125 | one proximal half of an adult fibula, and complete left third metacarpal   |     |   |
| 126 | right radius, missing proximal end; one adult fibula, also missing proximal end  | 162 | complete left femur of older child, no epiphyses are united (The bone measures 394 mm in length. Also present are an adult left scapula of undetermined sex and aged between 25 and 40 years, the distal half of a right tibia of a young adult, and a complete right humerus of a young adult female.) |
| 127 | complete left femur of adolescent  |     |   |
| 128 | fibula of adolescent missing distal end  |     |   |
| 129 | left femur of adult male missing distal end, and adult rib fragment  | 163 | adult fibula shaft fragment, 210 mm long  |
| 130 | adult female complete thoracic vertebra and one adult rib  | 164 | adult complete left femur of undetermined sex and aged between 25 and 35 years  |
| 131 | adult male complete left humerus, immature first cervical vertebra, and adult left second metatarsal missing distal end  | 165 | one lumbar vertebra of a young adult, of undetermined sex, one young adult manubrium, and one adult iliac crest fragment  |
| 132 | young adult complete right tibia   | 166 | one adult right humerus of undetermined sex, aged between 25 and 40 years   |
| 133 | adult thoracic vertebra, adult left fibula, and adult cervical vertebra  |     |   |
| 134 | immature section of first cervical vertebra (matches with same bone in 131)  | 167 | one adult complete left ulna of age 25–40 years and one left mandible, probably late adolescent, perhaps young adult  |
| 135 | one adult rib fragment and one adult right malar   | 168 | one young adult proximal hand phalanx   |
| 136 | one adult rib fragment and adult fibula fragment   | 169 | one young adult thoracic vertebra and one adult left radius   |
| 137 | adult sacrum fragment and adult right distal radius shaft fragment   | 170 | proximal 200 mm of a left tibia of a young adult; also one complete left clavicle, epiphysis on sternal end just uniting of age 22–24 years   |
| 138 | adult left clavicle and adult rib fragment   | 171 | one complete left femur of a young adult  |
| 139 | adult male complete left femur and one animal bone   | 172 | one complete left fibula of age 25–40 years.  |
| 140 | adult left humerus missing extreme ends  | 173 | one adult complete left tibia of age 25–40 years  |
| 141 | adult complete left tibia with damaged proximal end  | 174 | one thoracic vertebra of a young adult of age 18–30 years   |
| 142 | adult left humerus, missing both ends, and adult rib fragment  | 175 | one adult left third metacarpal   |
| 143 | adult rib fragment and adult radius fragment   | 176 | one adult complete right ulna and one left triquetral   |
| 144 | three adult rib fragments  | 177 | one nearly complete adult right rib   |
| 145 | adult right rib fragment   | 180 | one adult right rib   |
| 146 | adult right tibia, adult right third metatarsal, and adult left clavicle   | 181 | one adult right rib   |
| 147 | adolescent left clavicle and right rib of adolescent   | 182 | adult left acromial process of a scapula  |
| 148 | adult rib fragment, adult mandible missing right ascending ramus, and adult left mandible ascending ramus  | 183 | adult right rib fragment  |
| 149 | adult fibula shaft fragment  | 184 | one adult right rib   |
| 150 | lumbar vertebra and adult fibula shaft fragment  | 185 | one adult left fifth metatarsal   |
| 151 | adult rib fragment and left clavicle missing only extreme sternal end  | 186 | one adult middle hand phalanx   |
| 152 | several adult cranial fragments plus complete adult cervical vertebra of a small female age 25 to 35 years   | 187 | one badly eroded adult right humerus shaft fragment   |
| 153 | adult fragments of sacrum and one right rib head   | 189 | complete cranium and mandible of mature adult   |
| 154 | complete right innominate of young adult male  | 190 | one adult left rib  |
| 155 | adult first thoracic vertebra, adult left lunata, and adult first right rib  | 191 | one adult left rib  |
| 156 | eroded shaft of adult female left humerus  | 192 | one adult right rib fragment  |
| 157 | adult left humerus fragment  | 193 | one adult left rib fragment   |
| 158 | adolescent right humerus and immature cranial fragments  | 194 | one adult first metacarpal  |
| 159 | adult male right scapula and adult left radius missing both extreme ends (Rodent gnaw marks are located on most of shaft.)   | 195 | one adult rib fragment  |
| 160 | several child cranial fragments  | 196 | young adult right femur   |
| 161 | artifact of human bone, probably distal end of child femur (The artifact is 162 mm long and the extreme distal end is not present (Figure 18). The entire bone outer surface is extremely polished. The distal end has a design of two incised lines around the circumference of the bone, with a series of round 4.5 mm punched out indentations also extending around the circumference (Figure 19). The proximal end is tapered with an extended opening 53 mm long. Maximum width at the | 197 | adult rib fragment and epiphysis from a distal right femur  |
|     |  | 198 | right rib fragment and complete thoracic vertebra of young adult  |
|     |  | 199 | one adult left rib  |
|     |  | 200 | one adult rib fragment  |
|     |  | 201 | one adult rib fragment, one complete right hamate, one medial hand phalanx, and one animal bone   |
|     |  | 202 | adult thoracic vertebra (same individual as 198)  |



FIGURE 19.—Incised design on distal end of human bone artifact, Mango Montaña Cama, 161.

- 203 left ischium of a young adult
- 204 adult left first metatarsal and two adult proximal foot phalanges
- 205 one adult distal first hand phalanx
- 206 one adult complete left calcaneus
- 207 one adult left fourth metatarsal and one adult left third metatarsal
- 208 one adult rib fragment
- 209 one complete right tibia of a young adult
- 210 one adult rib end
- 211 one adult rib fragment
- 212 one adult left second metatarsal
- 213 one complete right fibula
- 214 adult left talus
- 216 one adult right rib
- 217 one adult right rib
- 218 one adult second right cuneiform
- 219 one adult right first metatarsal

- 220 one adult right fourth metatarsal
- 221 one adult right innominate of a male age 34–40 years
- 222 one adult gladiolus of age 20–35 years
- 223 adult right calcaneus of age 20–35 years
- 224 adult left foot navicular
- 225 adult right cuboid
- 226 adult left cuboid
- 227 adult right talus
- 228 adult right third metatarsal
- 229 adult right second metatarsal
- 230 adult right first foot navicular
- 231 immature fibula
- 232 left scapula
- 233 immature right femur
- 234 immature rib fragment
- 235 head of adult right femur
- 236 left ilium, immature
- 237 two rib fragments
- 238 adult complete fibula
- 239 immature rib fragment
- 240 immature left femur
- 241 immature fragmentary fibula and one animal bone
- 242 immature sacrum segment
- 243 immature right rib
- 244 immature right rib
- 245 immature right rib
- 246 immature complete left tibia
- 247 immature left rib
- 248 immature left ulna
- 249 immature rib fragment
- 250 immature right rib
- 251 immature left rib
- 252 immature right rib
- 253 adult left rib fragment and immature rib fragment
- 254 immature rib fragment
- 255 immature rib fragment
- 256 immature rib fragment
- 257 immature rib fragments
- 258 immature rib fragments
- 259 immature left rib, and manubrium
- 260 immature thoracic vertebra body
- 261 immature right rib
- 263 immature cervical vertebra
- 264 adult right rib fragment
- 265 immature left clavicle
- 267 immature right first rib
- 268 immature complete left rib
- 270 immature complete left rib
- 271 immature complete right tibia
- 272 immature left rib
- 273 immature rib fragment
- 274 immature tarsal fragment
- 276 immature rib fragment
- 277 immature rib fragment
- 278 immature rib fragment
- 279 immature thoracic vertebra
- 280 adult rib fragment, distal tibia epiphysis
- 281 transverse processes of immature thoracic vertebra
- 282 immature complete lumbar vertebra
- 283 immature complete left radius
- 284 immature right scapula
- 285 immature left humerus
- 286 immature rib fragment
- 287 immature rib fragment

288	immature lumbar vertebra	352	adult left third metacarpal
289	immature right rib fragment	353	adult left rib with head
290	immature right humerus	354	adult right rib fragment
291	immature left rib	355	adult left radius fragment
292	immature thoracic vertebra	356	adult left radius fragment
293	immature complete right radius	357	adult fibula shaft fragment
294	adult distal first foot phalanx	358	adult right rib fragment
295	proximal second foot phalanx	359	one small rib fragment
296	adult cranium, nearly complete, of male age 25-30 years; complete cranium, no mandible, with frontal deformation and slight occipital flattening of male age 25-32 years	360	complete cranium and mandible, undeformed, of male age 30-35 years
297	adult lumbar vertebra	361	adult cranium, missing part of left face, of young female age 20-30 years
298	immature left ischium	362	two left ilium fragments, area around sciatic notch
300	one frontal of young adult	364	right ilium of adult male age 25-40 years
301	one sternal rib end of young adult	365	adult second proximal foot phalanx
302	one left radius (most of proximal shaft)	366	adult second proximal foot phalanx
303	one child lumbar vertebra	367	maxillary third molar, very slight wear, of adult age 18-22 years
304	one adult left second metatarsal	369	adult rib, left sternal end
305	one adult right second metatarsal		
306	one adult rib fragment		
307	one immature right pubis		
308	one immature lumbar vertebra		
309	one adult left third metatarsal		
310	one adult cervical vertebra		
311	adult clavicle fragment		
312	adult right first proximal metatarsal		
313	immature right scapula, most of central part complete		
314	right temporal of young adult female		
315	adult right first metatarsal		
316	adult right rib fragment		
317	adult thoracic vertebra		
318	adult thoracic vertebra		
319	one adult gladiolus		
320	one adult right ulna, missing distal end		
321	one adult female right humerus		
322	immature adolescent right femur		
323	adult sphenoid fragment		
324	adult sphenoid fragment		
325	fragment from immature basilar portion of occipital		
327	fragment from an adult-size sphenoid		
328	three left rib fragments of adult		
329	fragment from mature right scapula		
330	immature cranial fragment		
331	adult rib fragment		
332	adult right rib fragment		
333	adult rib fragment		
334	adult rib fragment		
335	immature left calcaneus		
336	mature thoracic vertebra body		
337	adult rib fragment		
338	adult thoracic vertebra		
339	animal bones, right adult tibia missing proximal end with rodent gnawing over much of shaft		
340	adult rib fragment		
341	badly eroded vertebral centrum		
342	unidentified long bone shaft fragments		
343	probable shaft of right ulna, missing both ends		
344	unidentified small bone fragment		
345	right ulna, missing extreme distal end		
346	one adult middle hand phalanx		
347	adult left ulna, missing distal end		
348	unidentifiable long bone shaft fragment		
349	mature right radius, proximal end only		
350	adult thoracic vertebra		
351	very small fragment of adult vertebral centrum		

In addition to the above lots of bones that were numbered, there also were approximately 62 lots of bones that lacked numbers. These are not listed here but were inventoried and included with those numbered in the total list of bones represented in this feature.

The following bones from the "Cama" showed evidence of rodent gnaw marks over much of the diaphysis: 73, right adult fibula; 101, adult left humerus; 94, adult right tibia; 126, fibula; 127, 15- to 18-year-old left femur; 128, adolescent fibula; 159, adult left radius; 339, right adult tibia; and unnumbered adult right ulna. These modifications occur on bones of all ages and indicate that at some point in their history, likely prior to burial, they were exposed to small animals that chewed on them.

Cut marks were found on three numbered bones. One cervical vertebra (from number three through seven) from a young adult female (no. 96) displayed four cut marks. One is 10 mm long and is located on the ventral surface of the centrum (Figure 20). Two parallel incisions are 11 mm in length and located two mm apart on the inferior side of the spinous process in the midline (Figure 21). A fourth small cut mark is located on the ventral surface of the centrum, just to the right of the first one. All are very thin, and were made with a thin knife-like instrument.

The adolescent female left femur numbered 127 shows five thin cut marks on the superior, anterior, lateral diaphysis about 65 mm below the medial epicondyle (Figure 22). The incisions are each about 17 mm long and run inferior laterally.

Cut marks also are present on the adult sacrum fragment of 137, but they appear to be of recent origin.

Three examples of trauma were noted in the remains from the Cama. The right adult male femur of 119 displays an indentation on the head that measures 32 mm in length, running from superior-lateral to inferior-medial (Figure 23). The bone is slightly indented suggesting it was made while the bone was fresh (perimortem). The instrument had a pointed edge but was not sharp.

A round circular depressed fracture approximately eight mm in diameter is located on the medial superior ischial surface of



FIGURE 20.—Perimortem incision on ventral surface of cervical vertebra centrum, Mango Montaña Cama, 96.

the male right innominate of a young adult (154). The borders of the alteration are fractured, but this could represent postmortem change.

Finally an unnumbered right radius diaphysis of an adult displays a well-remodeled healed fracture.

Two bones from the Cama show evidence of infection. The left femur of no. 164 displays a circular lesion approximately 10 mm in diameter located just above the medial epicondyle on the dorsal surface (Figure 24). A perforation with irregular margins is located in the center of the lesion. The perforation is surrounded by a slightly raised area of irregular bone approximately 16 mm in diameter.

An unnumbered right adult tibia displays well-remodeled periosteal thickening on a 110 mm area of the central medial surface.

Two of three Cama crania are deformed. The adult male no. 360 lacks deformation. The adult male cranium of 189 shows slight frontal deformation. The adult male no. 296 shows slight occipital flattening.

Examples of cribra orbitalia in the Cama sample are confined to both orbits in the 7- to 10-year-old child from no. 120 (Figure 25). The expression of the condition is especially strong in the right orbit.

#### POZO IGLESIA (200 BC to 90 AD) (CLÁSICO)

*E-2 (1-T1-T2):* This skeleton of one individual is represented by the following bones: right humerus, both radii, both

ulnae, both femora, both tibiae, both fibulae, both clavicles, both scapulae, both temporals, one mandible, both innominates, the first and second cervical vertebrae, three other cervicals, eight thoracics, five lumbers, the sacrum, and eight ribs. At the time of analysis several of the vertebrae were still articulated.

A wide sciatic notch and large preauricular sulcus on the innominates, as well as the morphology of other bones, suggests female sex. The right femur shows extreme platymery in the proximal third with some lateral kyphosis that may represent a very well-remodeled fracture.

The left ulna also shows evidence of an old remodeled fracture at the distal third, approximately 50 mm from the distal end. In addition, the right radius shows an irregular surface with remodeled periosteal new bone apposition about 40 mm from the distal end. It appears to represent a well-remodeled fracture.

Estimated maximum length of a right tibia of 310 mm suggests a living stature of about 148 cm (4ft, 10 in), using the female formula of Genovés (Ubelaker, 1989:62).

The extent of cranial suture closure, loss of teeth, dental attrition, and arthritic changes suggest an age at death of between 35 and 40 years.

*Ent. #2 (secundario) (3-T1-T2):* These remains were labeled separately from the above and were studied in July of 1989. Bones present consist of a right humerus, left radius, left ulna, right scapula, both maxillae, and the mandible. The bones originate from a female, likely between 25 and 50 years of age.

*Pozo # 20. Prof. 140 cm (3-T1-T2):* Only a badly eroded

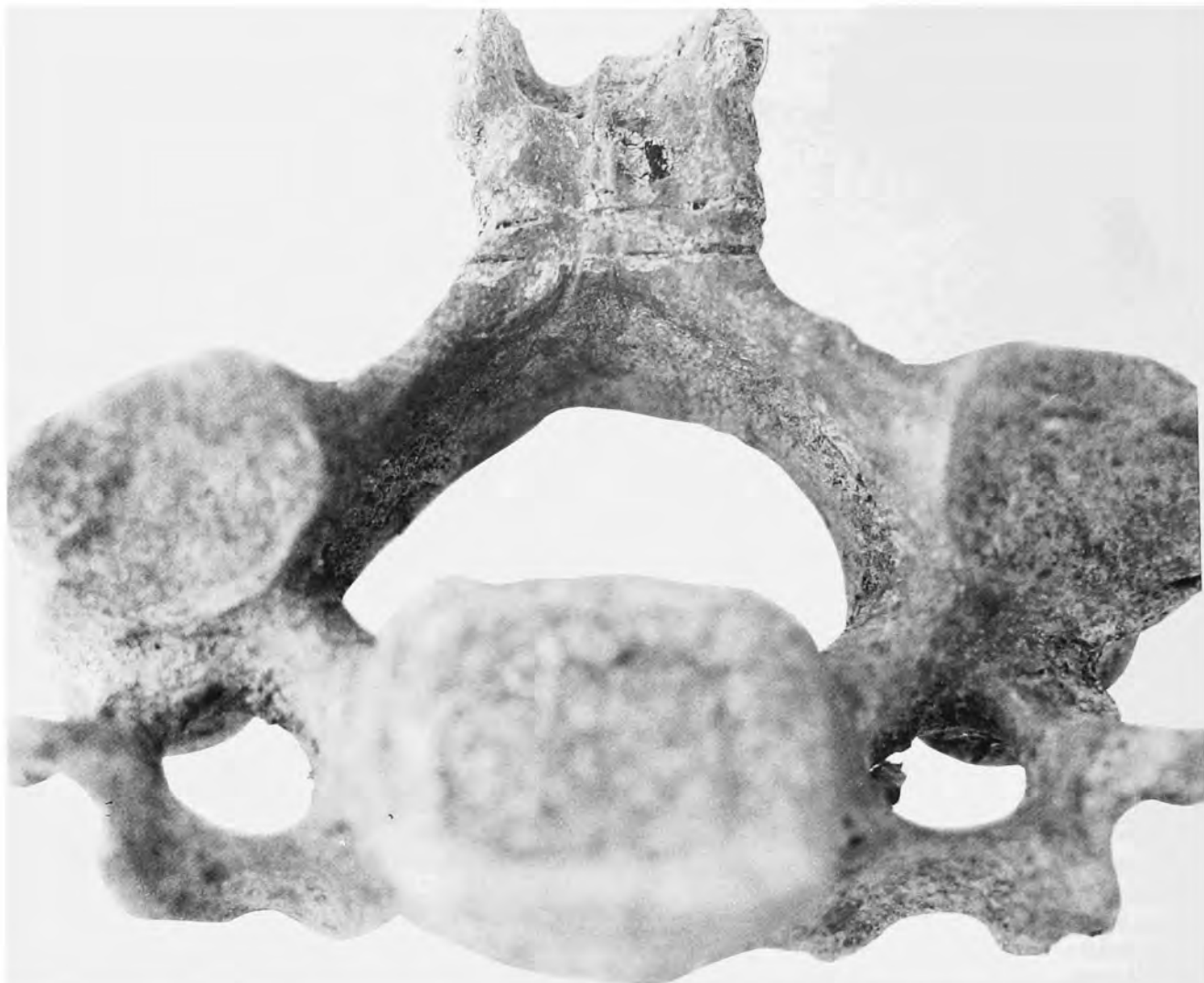


FIGURE 21.—Parallel incisions on the inferior aspect of a cervical vertebra, spinous process, Mango Montaña Cama, 96.





FIGURE 22.—Incisions on left femur, Mango Montaña Cama, 127.



FIGURE 23.—Patterned fracture on femoral head, Mango Montaña Cama, 119.

adult humerus fragment is present.

#20, 3 (4-TI-T2): A humerus and left calcaneus of a young adult female are present.

*Pared sureste, Prof. 120 (2-TI-T2)*: Fragmentary bones present are two left humeri and a proximal hand phalanx. The bones are from young adults of undetermined sex.

#### POZO LETRINA WAGNER (CLÁSICO)

*1.20 meters to 1.30 meters (1-PW-T2)*: A fragmentary complete skeleton was noted in the excavation. Bones present are the left humerus, both radii and ulnae, a tibia and fibula, left clavicle, both temporals, mandible, gladiolus, right innominate, three cervical vertebrae, two thoracic vertebrae, three lumbar, one rib, and the following bones from the right hand: lunate, triquetral, greater multangular, capitate, hamate, second, third, and fifth metacarpals, two proximal, one middle, and one distal phalanges. The bones originate from a 30-year-old male.

*Disturbed, 1.30 meters, 24 Sept. 1985*: This disturbed feature is represented only by fragments from the following adult bones: left humerus, left femur, left and right tibia, and left patella. No reliable estimate of sex or age can be made.

#### SECTOR H9 (CLÁSICO)

*E-1, Prof. 234 (2-H9-T2)*: This sector is represented by this one feature, which consists of one fragmentary adult calvarium, plus one second cervical and one right talus. The calvarium contains both temporals and the right side of a mandible and several teeth. The extent of dental attrition and cranial suture closure suggests an age at death of between 30 and 35 years. Small mastoid processes as well as general gracility of the calvarium suggest female sex.

*B2-3, Prof. 205.5 cm (1-H9-T2)*: This isolated cranium, mandible, and first two cervical vertebrae were articulated, but no other bones are present. No cut marks were found, but the bones were very fragmentary and eroded. The individual represented is a 19- to 20-year-old adult of undetermined sex.

#### AREA TOLA DE LA Balsa (TEMPRANO AND CLÁSICO)

*CE, 660 cm (Temprano) (1-TB-T1)*: Bones of this secondary deposit are the left ulna, radius, and tibia of an adult female with a living stature of about 161 cm (5 ft, 4 in).

*Superficie, revuelta (Clásico) (1-TB-T2)*: This secondary deposit consists of two right femora, a left mandible, left innominate, and lumbar vertebra. The innominate is male. Both femora (estimated lengths, 400 mm and 435 mm) also are male and represent individuals with living statures of about 157 cm (5 ft, 2 in) and 165 cm (5 ft, 5 in), estimated using the male femur formula of Genovés (1967:76).

#### AREA CABEZAS (CLÁSICO)

*Pozo B, Prof. 2.15 meters (1-SC-T2)*: Bones present are two right femora and fragments of an innominate. The bones

represent a female, 20 to 30 years old. An estimated right femur length of 380 mm suggests a living stature of about 148 cm (4 ft, 10 in), using Genovés' (1967:76) formula for the female femur.

#### UNDATED MATERIAL

According to information provided by personnel of the La Tolita project, the following bone assemblages are from the La Tolita area but can not be reliably dated or related to the features and areas discussed above.

*Solar Merlin, Pozo 3, Prof. 80 cm (1-SM-T2)*: A young child mandible, maxilla, left temporal, and first cervical vertebra are present.

*Solar Merlin, Pozo Sondeo #1, Prof. 1 m, 29-1-86 (1-SM-T2)*: Bones present are a distal femur fragment, a frontal, an osteophytic centrum fragment, and a right first metacarpal.

*BC 5.5.6, N.2a, 1-IX-85*: Only a fragmentary ulna, lumbar, and right third metacarpal are present. The bones likely originate from a young adult of undetermined sex.

*Donacion, Antonio Al Aren, XII-85*: This cranium and mandible shows occipital flattening below the external occipital protuberance on the occipital.

*Juan Cueva excavation "14," caja G (1-JC-71)*: One cranium with occipital deformation is present. The occipital deformation is extreme and extends from just posterior to the foramen magnum to the parietal foramen. Some frontal flattening is apparent as well. A metopic suture is present on the frontal. The large size of the cranium indicates male sex. Apparent postmortem erosion of the bone surface has resulted in a perforation 5 by 14 mm just above inion on the occipital. The perforation is surrounded by an eroded area measuring about 18 by 25 mm.

*Juan Cueva excavation, Fuso 4, Lt. Exc I (2-JC-71)*: Bones present are a left and right humerus, right ulna, two left and three right femora, three left and three right tibiae, one right mandible, one left innominate, and one left calcaneus. All cranial sutures are open. Femoral head diameters are about 30 mm, 41 mm, and 43 mm. One left and one right tibia show extensive well-remodeled periosteal apposition. On the left, the alteration covers all surfaces of the inferior half of the bone, with a cortical thickness of about 13 mm. On the right femur, only the proximal third is present, with the inferior 40 mm affected. The bones assembled here likely represent a mixture of the two sexes and different adult ages.

*Juan Cueva excavation, 1971, Atacames Corte A. Nivel 2, Caja E*: Bones present are a left and right humerus, left radius, one femur, tibia, one left and one right scapula, one mandible, two innominates, one thoracic vertebra, and one rib. The bones are very fragmentary and originate from an adult male and female. Two congenitally fused cervical vertebrae are present.

*Excavated by Juan Cueva Jaramilla in 1971. Caja D*



FIGURE 24.—Lesion of left femur of Mango Montaño Cama, 164.

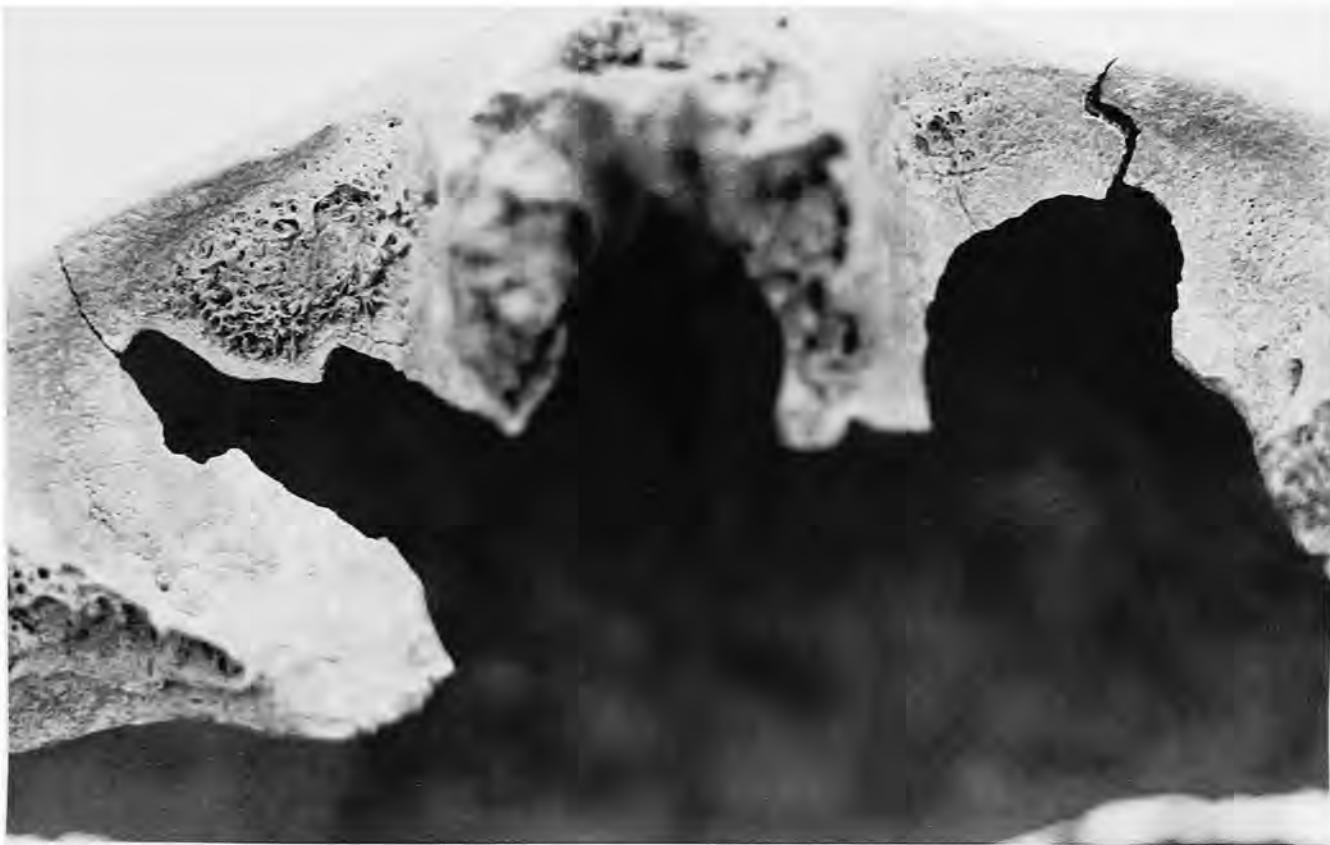

FIGURE 25.—Cribra orbitalia in orbits of child, Mango Montaña Cama, 120.

(3-JC-71): Bones present are a left humerus, left and right radius, left ulna, right femur, left and right tibia, left and right fibula, left clavicle, left and right scapulae, right temporal, left mandible, right innominate, left calcaneus, right talus, and cranial fragments. The bones likely all originate from a male between the ages of 30 and 35 years. The left radius and ulna were united by a bony bridge at the proximal end near the ulnar articular facet. The proximal articular surface of the ulna shows considerable arthritic change. The left humerus shows no abnormality, but the extreme distal end of the humerus is not present.

#### Demographic Profiles

Summary demographic information on the La Tolita samples is presented in Table 1. The minimum number of individuals within each of the samples involved judgements regarding the completeness of each individual listed. An attempt was made to relate isolated bones to other individuals within the area, rather than to assume each represented a distinct individual. The result is a conservative estimate of the number of individuals present.

The actual number may be somewhat higher. This process suggests the following minimum number of individuals: Tola Pajarito, 16; Tola Mango, 5; Mango Montaña General, 44; Mango Montaña Cama, 16; Pozo Iglesia, 2. The Tolita Temprano samples consist of all those from Tola Mango, as well as some remains from Tola de la Balsa and Tola Pajarito. The Tolita Clásico total of 32 represents those of Tola Pajarito and various features from Mango Montaña and Pozo Iglesia, Pozo Letrina Wagner, Sector H9, Tola de la Balsa, and Cabezas. The Tolita Tardío figure of 49 represents the total of the remaining samples from Mango Montaña. Remains from other areas at La Tolita are discussed in the text but are not included here because they are very incomplete and/or cannot be reliably dated.

The mean age of the samples varied little. The mean age of the Tola Mango sample was the lowest at 20 years, and the two burials of Pozo Iglesia was the highest at 38.

Similarly, the mean age of males and females in the samples varied little. Males were slightly younger than females in the Temprano, Clásico, and Tardío summary figures.

The ratio of immatures to adults in the sample decreased

TABLE 1.—Demographic information derived from the La Tolita samples.

Sample	Minimum number of individuals	Mean age of sample	Mean age of males	Mean age of females	Ratio of immature to adult individuals
Area					
Tola Pajarito	16	28	27	36	0.33
Tola Mango	5	20	28	35	0.67
Mango Montaña General	44	28	30	37	0.26
Mango Montaña Cama	16	22	30	25	0.33
Pozo Iglesia	2	38		38	0
Pozo Letrina Wagner	2	35	30		0
Sector H9	2	26		32	0
Tola de la Balsa	3	40	40	40	0
Cabezas	1	25		25	0
Period					
Tolita Temprano	7	23	23	37	0.40
Tolita Clásico	32	30	34	36	0.23
Tolita Tardío	49	27	30	35	0.20

from Temprano through Tardío. Excluding the small samples, individual ratios varied from a low of 0.26 in Mango Montaña General to a high of 0.33 in Tola Pajarito. The higher values reflect higher immature mortality, or, alternatively, a mortuary custom that produced a greater proportion of immature individuals in the sample.

Comparative data are available from 19 other archeologically recovered samples from Ecuador. These are presented in Tables 2 and 3 with the two La Tolita samples in approximate chronological order. Note that this order is only an approxima-

tion because the ranges of the dates overlap significantly. Analyses of each of these samples has either been published or is completed in manuscript form awaiting publication. The following represents a listing of the samples and their published references: Sta. Elena, Ubelaker, 1980a, 1988c; Cotocollao, Ubelaker, 1980b, 1988d; Ayalán urn and non-urn, Ubelaker 1981; OGSE-MA-172, Ubelaker, 1983, 1993; La Libertad (OGSE-46), Ubelaker, 1988b; La Tolita, Ubelaker, 1988a; Agua Blanca, Ubelaker, 1988e; Cumbayá, Ubelaker, 1990; San Francisco strata cuts, superficial collections, and boxes, Ripley

TABLE 2.—Archeologically recovered samples of human skeletal remains from Ecuador.

Sample	Date	Location (province)	Culture	Number in sample
Sta. Elena	8250 B.P.–6600 B.P.	Guayas	Vegas Complex	192
Cotocollao	1000 B.C.–500 B.C.	Pichincha	Cotocollao	199
La Libertad (OGSE-46)	900 B.C.–200 B.C.	Guayas	Engory	24
La Tolita Temprano	600 B.C.–200 B.C.	Esmeraldas	Tolita Temprano	7
Cumbayá	400 B.C.–A.D. 100	Pichincha	Cumbayá	20
OGSE-MA-172	100 B.C.	Guayas	Guangala	30
La Tolita Clásico	200 B.C.–A.D. 90	Esmeraldas	Tolita Clásico	32
La Tolita Tardío	A.D. 90–A.D. 400	Esmeraldas	Tolita Tardío	49
Ayalán non-urn	500 B.C.–A.D. 1155	Guayas	Milagro	51
La Florida	A.D. 340	Pichincha	Chaupicruz	76
Agua Blanca	A.D. 800–A.D. 1500	Manabí	Manteño	7
Ayalán urn	A.D. 730–A.D. 1730	Guayas	Milagro	384
San Francisco, vestibule	A.D. 1500–A.D. 1570	Pichincha	Historic	30
Santo Domingo	A.D. 1500–A.D. 1650	Pichincha	Historic	46
San Francisco, strata cut, upper level	A.D. 1540–A.D. 1650	Pichincha	Historic	74
San Francisco, strata cut, lower level	A.D. 1580–A.D. 1700	Pichincha	Historic	46
San Francisco, atrium	A.D. 1600–A.D. 1725	Pichincha	Historic	19
San Francisco, church	A.D. 1535–A.D. 1858	Pichincha	Historic	119
San Francisco, superficial collection, upper level	A.D. 1670–A.D. 1790	Pichincha	Historic	21
San Francisco, main cloister	A.D. 1730–A.D. 1858	Pichincha	Historic	33
San Francisco, superficial collection, lower level	A.D. 1770–A.D. 1890	Pichincha	Historic	52
San Francisco, boxes	A.D. 1850–A.D. 1940	Pichincha	Historic	33

TABLE 3.—Demographic characteristics of samples from Ecuador.

Sample	Minimum number of individuals	Mean age of sample	Mean age of males	Mean age of females	Ratio of immature to adult individuals
Sta. Elena	192	25	34	38	0.57
Cotacollao	199	28	35	34	0.21
La Libertad (OGSE-46)	24	31	32	39	0.14
La Tolita Temprano	7	23	23	37	0.40
Cumbayá	20	29	34	26	0.11
OGSE-MA-172	30	13	43	22	2.33
La Tolita Clásico	32	30	34	36	0.23
La Tolita Tardío	49	27	30	35	0.20
Ayalán non-urn	51	19	36	31	0.82
La Florida	76	20	23	24	0.19
Agua Blanca	7	12	39	33	2.50
Ayalán Urn	384	23	36	40	0.93
San Francisco, vestibule	30	17	25	27	0.76
Santo Domingo	46	25	32	40	0.35
San Francisco, strata cut, upper level	74	14	39	50	2.52
San Francisco, strata cut, lower level	46	18	40	55	1.71
San Francisco, atrium	19	10	41	18	2.80
San Francisco, church	119	18	40	55	0.95
San Francisco, superficial collection, upper level	21	21	54	45	1.63
San Francisco, main cloister	33	16	31	32	1.06
San Francisco, superficial collection, lower level	52	38	39	44	0.04
San Francisco, boxes	33	29	45	44	0.74

and Ubelaker, 1992; Ubelaker and Ripley, 1992; La Florida, Ubelaker, 1991; San Francisco vestibule, atrium, church, and main cloister, Ubelaker, in press.

As illustrated in Figure 26, these sites are located on both the coast and the sierra. The historic samples all originate from two religious institutions within Quito in the highlands. La Florida is located in the close suburbs of Quito. Cumbayá also is near Quito.

Of all the individual sample sizes, the Tolita Tardío sample (49) ranks ninth and the Clásico sample fourteenth among the 22 samples reported.

Mean age at death for precontact samples ranges from 12 in the small Agua Blanca sample to 31 in La Libertad. Within the historic samples, the values range from 10 (San Francisco atrium) to 38 (San Francisco, superficial collection, lower level). Thus the mean ages at death of 23 to 30 years for all La Tolita samples fall within the high end of the range for both the precontact and historic samples. These figures generally reflect a comparatively low rate of immature mortality.

In all La Tolita samples, the mean age at death of females (37 years Temprano, 36 years Clásico, 35 years Tardío) was greater than that of males (23 years Temprano, 34 years Clásico, 30 years Tardío). Females also outlived males in about 55 percent of the precontact samples and 60 percent of the historic samples. The male values of 23 through 34 for La Tolita fall well within the lower end of both the precontact range of 23 to 43 and the historic range of 25 to 54. The female values of 35 to 37 fall within a precontact range of 22 and 40 and a historic range of 18 and 55.

The ratios of immature individuals (less than age 15) to adults in the La Tolita samples (0.40 Temprano, 0.23 Clásico, and 0.20 Tardío) also fall within the ranges for precontact (0.11 to 2.50) and historic (0.04 to 2.80). Again, the comparatively low values reflect the relatively few numbers of immature remains.

### Antemortem Cultural Influences of the Skeleton

#### CRANIAL DEFORMATION

Only four examples of cranial deformation were found at La Tolita, one from Clásico (Tola Pajarito) and three from Tardío (Mango Montaña). The Clásico example from Tola Pajarito shows occipital flattening in a 4.5- to 5.0-year-old child. The three Tardío samples are all from adult males. A 33- to 38-year-old from Mango Montaña shows frontal deformation. A 25- to 32-year old from the Mango Montaña Cama shows flattening on both the frontal and the occipital. An adult male from the Mango Montaña Cama shows frontal flattening. This pattern generally conforms to that documented in the Ayalán samples (Ubelaker, 1981). The occipital flattening is similar to that described as Neumann's (1942) type 4 and Munizaga's (1976) cuneiform type. Such a condition may represent unintentional deformation of the skulls of immature individuals placed on their backs with their heads in contact with a hard surface (Ubelaker, 1981). The example from the Mango Montaña Cama with both frontal and occipital deformation likely represents intentional deformation in which hard flat objects were bound to the frontal and occipital areas of the head

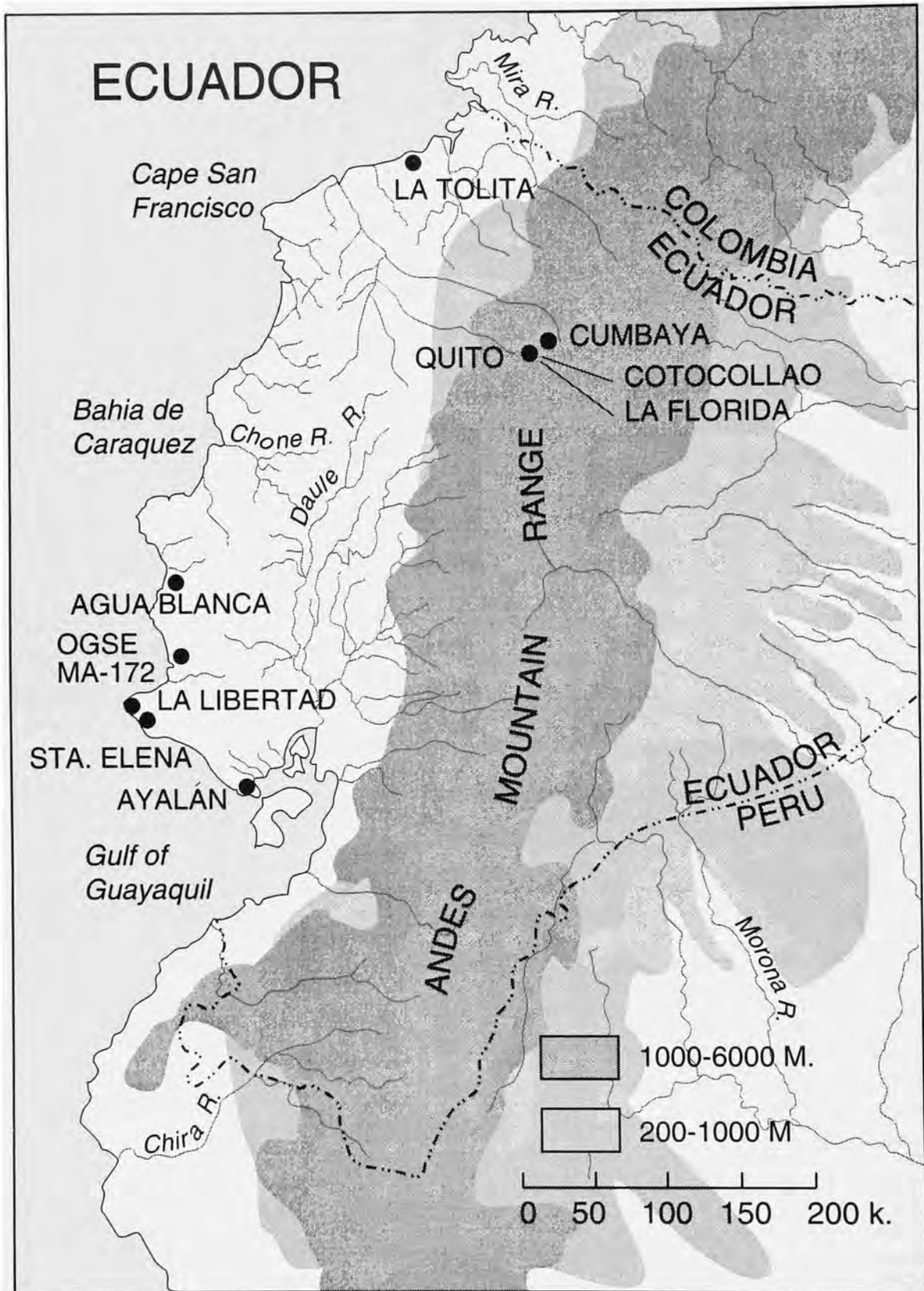


FIGURE 26.—Location of archeological sites in Ecuador yielding samples of human remains.



TABLE 4.—Measurements (in mm) of metatarsals and proximal first foot phalanges lacking alterations in La Tolita samples.

Sex	Metatarsal 1			Metatarsal 2			Metatarsal 3			Metatarsal 4			Metatarsal 5			Phalanges		
	No.	Mean	Range	No.	Mean	Range	No.	Mean	Range	No.	Mean	Range	No.	Mean	Range	No.	Mean	Range
Male	7	62	59-65	4	77	71-79	1	74	74	2	76	72-79	4	68	64-70	7	34	32-35
Female	3	55	53-57	4	72	70-75	3	70	68-73	3	67	66-68	2	65	65-65	3	32	30-37

to modify the head shape. No examples of dental mutilation or intentional modification were found.

#### METATARSOPHALANGEAL ALTERATIONS

Analysis of the Ayalán sample (Ubelaker, 1981) revealed that many of the adults, probably females, had alterations on their metatarsals and phalanges indicating extreme hyperdorsiflexion of the toes, the likely result of a kneeling posture. The alterations take the form of facets or small bony extensions on the superior surface of the distal ends of the metatarsal diaphysis and the superior proximal ends of the first foot phalanges. These alterations also occur in other American Indian and Eskimo samples (Ubelaker, 1979) and likely represent habitual work and/or rest posture.

Only one metatarsophalangeal alteration was found in the La Tolita sample. The distal end of the right third metatarsal of the adult male of Tola Pajarito 2a displayed a flattened area. All other metatarsals and phalanges lacked these alterations. Measurements of the metatarsals and phalanges that lacked the alterations are presented in Table 4. The right third metatarsal with the facet measured 78 mm in length. As demonstrated in other studies, male metatarsals and phalanges are longer than those of females. The data suggest that unlike the females at Ayalán, only one male routinely assumed a work or rest posture that involved extreme hyperdorsiflexion of the toes.

#### Postmortem Skeletal Alterations

##### RODENT TOOTH MARKS

All rodent tooth marks were found within the Mango Montaña Cama sample. Nine examples occurred on long bone diaphyses from both adult and adolescent bones. Three of the bones involved were fibulae. The others were a humerus, tibia, femur, radius, tibia, and ulna. The presence of rodent tooth marks indicates that prior to burial at least some individuals within the Cama sample were exposed either above ground or near the ground surface in a manner that allowed access by small rodents.

##### CUT MARKS

Excavation and analysis of the human remains from La Tolita revealed some evidence of dismemberment and likely soft tissue removal as part of the funerary ritual. The adult males of Features 1 and 2 of Mango Montaña were found with the articulated cranium and mandible separate from the postcranial skeleton. No cut marks were found on the bones,

but they were severely eroded.

Feature V-6, Prof. 243 of Tola Pajarito consisted of the bones of an isolated hand with incisive shearing of the carpal bones. This evidence clearly suggests that the hand was separated from the arm (not present) through incision.

Four other features revealed evidence of sharp force trauma on recovered bones. The fine incisions on the cervical vertebra (no. 96; Figures 20 and 21) from the Cama area of Mango Montaña clearly indicate perimortem sharp force trauma, the likely result of an attempt to separate the vertebra from the adjacent articulated cervical vertebra. Additional incisions (Figure 22) were found on an adolescent female left femur (no. 127) from the Cama area of Mango Montaña, and a Clásico adult tibia (5-MM-T2) from Mango Montaña (Figures 14 and 15). Also from Mango Montaña, fine incisions were found in the upper nasal area of one individual, but a recent origin could not be ruled out.

#### BONES AS TOOLS

Three human bones were found that had been modified by human activity, all from Mango Montaña. One of these (5-MM-T2, Prof. 20-45 cm) consisted of a human tibia diaphysis fragment that had been polished and filed to a point at the proximal end. An adolescent femur fragment from 28-MM-T3 shows some polishing, but the original form of the artifact cannot be established. No. 161 found in the Cama (Figures 18 and 19) consists of an artifact made from human bone, likely the distal end of a child's femur.

The modification of human bones for artifacts is unique within the samples studied from Ecuador. The presence of such artifacts further indicates the complexity of mortuary ritual at La Tolita.

#### Measurements and Developmental Characteristics

##### CRANIUM AND MANDIBLE

MEASUREMENTS.—Summary statistics on cranial and mandibular measurements are presented in Tables 5, 7, and 9. Relatively few skulls were complete enough for measurement. Comparisons between Clásico and Tardío mean values suggest that the earlier Clásico crania may have been slightly higher and longer than the later Tardío crania. Tardío mandibles may have been slightly broader.

NONMETRIC OBSERVATIONS.—Eighteen nonmetric observations were recorded on the La Tolita sample. These were selected because of their use in previous studies of Ecuadorean

TABLE 5.—Cranial and mandibular measurements (in mm), Temprano period.

Measurement	Male (n = 1)
Cranial length	177
Cranial breadth	154
Bigonial breadth	100
Height of ascending ramus	61
Minimum breadth of ascending ramus	32
Height at mandibular symphysis	32

TABLE 6.—Nonmetric observations, Temprano period.

Trait	Male	
	Number of observations	% present
Mylohyoid bridge	1	0
Accessory mental foramen	2	0
Frontal grooves	2	0
Supraorbital foramina	1	0
Supraorbital notch	1	0
Wormian bones	2	100
Parietal process of temporal squama	2	0
Squamoparietal synostosis	2	0
Auditory exostoses	2	0
Marginal foramen of tympanic plate	2	0
Tympanic dehiscence	2	0

TABLE 7.—Cranial and mandibular measurements (in mm), Clásico period.

Measurement	Male				Female			
	No.	Mean	Range	s.d.	No.	Mean	Range	s.d.
Auricular height	1	113	113	0	1	121	121	0
Porion-Bregma	1	112	112	0	1	120	120	0
Cranial length	1	183	183	0	2	177	170-184	9.9
Cranial breadth	1	145	145	0	2	144	141-146	3.5
Minimum frontal breadth	1	97	97	0	1	83	83	0
Orbital height	-	-	-	-	1	33	33	0
Orbital breadth	-	-	-	-	1	37	37	0
Maxillo-alveolar breadth	1	62	62	0	-	-	-	-
Bicondylar breadth	1	111	111	0	1	118	118	0
Bigonial breadth	1	96	96	0	2	92	80-103	16.3
Height of ascending ramus	1	64	64	0	2	54	54	0
Minimum breadth of ascending ramus	2	31	29-32	2.1	4	28	25-31	2.5
Height at mandibular symphysis	1	34	34	0	3	31	30-33	1.5

TABLE 8.—Nonmetric observations, Clásico period.

Trait	Male		Female	
	Number of observations	% present	Number of observations	% present
Mylohyoid bridge	4	25	6	0
Accessory mental foramen	3	0	7	14
Frontal grooves	2	0	7	0
Supraorbital foramina	4	0	10	50
Supraorbital notch	3	33	10	50
Infraorbital suture	-	-	1	0
Wormian bones	4	50	4	0
Parietal process of temporal squama	2	0	2	0
Squamoparietal synostosis	4	0	5	0
Auditory exostoses	4	0	8	12
Pharyngeal fossa	-	-	1	0
Marginal foramen of tympanic plate	3	0	7	0
Tympanic dehiscence	4	0	7	0

TABLE 9.—Cranial and mandibular measurements (in mm), Tardio period.

Measurement	Male				Female				Indeterminate			
	No.	Mean	Range	s.d.	No.	Mean	Range	s.d.	No.	Mean	Range	s.d.
Auricular height	6	107	103-113	3.3	5	109	103-115	4.5	-	-	-	-
Porion-Bregma	6	106	98-110	4.2	5	107	99-112	6.0	-	-	-	-
Cranial length	5	175	166-182	7.0	7	171	162-177	5.5	-	-	-	-
Cranial breadth	6	146	137-153	6.0	6	143	138-153	5.7	-	-	-	-
Basion-Bregma	2	121	119-123	2.8	1	135	135	0	-	-	-	-
Basion-Porion	1	13	13	0	-	-	-	-	-	-	-	-
Minimum frontal breadth	5	102	96-108	4.3	8	95	90-100	3.4	1	100	100	0
Upper facial height	-	-	-	-	2	69	69	0	-	-	-	-
Facial width	2	137	136-138	1.4	1	136	136	0	-	-	-	-
Nasal height	3	55	53-56	1.7	3	51	48-53	2.5	1	51	51	0
Nasal width	3	27	26-28	1.2	5	25	23-27	1.8	1	27	27	0
Orbital height	3	38	35-42	3.5	3	37	33-39	3.2	-	-	-	-
Orbital breadth	3	43	41-44	1.5	3	42	40-44	2.1	1	45	45	0
Maxillo-alveolar length	3	52	49-54	2.6	3	53	50-56	3.2	-	-	-	-
Maxillo-alveolar breadth	3	61	60-61	0.6	3	61	58-63	2.9	-	-	-	-
Bicondylar breadth	3	121	116-125	4.7	6	121	109-131	8.9	1	131	131	0
Bigonial breadth	3	98	92-106	7.1	7	98	92-107	5.0	2	103	96-110	9.9
Height of ascending ramus	3	66	55-73	9.6	9	56	51-65	5.8	4	63	59-69	4.9
Minimum breadth of ascending ramus	3	31	28-35	3.5	10	30	26-34	2.8	4	31	29-32	1.3
Height at mandibular symphysis	4	33	30-35	2.4	9	32	27-36	3.5	6	34	31-37	2.2
Total facial height	2	126	120-132	8.5	-	-	-	-	-	-	-	-

samples and the availability of comparative information. Data are summarized for males and females of the Clásico and Tardio samples in Tables 8 and 10 and for the Temprano male in Table 6. Possible differences between the periods involve mainly a higher frequency of auditory exostoses among Tardio individuals. Clásico males show higher frequency of wormian bones than those of Tardio males, but the reverse is true for females.

#### STATURE

Estimates of living stature are available for males and/or females from Tola Pajarito, Mango Montaña, Pozo Iglesia, Area Cabezas, Tola Mango, and Tola de la Balsa (Table 11). As expected, males have greater mean statures than females. Stature of the Tola Pajarito sample is slightly greater than the later Mango Montaña sample for both males and females.

TABLE 10.—Nonmetric observations, Tardio period.

Trait	Male		Female		Indeterminate	
	Number of observations	% present	Number of observations	% present	Number of observations	% present
Mylohyoid bridge	9	33	15	7	7	0
Accessory mental foramen	11	9	19	16	11	0
Frontal grooves	14	0	10	20	2	0
Supraorbital foramina	14	7	16	44	4	25
Supraorbital notch	14	71	15	53	4	75
Trochlear spur	2	0	-	-	-	-
Accessory optic canal	2	0	-	-	-	-
Infraorbital suture	6	0	4	0	2	100
Os japonicum trace	6	0	2	0	-	-
Wormian bones	14	29	11	18	-	-
Parietal process of temporal squama	10	0	6	0	-	-
Squamoparietal synostosis	12	0	20	0	1	0
Auditory exostoses	15	13	21	0	3	0
Pharyngeal fossa	5	0	3	0	-	-
Paracondylar process	2	0	2	0	-	-
Postcondylar canal	2	0	2	0	-	-
Marginal foramen of tympanic plate	15	7	17	18	3	33
Tympanic dehiscence	15	7	20	5	3	0

TABLE 11.—Estimates of living stature (in cm) in La Tolita samples.

Sample	Male			Female		
	No.	Mean	Range	No.	Mean	Range
Tola Pajarito	3	165	157-170	2	158	152-164
Mango Montaña	14	163	154-170	7	157	148-167
Pozo Iglesia	0			1	148	148
Area Cabezas	0			1	148	148
Tola Mango	1	162	162	0		
Tola de la Balsa	2	161	157-165	1	161	161

TABLE 12.—Comparison of stature estimates (in cm) derived from samples from Ecuador.

Sample	Male			Female		
	No.	Mean	Range	No.	Mean	Range
Sta. Elena	8	161	153-170	14	149	138-165
Cotocollao	17	159	149-171	7	148	138-167
La Libertad (OGSE-46)	6	162	151-170	1	153	153
La Tolita Temprano	3	163	157-170	1	161	161
Cumbayá	1	157	157	2	152	146-158
OGSE-MA-172	3	161	157-165	1	152	152
La Tolita Clásico	5	162	155-167	4	153	148-164
La Tolita Tardío	12	164	154-170	7	157	148-167
Ayalán non-urn	9	159	152-165	7	149	132-157
La Florida	3	162	159-166	9	149	128-162
Agua Blanca	1	157	157	1	151	151
Ayalán urn	25	159	151-166	31	149	136-157
San Francisco, vestibule	1	161	161	3	155	148-159
Santo Domingo	1	145	145			-
San Francisco, strata cut, upper level	3	165	155-182	9	149	140-158
San Francisco, strata cut, lower level	1	165	165	5	154	149-160
San Francisco, atrium	1	159	159	1	149	149
San Francisco, church	6	159	150-162	9	152	142-160
San Francisco, superficial collection, upper level	2	164	161-166	2	153	153-153
San Francisco, main cloister	2	161	160-161			-
San Francisco, superficial collection, lower level	10	165	156-171			-
San Francisco, boxes	6	170	164-174	10	160	153-171

TABLE 13.—Antemortem trauma from La Tolita samples.

Sample	No.	Bones	Sex	Age
Tola Pajarito	2A	cervical vertebrae	male	33-36
	3A	frontal	female	27-32
Mango Montaña	3	left radius (Colles fracture)	female	32-38
	4	rib	female	40-50
	D-2,115	talus and calcaneus	female	24-29
Mango Montaña Cama	119	right femoral head	male	adult
	154	right innominate	male	20-25
	no #	right radius	indeterminate	adult
Pozo Iglesia	E-2	right femur, left ulna, right radius	female	35-40

TABLE 14.—Trauma and periosteal lesions: Ratios of number of bones with lesions to numbers of adults and all individuals.

Sample	Number of bones with periosteal lesions to all individuals	Number of bones with periosteal lesions to adults	Number of bones with trauma to all individuals	Number of bones with trauma to adults
Sta. Elena	0.06	0.09	0.06	0.09
Cotocollao	0.04	0.04	0.02	0.02
La Libertad (OGSE-46)	0.08	0.10	0	0
La Tolita Temprano	0.14	0.20	0	0
Cumbayá	0.55	0.61	0	0
OGSE-MA-172	0.13	0.44	0.10	0.33
La Tolita Clásico	0.31	0.38	0.19	0.23
La Tolita Tardío	0.12	0.15	0.14	0.17
Ayalán non-urn	0.02	0.04	0.10	0.18
La Florida	0	0	0.07	0.08
Agua Blanca	0.14	0.50	0	0
Ayalán urn	0.08	0.16	0.07	0.13
San Francisco, vestibule	0.03	0.06	0.03	0.06
Santo Domingo	0.13	0.18	0	0
San Francisco, strata cut, upper level	0.22	0.76	0.11	0.38
San Francisco, strata cut, lower level	0.11	0.29	0.04	0.12
San Francisco, atrium	0.26	1.00	0	0
San Francisco, church	0.24	0.48	0.08	0.15
San Francisco, superficial collection, upper level	0.14	0.38	0	0
San Francisco, main cloister	0.06	0.12	0.09	0.19
San Francisco, superficial collection, lower level	0.42	0.44	0.25	0.26
San Francisco, boxes	0.09	0.16	0.33	0.58

Table 12 compares the stature values for the La Tolita Clásico and Tardío samples with those reported for other samples within Ecuador. The Clásico female mean and the Tardío means of both sexes are the highest yet reported for precontact Ecuadorean samples. In comparison to other Ecuadorean samples, the La Tolita people were relatively tall.

### Pathology

#### ANTEMORTEM TRAUMA

As shown in Table 13, antemortem trauma in the La Tolita samples consisted of 10 examples from Tola Pajarito, Mango Montaña, and Pozo Iglesia. All examples were found on adult bones of three males and five females. The fracture of the left radius of Mango Montaña feature 3 represented a Colles fracture, likely resulting from a fall. All others resulted from trauma of undetermined origin.

The ratio of bones with trauma to the total number of individuals in the sample is 0.19 for the Clásico samples and 0.14 for the Tardío samples (Table 14). Both values represent the highest yet reported for precontact Ecuadorean samples and are surpassed in the historic samples only by two of the San Francisco samples.

The similar calculation of the ratio of bones with trauma to the total number of adults is 0.23 for Clásico and 0.17 for Tardío. These values again are high but are surpassed in the

precontact samples by a 0.33 value for OGSE-MA-172 and by several of the historic San Francisco samples.

#### INFECTIOUS DISEASE

Evidence for infectious disease in the La Tolita samples consists of periosteal lesions on 17 bones from 13 individuals, six females, two males, and five individuals of undetermined sex (Table 15). All of the examples but two were extensively remodeled, indicating that the active phase of the lesion occurred a long time before death. Lesions in two of the individuals lacked such remodeling, indicating they were active at the time of death and perhaps were correlated with factors contributing to death.

The ratio of bones with periosteal lesions to the number of individuals in the sample was 0.14 for the Temprano sample, 0.31 for the Clásico sample, and 0.12 for the Tardío sample. The Clásico value is high, but both ratios fall within the range previously documented for both precontact and historic samples.

The ratios of bones with lesions to adults in the samples are 0.20 (Temprano), 0.38 (Clásico), and 0.15 (Tardío). These values also fall within the high end of the range previously documented for Ecuadorean samples.

Clearly all but two of the individuals with periosteal lesions survived the infection and likely died much later of other causes. Thus, the frequency of these lesions indicates exposure

TABLE 15.—Periosteal lesions in the La Tolita samples.

Sample	No.	Bone	Sex	Age	Status
Tola Pajarito	3A	fibula, right parietal	female	27-32	remodeled
	4A	right tibia	female	adult	remodeled
		right tibia, left fibula	female	adult	remodeled
	EH	tibia	indeterminate	adult	remodeled
Tola Mango	Prof. 276-281	tibia	male	20-35	remodeled
Mango Montaña	4	femur	female	40-50	remodeled
	E-4, Prof. 183	left and right tibiae, fibula	indeterminate	9.5	active
	8	ulna	female	45-50	remodeled
	DE 6-7	right tibia	male	25-28	remodeled
	17-MM-T2	tibia	female	40-45	remodeled
	MN 5-6, Prof. 110	left tibia	indeterminate	adult	active
	Cama 164	left femur	indeterminate	25-35	remodeled
	Cama, no #	right tibia	indeterminate	adult	remodeled

and perhaps significant morbidity from infection but not mortality. Other causes of the periosteal new bone formation, such as trauma, cannot be entirely ruled out.

#### POROTIC HYPEROSTOSIS

The term "Porotic Hyperostosis" refers to an expansion of the spongy bone in the diploe of the cranial vault (usually the parietals), as well as in the superior margins of the orbits (cribra orbitalia). The expression of porotic hyperostosis can vary from clusters of pinpoint perforations to large honeycomb-like structures. The condition appears to represent a bony response to anemia. In the Americas, the source of the anemia in precontact populations is thought to be acquired through dietary problems or morbidity. The dietary culprit usually suggested is maize, because maize is low in iron and contains phytates that can inhibit the absorption of iron (El-Najjar et al., 1976; Lallo et al., 1977). The suggested result is iron-deficiency anemia, which in turn triggers the bony response.

In the La Tolita samples, the condition is confined to one individual found within the Cama of Mango Montaña. The calvarium of a child (no. 120) between the ages of seven and 10 years displays porosity in the superior aspects of both orbits (Figure 25). The expression is stronger in the right orbit.

Table 16 compares the expression of porotic hyperostosis in La Tolita with that from other Ecuadorean samples. The value of 0.02 for La Tolita Tardío falls within the range of values previously reported for both precontact and historic samples.

As noted before (Ubelaker, 1992), the condition appears in Ecuadorean samples shortly before the time of Christ and initially appeared to be confined to coastal sites. The high frequency at OGSE-MA-172, where iron-rich seafood was consumed, and absence at Cotocollao, a highland site lacking seafood but having maize, argued against maize being the principal causal factor. The high frequency at the coastal site and initial absence in the highlands suggested that the condition might have been caused by low-altitude-dwelling hookworm

(Ubelaker, 1992). Subsequent work revealed a low frequency at the highland site of La Florida as well as in various highland historic samples. Of course the historic samples may contain individuals of European origin, allowing the possibility that the condition represents congenital and not acquired anemia. The San Francisco vestibule sample is thought to contain Indians, although from the early historic period.

#### DEGENERATIVE CHANGES

As noted earlier, the mean age at death for males was 28 among La Tolita Clásico and 30 among La Tolita Tardío. For females the value was 36 years for both samples. The age

TABLE 16.—Ratio of bones with porotic hyperostosis to the number of individuals in the sample.

Sample	Ratio
Sta. Elena	0
Cotocollao	0
La Libertad (OGSE-46)	0
Cumbayá	0
OGSE-MA-172	0.33
La Tolita Clásico	0
La Tolita Tardío	0.02
Ayalán non-urn	0.08
La Florida	0.01
Agua Blanca	0
Ayalán urn	0.07
San Francisco, vestibule	0.06
Santo Domingo	0
San Francisco, strata cut, upper level	0.12
San Francisco, strata cut, lower level	0.04
San Francisco, atrium	0
San Francisco, church	0
San Francisco, superficial collection, upper level	0.05
San Francisco, main cloister	0
San Francisco, superficial collection, lower level	0
San Francisco, boxes	0.06

TABLE 17.—Vertebral osteophytosis at La Tolita.

Sample/Sex	Cervical				Thoracic				Lumbar			
	No.	0	1	2	No.	0	1	2	No.	0	1	2
Tola Pajarito												
Male	28	16	12	0	44	33	11	0	18	7	10	1
Female	15	3	9	3	34	17	17	0	24	10	10	4
Tola Mango												
Male	4	4	0	0	6	6	0	0	5	5	0	0
Mango Montaña												
Male	11	11	0	0	26	16	10	0	12	12	0	0
Female	14	13	1	0	20	20	0	0	15	8	5	2
?	7	6	1	0	10	10	0	0	9	8	1	0
Pozo Letrina Wagner												
Male	0	0	0	0	3	3	0	0	0	0	0	0
Totals	79	53	23	3	143	105	38	0	83	50	26	7

changes among the adults within these samples are marked in many ways on the skeleton. Data were collected from several areas of the skeleton to document the distribution of degenerative changes. Tables 17 through 21 summarize the distribution of vertebral osteophytosis, spicule formation, arthritic lipping on selected joint surfaces, and porosity and related arthritic changes on the joint surfaces among the La Tolita samples.

In general, females for all Tolita samples reveal a greater expression of vertebral osteophytosis (Table 17). This frequency difference is consistent with the greater mean age at death for females. The three categories of vertebral osteophytosis indicate the degree of formation (Ubelaker, 1981:122). Some expression of vertebral osteophytosis was observed in 28 percent of male vertebrae and 42 percent of those of females. Within male vertebrae, osteophytosis was present in 28 percent of cervicals, 27 percent of thoracics, and 31 percent of lumbar. For female vertebrae, 45 percent of cervicals, 31 percent of thoracics, and 54 percent of lumbar show some degree of

osteophytosis. The data suggest that for both males and females, the lower back was stressed more than the upper.

Table 18 presents data on arthritic lipping of joint surfaces within the La Tolita samples. Data on lipping were collected from the humeral head, proximal and distal tibia, patella, and the cuboid facet of the calcaneus. Lipping was scored as present if any bony extensions were observed on the margins of the joint surface. Frequencies ranged from absent in the proximal tibia to 25 percent of patellae and 16 percent of humeral heads.

Observations on abnormal porosity are available in Tables 19 and 20 for 12 joint surfaces. Abnormal porosity was absent in the tibia, fibula, superior calcaneus, and distal radius. The greatest expression occurred in the proximal ulna (especially in those from Tola Pajarito) and the distal humerus.

Observations on spicule formation are available in Table 21 for the proximal anterior surface of the tibia, the anterior surface of the patella, and the inferior posterior surface of the calcaneus. These spicules were absent from the calcaneus but

TABLE 18.—Arthritic lipping of joint-surface margins in La Tolita samples.

Sample/Sex	Humerus head		Proximal tibia		Distal tibia		Patella		Cuboid facet of calcaneus	
	No.	Present	No.	Present	No.	Present	No.	Present	No.	Present
Tola Pajarito										
Male	4	1	7	0	6	1	7	3	6	1
Female	11	4	4	0	7	2	4	1	0	0
Tola Mango										
Male	2	0	0	0	0	0	2	0	2	0
Mango Montaña										
Male	2	0	1	0	1	0	0	0	1	0
Female	7	0	3	0	3	0	3	0	0	0
?	5	0	9	0	11	0	0	0	8	0
Pozo Iglesia										
Female	1	0	1	0	1	0	0	0	0	0
Totals	32	5	25	0	29	3	16	4	17	1

TABLE 19.—Arthritic porosity in joint surfaces of the tibia, fibula, and calcaneus in La Tolita samples.

Sample/Sex	Proximal tibia		Distal tibia		Proximal fibula		Distal fibula		Anterior calcaneus		Superior calcaneus	
	No.	Present	No.	Present	No.	Present	No.	Present	No.	Present	No.	Present
Tola Pajarito												
Male	7	0	7	0	5	0	4	0	8	1	7	0
Female	5	0	8	0	1	0	4	0	0	0	1	0
Mango Montaña												
Male	1	0	1	0	1	0	0	0	1	0	1	0
Female	3	0	3	0	2	0	2	0	0	0	0	0
?	9	0	12	0	4	0	9	0	8	0	8	0
Totals	25	0	31	0	13	0	19	0	17	1	17	0

TABLE 20.—Arthritic porosity in joint-surface margins of the humerus, radius, ulna, and femur in La Tolita samples.

Sample/Sex	Distal humerus		Proximal radius		Distal radius		Proximal ulna		Distal ulna		Distal femur	
	No.	Present	No.	Present	No.	Present	No.	Present	No.	Present	No.	Present
Tola Pajarito												
Male	5	1	7	0	6	0	8	4	6	0	7	0
Female	5	3	7	2	6	0	5	4	5	2	8	3
Tola Mango												
Male	1	0	1	0	0	0	1	0	0	0	2	0
Mango Montaña												
Male	3	0	3	1	3	0	5	1	0	0	1	0
Female	4	0	3	0	2	0	3	0	2	0	2	0
?	8	1	4	0	4	0	7	2	3	0	13	0
Pozo Iglesia												
Female	1	1	2	0	1	0	1	1	0	0	0	0
Pozo Letrina Wagner												
Male	0	0	1	0	2	0	1	0	0	0	0	0
Totals	27	6	28	3	24	0	31	12	16	2	33	3

TABLE 21.—Spicule formation in La Tolita samples.

Sample/Sex	Tibia			Patella			Calcaneus		
	No.	Present	%	No.	Present	%	No.	Present	%
Tola Pajarito									
Male	9	2	22	9	0	0	8	0	0
Female	4	0	0	2	0	0	0	0	0
Mango Montaña									
Male	1	0	0	0	0	0	2	0	0
Female	6	0	0	3	2	67	0	0	0
?	5	0	0	3	0	0	8	0	0
Totals	25	2	8	17	2	12	18	0	0

were present in 13 percent of patellae and eight percent of tibiae.

#### CONGENITAL DISORDERS

Examples of congenital disorders were rare in the La Tolita materials. The three examples were all located within the

Mango Montaña sample. They consist of a separate neural arch on a fifth lumbar of feature 2, a bony nodule on the internal surface of a left temporal, and a button osteoma on a left parietal from Feature 6. The right maxilla of Mango Montaña Cama (no. 189), displayed a third molar that was completely inverted. The occlusal tip was located 31 mm from the occlusal border of the alveolus (Figure 27).





FIGURE 27.—Inverted maxillary right third molar, Mango Montaña Cama, 189.

#### DECIDUOUS DENTITION

Observations on deciduous teeth are confined to 38 teeth from four features: 1-SM-T2; 1-TP-T2; 7-TM-T1; and the child from 11-MM-T3. Of the 38 teeth present, none were lost prematurely antemortem, none were carious, and no associated alveolar abscesses were identified. Of observations of calculus, 21 were absent and 16 were slight on the buccal surfaces. On the lingual surface, 23 were absent and 14 were slight. The maxillary canine crowns of 1-TP-T2 show buccal pitting that likely represents hypoplasia.

#### PERMANENT DENTITION

Inventory of permanent teeth present in the La Tolita samples is presented in Table 22. A total of 638 teeth were examined, 367 from non-Cama features of Mango Montaña, 136 from Mango Montaña Cama, 22 from Pozo Iglesia, 2 from H9, 49 from Tola Pajarito, 33 from Tola Mango, and 29 from other areas.

Antemortem loss was assessed from the absence of the tooth and evidence of bony remodeling within the appropriate area of the alveolus. Tooth loss averaged 4.9 percent for the entire

TABLE 22.—Inventory of permanent teeth present in La Tolita samples.

Sample/Sex	Maxilla				Mandible				Totals
	Incisors	Canines	Premolars	Molars	Incisors	Canines	Premolars	Molars	
Mango Montaña									
Male	10	6	14	24	10	4	12	23	103
Female	18	13	26	30	17	10	25	36	175
?	11	6	16	19	4	4	13	16	89
Mango Montaña Cama									
Male	0	2	4	4	8	4	8	10	40
Female	2	2	4	3	0	1	2	4	18
?	9	4	6	8	9	4	12	26	78
Pozo Iglesia									
Female	3	1	4	1	2	1	4	6	22
H9									
Female	0	0	0	0	0	0	0	2	2
Tola Pajarito									
Male	3	2	4	5	3	2	2	6	27
Female	0	2	6	3	0	1	3	5	20
?	1	0	1	0	0	0	0	0	2
Tola Mango									
Male	4	2	4	6	4	2	4	6	32
?	0	0	0	0	0	0	0	1	1
Other areas									
Male	1	0	0	0	2	1	3	5	12
?	3	1	2	5	0	1	2	3	17

TABLE 23.—Antemortem permanent tooth loss in La Tolita samples.

Sample/Sex	Maxilla								Mandible								Total	
	Incisors		Canines		Premolars		Molars		Incisors		Canines		Premolars		Molars			
	No.	%	No.	%	No.	%	No.	%	No.	%	No.	%	No.	%	No.	%		
Mango Montaña																		
Male	0/12	0	0/6	0	0/15	0	0/26	0	1/15	7	0/7	0	2/15	13	5/30	17	8/126	6.3
Female	0/28	0	0/15	0	0/33	0	1/34	3	5/34	15	0/18	0	0/36	0	6/47	13	12/245	4.9
?	0/17	0	2/9	22	0/16	0	0/19	0	1/10	10	0/6	0	0/16	0	4/23	17	7/116	6.0
Mango Montaña Cama																		
Male	0/4	0	0/2	0	0/4	0	2/6	33	0/8	0	0/4	0	0/8	0	2/12	17	4/48	8.3
Female	0/4	0	0/2	0	0/4	0	0/3	0	—	—	0/1	0	0/4	0	0/4	0	0/22	0
?	0/11	0	0/5	0	0/8	0	1/12	8	0/30	0	0/14	0	0/24	0	1/37	3	2/141	1.4
Pozo Iglesia																		
Female	0/3	0	0/1	0	0/4	0	0/1	0	0/6	0	0/3	0	2/6	33	2/10	20	4/34	11.8
H9																		
Female	—	—	—	—	—	—	—	—	—	—	—	—	0/1	0	0/3	0	0/4	0
Tola Pajarito																		
Male	0/3	0	0/2	0	0/4	0	0/5	0	0/4	0	0/2	0	0/4	0	0/6	0	0/30	0
Female	—	—	0/2	0	0/6	0	0/3	0	0/5	0	0/5	0	0/11	0	3/19	16	3/51	5.9
?	0/1	0	—	—	0/1	0	—	—	—	—	—	—	—	—	—	—	—	—
Tola Mango																		
Male	0/4	0	0/2	0	0/4	0	0/6	0	0/4	0	0/2	0	0/4	0	0/6	0	0/32	0
?	—	—	—	—	—	—	—	—	0/4	0	0/2	0	0/4	0	3/6	50	3/16	18.8
Other areas																		
Male	0/1	0	—	—	—	—	—	—	0/2	0	0/1	0	0/3	0	0/5	0	0/12	0
?	0/4	0	0/1	0	0/2	0	1/7	14	—	—	0/1	0	0/2	0	0/3	0	1/20	5

TABLE 24.—Permanent teeth with carious lesions in La Tolita samples.

Sample/Sex	Maxilla								Mandible								Total	
	Incisors		Canines		Premolars		Molars		Incisors		Canines		Premolars		Molars			
	No.	%	No.	%	No.	%	No.	%	No.	%	No.	%	No.	%	No.	%		
Mango Montaña																		
Male	0/10	0	0/6	0	0/13	0	1/23	4	0/9	0	0/4	0	0/12	0	1/23	4	2/100	2.0
Female	0/18	0	0/13	0	0/26	0	1/30	3	0/15	0	0/10	0	0/25	0	2/32	6	3/169	1.8
?	0/10	0	0/6	0	0/16	0	0/18	0	0/4	0	0/4	0	0/15	0	0/15	0	0/88	0
Mango Montaña Cama																		
Male	-	-	0/2	0	0/4	0	0/4	0	0/8	0	0/4	0	0/8	0	0/10	0	0/40	0
Female	0/2	0	0/2	0	0/4	0	0/3	0	-	-	0/1	0	0/2	0	0/4	0	0/18	0
?	0/9	0	0/4	0	0/6	0	0/8	0	0/9	0	0/4	0	0/12	0	0/26	0	0/78	0
Pozo Iglesia																		
Female	0/3	0	0/1	0	0/4	0	0/1	0	0/2	0	0/1	0	0/3	0	2/5	40	2/20	10.0
H9																		
Female							-	-							0/2	0	0/2	0
Tola Pajarito																		
Male	0/3	0	0/2	0	0/3	0	0/2	0	0/2	0	0/1	0	0/2	0	0/6	0	0/21	0
Female			0/2	0	0/6	0	0/4	0			0/1	0	1/3	33	0/4	0	1/20	5.0
?	0/1	0	-	-	0/1	0	-	-	-	-	-	-	-	-	-	-	-	-
Tola Mango																		
Male	0/4	0	0/2	0	0/4	0	0/6	0	0/4	0	0/2	0	0/4	0	0/6	0	0/32	0
?			-	-	-	-	-	-			-	-			0/1	0	0/1	0
Other areas																		
Male	0/1	0							0/2	0	0/2	0	0/4	0	0/6	0	0/15	0
?	0/3	0	0/1	0	0/2	0	0/5	0			0/1	0	0/2	0	0/3	0	0/17	0

sample (44 of 897 observations). The distribution of tooth loss among the samples and between the sexes was relatively even (Table 23). Tooth loss values for other precontact samples range from 1 to 42 and within historic samples from 4 to 89. Thus the La Tolita values are relatively low.

The frequency of dental caries is relatively low in the La Tolita samples (Table 24). Of 621 observations for dental caries, only eight (1.3 percent) carious lesions were found. No lesions were found in the Mango Montaña Cama, H9, and Tola Mango samples. Frequencies within other samples varied from 1.8 percent among Mango Montaña females to 10 percent for the Pozo Iglesia female. Overall, carious lesions were slightly more common in females (2.6 percent) than males (1.0 percent). Lesions were absent in the anterior dentition, occurring only in the maxillary molars and the mandibular premolars and molars.

Values for dental caries in the La Tolita Tardío samples of about 1.0 percent (Table 25) are the lowest yet reported for large samples within Ecuador (no carious lesions were found in the small Agua Blanca and La Tolita Temprano samples). This low frequency is difficult to explain given the date and agricultural subsistence base of the La Tolita population. Presumably, it reflects constitutional factors or perhaps acquired resistance to caries such as would be expected with high fluorine levels in drinking water.

Preliminary data available from analysis of water samples suggests that fluoride may have been a factor. Water samples

were collected from wells, springs, or other ground water sources associated with seven of the archeological sites that have yielded samples of human remains. These samples were analyzed for fluoride content by the Laboratorio de Aguas y Control de Contaminación, Instituto Ecuatoriano de Recursos Hidráulicos, Ministerio de Agricultura y Ganadería, Quito, Ecuador, between 13 December 1988 and 28 July 1989. The sites and their fluoride values (mg/L) are as follows: Cotocollao, 0.10; La Florida, 0.10; La Tolita, 0.40; Agua Blanca, 0.90; Sta. Elena, 0.10; OGSE-MA-172, 0.10; Cruz Loma, 0.00. The Cruz Loma sample was taken from a fresh water stream on top of the mountain Pichincha, altitude about 3000 meters.

It may be more than coincidental that the two high values of fluoride are from sites that also have low caries frequency. The value for La Tolita of 0.40 is well above levels (0.1 to 0.2) recommended for community drinking water in the United States. If this value was present throughout the water supply at the time represented by the skeletal remains, it may well have offered resistance to caries. The very high value of 0.90 for Agua Blanca corresponds to the absence of carious lesions in the small skeletal sample from that site and may have been at a level to create pathological symptoms (skeletal fluorosis).

Of 766 observations for dental abscess, 37 (4.8 percent) noted abscesses (Table 26). The distribution of abscesses was relatively uniform throughout the samples. Overall, females had a higher frequency (7.8 percent) than males (0.9 percent).

TABLE 25.—Frequencies of permanent teeth with carious lesions, associated abscesses, and hypoplasia and those lost antemortem in samples from Ecuador.

Sample	% Carious lesions	% Lost antemortem	% Associated abscesses	% Hypoplastic
Sta. Elena	3	6	1	<1
Cotocollao	2	7	—	<1
La Libertad (OGSE-46)	4	23	4	5
La Tolita Temprano	0	6	0	0
Cumbayá	5	7	6	3
OGSE-MA-172	8	42	12	3
La Tolita Clásico	3	5	5	2
La Tolita Tardío	1	5	5	4
Ayalán non-urn	8	13	3	1
La Florida	2	1	<1	1
Agua Blanca	0	6	0	5
Ayalán urn	11	15	4	6
San Francisco, vestibule	6	8	3	3
Santo Domingo	5	24	1	3
San Francisco, strata cut, upper level	6	11	1	4
San Francisco, strata cut, lower level		89	0	—
San Francisco, atrium	5	4	3	0
San Francisco, church	5	23	6	1
San Francisco, superficial collection, upper level	25	69	6	0
San Francisco, main cloister	15	7	4	0
San Francisco, superficial collection, lower level	32	46	4	0
San Francisco, boxes	13	49	1	1

TABLE 26.—Permanent teeth with associated alveolar abscesses in La Tolita samples.

Sample/Sex	Maxilla								Mandible								Total		
	Incisors		Canines		Premolars		Molars		Incisors		Canines		Premolars		Molars				
	No.	%	No.	%	No.	%	No.	%	No.	%	No.	%	No.	%	No.	%	No.	%	
Mango Montaña																			
Male	0/12	0	0/6	0	0/13	0	0/17	0	0/16	0	0/8	0	0/18	0	0/27	0	0/117	0	
Female	2/18	11	1/9	11	1/16	6	1/14	7	1/27	4	0/13	0	0/26	0	10/37	27	16/160	10.0	
?	2/10	20	0/5	0	4/13	31	1/10	10	0/8	0	1/6	17	2/14	14	3/20	15	13/86	15.1	
Mango Montaña Cama																			
Male	0/4	0	0/2	0	0/4	0	0/6	0	0/8	0	0/4	0	0/8	0	0/12	0	0/48	0	
Female	0/4	0	0/2	0	0/4	0	0/3	0	0/4	0	0/2	0	0/4	0	0/6	0	0/29	0	
?	0/10	0	0/5	0	0/10	0	0/13	0	0/30	0	0/14	0	0/24	0	0/34	0	0/140	0	
Pozo Iglesia																			
Female	0/3	0	0/1	0	0/3	0	0/1	0	0/8	0	0/4	0	0/8	0	2/12	17	2/40	5.0	
H9																			
Female			—	—	—	—	—	—	—	—			0/1	0	0/3	0	0/4	0	
Tola Pajarito																			
Male		—	—		—	0/2	0	1/2	50	1/1	100	0/4	0	0/4	0	2/13	15.4		
Female	0/3	0	0/2	0	0/4	0	0/2	0	0/5	0	0/4	0	0/11	0	4/17	24	4/48	8.3	
Tola Mango																			
Male	0/4	0	0/2	0	0/4	0	0/3	0	0/4	0	0/2	0	0/4	0	0/6	0	0/29	0	
?	—	—	—		—	—			0/4	0	0/2	0	0/4	0	0/5	0	0/15	0	
Other areas																			
Male	—	—	—		—				0/2	0	0/2	0	0/4	0	0/6	0	0/14	0	
?	0/1	0	0/1	0	0/2	0	0/2	0	—	—	—	—	0/3	0	0/4	0	0/23	0	

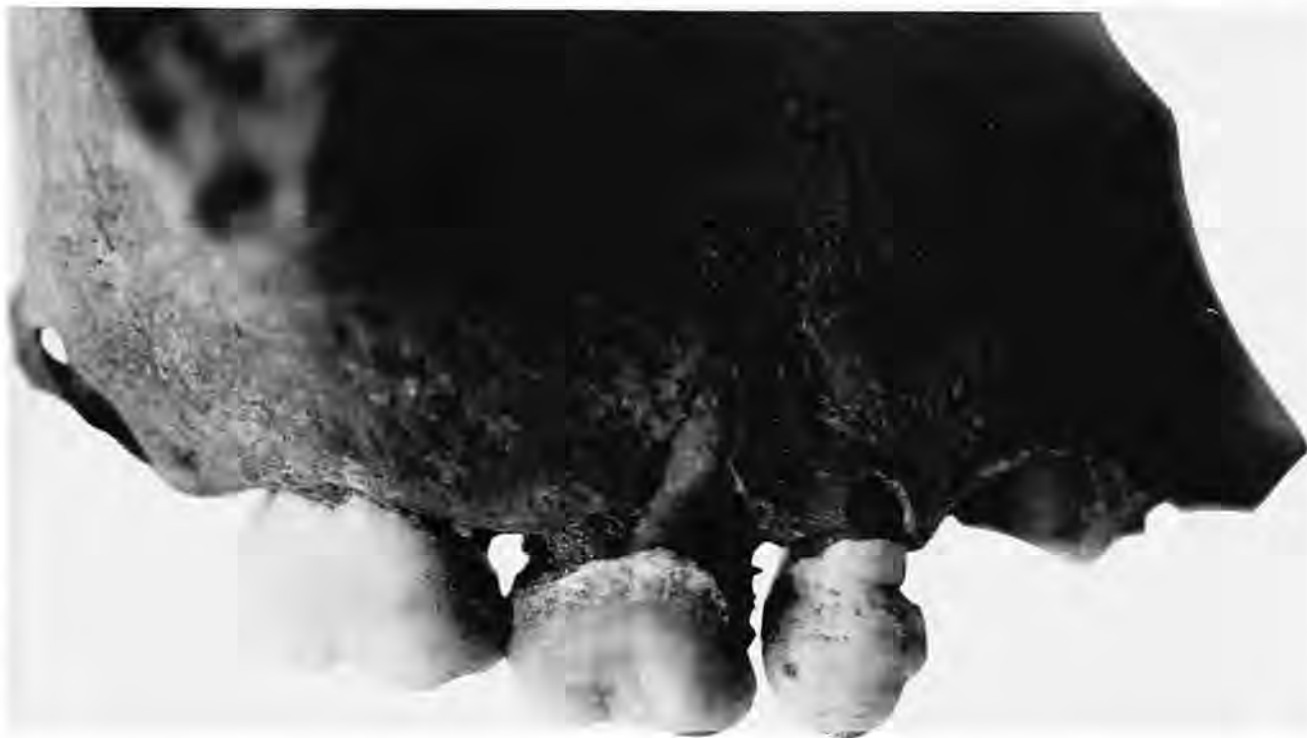

FIGURE 28.—Moderate calculus on maxillary right deciduous second molar and hypoplasia on permanent first premolar.

These figures fall within the high end of the range for previously studied Ecuadorean samples (Table 25). The high frequencies of dental abscess are surprising given the low frequencies of dental caries. Presumably, the abscesses largely result from extensive occlusal wear on the teeth due to attrition or some other factor besides caries.

Tables 27 through 30 present data on the distribution of dental calculus on teeth within the samples. Calculus was recorded for the buccal and lingual surface of each tooth (Figure 28). If present, each deposit was scored as either slight, medium, or large, using previously established standards. Of 598 observations on buccal surfaces, 12 percent were absent, 71 percent slight, 20 percent medium, and five percent large. The corresponding values for all lingual surfaces were 14 percent absent, 68 percent slight, 15 percent medium, and three percent large. Thus slightly more calculus was present on the buccal surfaces than on the lingual. Calculus was slightly more common on the mandibular teeth (both buccal and lingual) than on the maxillary. For both the lingual and buccal surfaces and maxillary and mandibular teeth, calculus was absent most often on the molar teeth. No clear differences in calculus distribution were apparent between the sexes or among the samples.

Only 19 of 626 (three percent) teeth in the entire La Tolita sample displayed 21 indications of enamel hypoplasia (Table 31). These (Figure 28) were confined to three of the samples

(Mango Montaña General, Mango Montaña Cama, and Pozo Iglesia). Only about eight individuals were involved, two adult males, two adult females, one ten year old, one five year old, and two individuals of unknown age and sex. Of the 21 lesions, four formed at about three years of age, 12 at about four years, four at about five years, and one at 12 years. Within the eight individuals with hypoplasia, two formed at about age three, three at about age four, two at age five, and one at age 12. For the La Tolita Tardío sample, 18 of 488 teeth displayed hypoplasia for a frequency of 3.69 percent. Two of the 124 Clásico teeth had hypoplasia. As shown in Table 25, the values for La Tolita are within the range of other Ecuadorean samples.

### Isotope Analysis

Stable isotope analysis offers an opportunity to examine aspects of diet. Stable carbon isotope ratios differentiate between diets rich in  $C_3$  plants and  $C_3$ -consuming animals and those involving  $C_4$  plants (van der Merwe, 1982). Maize would have been the only  $C_4$  plant utilized at La Tolita. All others would have been  $C_3$  plants. Isotope ratios around  $-20$  indicate  $C_3$  plant consumption. Values of  $-6$  to  $-15$  indicate varying dependence on  $C_4$  plants. Marine food diets are less negative ( $-10$  to  $-15$ ) (Schoeninger et al., 1983) than diets of  $C_3$  plants.

Two bone samples from La Tolita were analyzed for isotope

TABLE 27.—Calculus on the lingual surfaces of permanent maxillary teeth in La Tolita samples.

Sample/Sex	Maxilla																
	Incisors				Canines				Premolars				Molars				
	A	S	M	L	A	S	M	L	A	S	M	L	A	S	M	L	
Mango Montaña																	
Male	3	7	0	0	2	3	0	1	2	10	1	0	11	10	2	0	
Female	3	16	1	0	1	10	1	0	3	23	1	0	2	25	2	0	
?	3	7	0	0	1	4	0	0	6	7	0	0	7	8	0	0	
Mango Montaña Cama																	
Male	0	0	0	0	0	2	0	0	0	4	0	0	0	4	0	0	
Female	0	2	0	0	0	2	0	0	0	4	0	0	0	4	0	0	
?	2	7	0	0	0	4	0	0	0	6	0	0	0	8	0	0	
Pozo Iglesia																	
Female	2	1	0	0	1	0	0	0	3	1	0	0	1	0	0	0	
Tola Pajarito																	
Male	0	1	2	0	0	1	1	0	0	4	0	0	1	4	0	0	
Female	0	0	0	0	0	2	0	0	0	6	0	0	1	3	0	0	
?	0	1	0	0	0	0	0	0	1	0	0	0	0	4	0	0	
Tola Mango																	
Male	0	1	3	0	0	2	0	0	0	4	0	0	0	5	1	0	
Other areas																	
Male	0	1	0	0	0	0	0	0	0	0	0	0	0	0	0	0	
?	3	1	0	0	0	1	0	0	1	1	0	0	4	1	0	0	

TABLE 28.—Calculus on the lingual surfaces of permanent mandibular teeth in La Tolita samples.

Sample/Sex	Mandible																
	Incisors				Canines				Premolars				Molars				
	A	S	M	L	A	S	M	L	A	S	M	L	A	S	M	L	
Mango Montaña																	
Male	1	4	0	2	0	1	1	1	1	3	3	3	3	10	7	0	
Female	0	4	7	5	0	5	2	2	0	17	7	1	0	20	10	1	
?	1	2	1	0	0	3	0	0	2	7	2	0	4	8	3	0	
Mango Montaña Cama																	
Male	0	4	4	0	0	2	2	0	0	6	2	0	0	10	0	0	
Female	0	0	0	0	0	1	0	0	0	0	2	0	0	4	0	0	
?	0	3	6	0	0	3	1	0	0	12	0	0	0	18	5	1	
Pozo Iglesia																	
Female	0	3	0	0	0	1	0	0	0	3	0	0	1	2	0	0	
H9																	
Female	0	0	0	0	0	0	0	0	0	0	0	0	0	2	0	0	
Tola Pajarito																	
Male	0	1	1	0	0	1	0	0	0	0	1	1	0	3	0	0	
Female	0	1	0	0	0	1	0	0	0	3	0	0	0	4	0	0	
Tola Mango																	
Male	0	3	1	0	0	2	0	0	0	3	1	0	0	5	1	0	
?	0	0	0	0	0	0	0	0	0	0	0	0	1	0	0	0	
Other areas																	
Male	0	0	1	1	0	0	1	0	0	1	2	0	0	4	2	0	
?	0	0	0	0	1	0	0	0	2	0	0	0	1	2	0	0	

TABLE 29.—Calculus on the buccal surfaces of permanent maxillary teeth in La Tolita samples.

Sample/Sex	Maxilla															
	Incisors				Canines				Premolars				Molars			
	A	S	M	L	A	S	M	L	A	S	M	L	A	S	M	L
Mango Montaña																
Male	2	4	4	0	2	2	2	0	3	5	5	0	9	5	8	1
Female	0	14	4	0	0	9	3	0	1	23	3	0	1	16	11	2
?	3	6	1	0	1	4	0	0	6	8	0	0	7	5	2	0
Mango Montaña Cama																
Male	0	0	0	0	0	2	0	0	0	4	0	0	0	4	0	0
Female	0	2	0	0	0	2	0	0	0	4	0	0	0	1	2	0
?	0	9	0	0	0	4	0	0	0	6	0	0	0	8	0	0
Pozo Iglesia																
Female	2	1	0	0	1	0	0	0	3	1	0	0	1	0	0	0
Tola Pajarito																
Male	0	0	0	3	0	0	2	0	0	0	4	0	0	0	0	5
Female	0	0	0	0	0	0	2	0	0	2	4	0	1	1	2	0
?	0	1	0	0	0	0	0	0	0	1	0	0	0	0	0	0
Tola Mango																
Male	0	2	1	0	0	1	1	0	0	3	1	0	0	5	1	0
Other areas																
Male	0	0	1	0	0	0	0	0	0	0	0	0	0	0	0	0
?	3	1	0	0	1	0	0	0	2	0	0	2	3	2	0	0

content. One sample from Mango Montaña, E4, Prof. 183 yielded a  $\delta^{13}\text{C}$  value of  $-27.93$ . A second sample from 3-TP-T2 produced a  $\delta^{13}\text{C}$  value of  $-12.88$ . The very low value from Mango Montaña probably represents an erroneous reading. The Tola Pajarito value falls within the low range indicating minimal utilization of C4 plants but consistent with a diet with considerable reliance on marine foods.

Nitrogen isotope values generally measure trophic level (Schoeninger and DeNiro, 1984). Values of  $\delta^{15}\text{N}$  are lowest for diets with leguminous plants and are increasingly more positive for nonleguminous plants, herbivores, and omnivores. Maize horticulturists have  $\delta^{15}\text{N}$  values around 9.6; coastal peoples consuming marine vertebrates have values as high as 15 (DeNiro, 1987).

Nitrogen isotope values are not available for the Mango Montaña sample, but the Tola Pajarito sample yielded a  $\delta^{15}\text{N}$  value of 14.54. This very high value is consistent with a coastal diet high in marine vertebrates.

These values are consistent with what is known about the resources available to the La Tolita people. According to Valdez (1987:11), the La Tolita area was rich in natural food resources, including crustaceans from the mangrove areas, small mammals, birds, and fish. Plants from the tropical forest and ocean seafood provided abundant food resources. The preliminary isotope values presented here suggest that these resources were utilized more than maize.

The La Tolita values also are consistent with those reported from other coastal Ecuadorean sites, with slightly more

negative  $\delta^{13}\text{C}$  values than suggested for Valdivia Guangala and Salango Integration samples (van der Merwe et al., 1993).

Van der Merwe et al. (1993) report pre-ceramic  $\delta^{13}\text{C}$  values for the Las Vegas site (OGSE-80) of  $-14.0$  and  $-14.9$ . For the early Formative site of Loma Alta, they report mean values of  $-19.0$  for  $\delta^{13}\text{C}$  and  $+11.7$  for  $\delta^{15}\text{N}$ . Values of  $\delta^{13}\text{C}$  for successive chronological periods are  $-18.8$  for Valdivia 3 Phase,  $-12.3$  for Salango Machalillia Phase,  $-10.1$  for Loma Alta Chorrera Phase,  $-12.5$  for Salango, Chorrera Phase,  $-8.0$  for Regional Development Period, Guangala Phase, and  $-9.0$  for Integration Period Bahia and Manteño Phases.

Nitrogen values reported by van der Merwe et al. (1993) for human bone samples more recent than the early formative are 13.8 for Valdivia 3, 14.0 for Machalillia, 13.1 for Chorrera (Loma Alta), 14.4 for Salango Chorrera, 14.4 for Guangala, and 14.0 for the Bahia and Manteño Phases.

### Summary

The information reported on here expands that available from ancient Ecuador to the important coastal site of La Tolita. Although this report focuses primarily on the biological information gleaned from analysis, the secondary nature of some of the burial features and the cultural modifications of the bones made both during and after life offer cultural information as well. We know that at least some individuals within the earlier Clásico and the later Tardío samples practiced cranial deformation. Remains from both periods revealed cut marks,

TABLE 30.—Calculus on the buccal surfaces of permanent mandibular teeth in La Tolita samples.

Sample/Sex	Mandible															
	Incisors				Canines				Premolars				Molars			
	A	S	M	L	A	S	M	L	A	S	M	L	A	S	M	L
Mango Montaña																
Male	0	5	2	0	0	1	2	0	2	2	5	0	5	10	5	0
Female	0	8	7	1	0	7	3	0	0	24	1	0	0	28	3	0
?	1	2	1	0	0	3	0	0	2	7	2	0	4	8	3	0
Mango Montaña Cama																
Male	0	8	0	0	0	4	0	0	0	8	0	0	0	10	0	0
Female	0	0	0	0	0	0	1	0	0	2	0	0	2	2	0	0
?	0	4	5	0	0	3	1	0	0	12	0	0	0	23	1	0
Pozo Iglesia																
Female	0	1	0	0	0	1	0	0	0	3	0	0	1	1	1	0
H9																
Female	0	0	0	0	0	0	0	0	0	1	0	0	0	1	0	0
Tola Pajarito																
Male	0	0	0	2	0	0	0	1	0	0	1	1	0	0	1	2
Female	0	0	0	0	0	0	1	0	0	3	0	0	0	4	0	0
Tola Mango																
Male	0	3	1	0	0	2	0	0	0	4	0	0	0	6	0	0
?	0	0	0	0	0	0	0	0	0	0	0	0	1	0	0	0
Other areas																
Male	0	0	2	0	0	1	1	0	0	1	2	0	0	4	2	0
?	0	0	0	0	1	0	0	0	2	0	0	0	1	2	0	0

TABLE 31.—Permanent teeth with hypoplasia in La Tolita samples.

Sample	Feature	Sex	Age	Tooth	Location in crown	Estimated age at formation (years)
Mango Montaña	D-3, 29	female	adult	mandibular left M <sub>3</sub>	base	12
	Ent. 1-1	?	10	maxillary right I <sup>1</sup>	base	4
				maxillary right C	1 mm from base	4
				maxillary right C	4 mm from base	4
				maxillary right PM <sup>2</sup>	3 mm from occlusal	4
				maxillary left I <sup>2</sup>	base	4
				maxillary left C	9 mm from occlusal	4
				mandibular left PM <sub>1</sub>	middle of crown	4
				mandibular right C	base	3
				mandibular left C	base	3
Mango Montaña Cama	360	male	adult	mandibular right C	base	3
	296	male	adult	mandibular right C	base	3
				mandibular left C	base	3
	121	?	5	maxillary right C	base	5
				maxillary right PM <sup>1</sup>	base	4
				maxillary right PM <sup>1</sup>	midcrown	5
				maxillary left C	base	5
				maxillary left C	base	4
	loose teeth	?	?	maxillary left C	base	4
	L-2	?	?	maxillary right C	base	5
Pozo Iglesia	Ent. 2	female	adult	maxillary right I <sup>2</sup>	base	4
				maxillary left I <sup>2</sup>	base	4
				mandibular right I <sub>1</sub>	base	4



evidence of intentional flesh removal and/or separation of body parts, and polished artifacts made from human bone.

Comparisons among the La Tolita samples offer information on temporal change within La Tolita. The data suggest that most demographic indicators varied little among the samples. Demographic information at La Tolita could be affected by the complex nature of mortuary procedures at the site, especially if selection for burial at La Tolita favored certain age or sex groups over others. The data tentatively suggest a temporal decrease in the ratio of immature individuals to mature and in the female adult mean age at death.

Skeletal analysis indicates that the temporal transition from Clásico to Tardío involved a slight reduction in trauma, dental caries, and periosteal lesions (likely evidence of infection). The latter two increased between Temprano and Clásico but then decreased from Clásico to Tardío. Increases are seen in living stature and enamel hypoplasia.

These data present mixed signals on health transitions at that time. The reductions of trauma, periosteal lesions, dental caries, and the ratio of immature to adult individuals, coupled with increases in stature, are positive indicators of improving nutrition and health. In contrast, increases in enamel hypoplasia and porotic hyperostosis suggest health declines and an increase in physiological stress. To a large extent, trauma reflects cultural conditions, such as human aggression, technology-related accidents, etc. Dental caries reflects diet, personal hygiene, genetics, and perhaps fluoride levels in drinking water. Periosteal lesions represent bony response to infection or perhaps to trauma. Adult stature is the product of immature growth and the cumulative effects of the many factors that affect growth. The greatest contradiction here is that periosteal lesions and the ratio of immature to adult decrease and stature increases, whereas other indicators of mortality and morbidity

increase, such as enamel hypoplasia and porotic hyperostosis. Collectively, the data suggest that the transition from Clásico to Tardío was not marked by profound biological change, although some possible differences can be noted.

Comparison with other samples reported from Ecuador provides perspective on the La Tolita population. Culturally, a few individuals shared the custom of cranial deformation with other Ecuadorean samples. Very few La Tolita people assumed a habitual kneeling posture that altered the bones of their feet. Although very rare at other Ecuadorean sites, many bones at La Tolita show evidence of perimortem and postmortem modification, including dismemberment and modifying human bones to form artifacts.

Demographically the La Tolita population experienced a relatively high life expectancy with low immature mortality. The ratio of immature individuals to adults was relatively low in the La Tolita samples. They also were comparatively very tall in stature, with low frequencies of porotic hyperostosis, tooth loss, dental hypoplasia, and caries. The caries frequencies are among the lowest yet found in Ecuador.

On the negative side, the frequency of periosteal lesions is comparatively high, as are frequencies of dental abscesses and skeletal trauma.

The general picture of the La Tolita population is that of a well-nourished, healthy population who experienced relatively high rates of skeletal trauma.

Although the samples discussed herein are relatively large in comparison with others reported for Ecuador and other areas of ancient Latin America, they still allow only a partial view of the biology of the people represented. Hopefully, they can be supplemented in the future with additional well-excavated remains.

## Literature Cited

- Bass, William M.  
1987. *Human Osteology, A Laboratory and Field Manual*. Third Edition. Special Publication No. 2, 327 pages, 190 figures. Columbia: Missouri Archaeological Society.
- DeNiro, M.J.  
1987. Stable Isotopy and Archaeology. *American Scientist*, 75:182-191.
- El-Najjar, M.Y., D.J. Ryan, C.G. Turner, III, and B. Luzoff  
1976. The Etiology of Porotic Hyperostosis among the Prehistoric and Historic Anasazi of Southwestern United States. *American Journal of Physical Anthropology*, 44:477-488.
- Ferdon, E.N.  
1940-1941. Reconnaissance in Esmeraldas. *El Palacio*, 47(12):257-274, 48(1):7-15.
- Genovés, S.  
1967. Proportionality of the Long Bones and Their Relation to Stature among Mesoamericans. *American Journal of Physical Anthropology*, 26:67-77.
- Lallo, J.W., G.J. Armelagos, and R.P. Mensforth  
1977. The Role of Diet, Disease, and Physiology in the Origin of Porotic Hyperostosis. *Human Biology*, 49:471-483.
- Leiva, S., and M.C. Montaña  
1994. Informe Final del Proyecto Arqueológico "La Tolita." 737 pages, 127 figures, 176 plates. [Unpublished manuscript, Subdirección Programas Culturales, Banco Central del Ecuador, Quito.]
- Munizaga, J.R.  
1976. Intentional Cranial Deformation in the Pre-Columbian Populations of Ecuador. *American Journal of Physical Anthropology*, 45(3):687-694.
- Neumann, G.K.  
1942. Types of Artificial Deformation in the Eastern United States. *American Antiquity*, 7(3):687-694.
- Ripley, C., and D.H. Ubelaker  
1992. The Ossuary of San Francisco Church, Quito, Ecuador [Abstract]. *American Journal of Physical Anthropology*, Supplement, 14:139.
- Saville, M.  
1910. Archaeological Researches on the Coast of Esmeraldas, Ecuador. *Verhandlungen des XVI Internationalen Amerikanisten-Kongresses, Wien*, pages 331-345.
- Schoeninger, M.J., and M.J. DeNiro  
1984. Nitrogen and Carbon Isotopic Composition of Bone Collagen from Marine and Terrestrial Animals. *Geochimica et Cosmochimica Acta*, 48:625-639.
- Schoeninger, M.J., M.J. DeNiro, and H. Tauber  
1983. Stable Nitrogen Isotope Ratios of Bone Collagen Reflect Marine and Terrestrial Components of Prehistoric Human Diet. *Science*, 220:1381-1383.
- Ubelaker, D.H.  
1979. Skeletal Evidence for Kneeling in Prehistoric Ecuador. *American Journal of Physical Anthropology*, 51(4):679-685.  
1980a. Human Skeletal Remains from Site OGSE-80, A Pre-ceramic Site on the Sta. Elena Peninsula, Coastal Ecuador. *Journal of the Washington Academy of Sciences*, 70(1):3-24.  
1980b. Prehistoric Human Remains from the Cotocollao Site, Pichincha Province, Ecuador. *Journal of the Washington Academy of Sciences*, 70(2):59-74.  
1981. *The Ayalán Cemetery: A Late Integration Period Burial Site on the South Coast of Ecuador*. 175 pages, 119 figures. Washington, D.C.: Smithsonian Institution Press.
1983. Human Skeletal Remains from OGSE-172, an Early Guangala Cemetery Site on the Coast of Ecuador. *Journal of the Washington Academy of Sciences*, 73(1):16-26.
- 1988a. Prehistoric Human Biology at La Tolita, Ecuador; A Preliminary Report. *Journal of the Washington Academy of Sciences*, 78(1):23-37.
- 1988b. Human Remains from OGSE-46, La Libertad, Guayas Province, Ecuador. *Journal of the Washington Academy of Sciences*, 78(1):3-16.
- 1988c. Restos de Esqueletos Humanos del Sitio OGSE-80. In Karen E. Stothert, *La Prehistoria Temprana de la Península de Santa Elena, Ecuador: Cultura Las Vegas*, pages 105-132. Guayaquil: Museos del Banco Central del Ecuador.
- 1988d. Restos Humanos Prehistóricos del Sitio Cotocollao, Provincia del Pichincha, Ecuador. In Marcelo Villalba, *Cotocollao: Una Aldea Formativa del Valle de Quito*. In *Miscelánea Antropológica Ecuatoriana*, series 2, pages 555-571. Quito: Museos del Banco Central del Ecuador.
- 1988e. A Preliminary Report of Analysis of Human Remains from Agua Blanca, A Prehistoric Late Integration Site from Coastal Ecuador. *Journal of the Washington Academy of Sciences*, 78(1):17-22.
1989. *Human Skeletal Remains: Excavation, Analysis, Interpretation*. Second edition, 172 pages, 164 figures. Washington: Taraxacum.
1990. Human Skeletal Remains from "Jardín del Este," Cumbayá, Pichincha, Ecuador. In *La Preservación y Promoción del Patrimonio Cultural del Ecuador*, pages 22-52. Quito: Instituto Nacional de Patrimonio Cultural.
1991. Human Remains from La Florida, Quito, Ecuador. Unpublished manuscript.
1992. Porotic Hyperostosis in Prehistoric Ecuador. In P. Stuart-Macadam and S. Kent, editors, *Diet, Demography, and Disease: Changing Perspectives on Anemia*, pages 201-217. New York: Aldine de Gruyter.
1993. Restos Humanos Esqueléticos de OGSE-MA-172, un Sitio "Guangala Temprano" en la Costa del Ecuador. In *Un Sitio de Guangala Temprano en el Suroeste del Ecuador*, pages 99-112. Guayaquil: Museo Antropológico de Banco Central del Ecuador.
- In press. *Human Skeletal Biology of Convento de San Francisco de Quito*. Quito: Instituto Nacional de Patrimonio Cultural del Ecuador and the Agencia Española de Cooperación Internacional (AECI).
- Ubelaker, Douglas H., and Catherine Ripley  
1992. The Ossuary of San Francisco Church, Quito, Ecuador: Human Skeletal Biology. Unpublished manuscript submitted to the project for the preservation of Convento de San Francisco, Instituto Nacional de Patrimonio Cultural del Ecuador (INPC) and the Agencia Española de Cooperación Internacional (AECI), Quito.
- Uhle, M.  
1927. Estudios Esmeraldeños. *Annales de la Universidad Central*, 39(262): 61 pages, 32 plates. Quito.
- Valdez, Francisco  
1986. Investigaciones Arqueológicas en La Tolita (Esmeraldas, Ecuador). *Miscelánea Antropológica Ecuatoriana*, 6:81-107. Guayaquil: Museos del Banco Central del Ecuador.

1987. *Proyecto Arqueológico, La Tolita (1983-1986)*. 91 pages, 48 figures. Quito: Museo del Banco Central del Ecuador.
1989. La Sociedad Tolita. In *Nuestro Pasado: La Tolita*; pages 5-14. Quito: Museo del Banco Central del Ecuador.
- Valdez, Francisco, Rosangela Adoum, María Soledad Leiva, Alexandra Yopez, and Eugenia Rodríguez (editors)
1989. *Nuestro Pasado: La Tolita*, 57 pages, 9 figures. Quito: Museo del Banco Central.
- van der Merwe, N.J.
1982. Carbon Isotopes, Photosynthesis, and Archaeology. *American Scientist*, 70:596-606.
- van der Merwe, Nikolaas J., Julia A. Lee-Thorp, and J. Scott Raymond
1993. Light, Stable Isotopes and the Subsistence Base of Formative Cultures at Valdivia, Ecuador. In J.B. Lambert and G. Grupe, editors, *Prehistoric Human Bone, Archaeology at the Molecular Level*, pages 63-97. New York: Springer-Verlag.