

The Ossuary of San Francisco Church,  
Quito, Ecuador:  
Human Skeletal Biology

*Douglas H. Ubelaker  
and Catherine E. Ripley*



Smithsonian Institution Press

Washington, D.C.

1999

## ABSTRACT

Ubelaker, Douglas H., and Catherine E. Ripley. The Ossuary of San Francisco Church, Quito, Ecuador: Human Skeletal Biology. *Smithsonian Contributions to Anthropology*, number 42, 32 pages, 10 figures, 19 tables, 1999.—As part of the Columbus quincentenary activities, the Instituto Nacional de Patrimonio Cultural del Ecuador (INPCE) and the Agencia Española de Cooperación Internacional (AECI) attempted to study and restore the Convento de San Francisco de Quito, a facility founded in 1535. In 1990, these efforts included excavation of the central ossuary in the church. This research generated information about the structure of the ossuary as well as human remains. Detailed analysis of the human remains by the authors revealed the presence of at least 226 individuals from five spatial components of the ossuary. The remains likely date from the early history of the church in the sixteenth century to the twentieth century.

Analysis of the five ossuary samples revealed information on mortuary customs, ancestry, cranial and postcranial morphology, living stature, and bone and dental pathology. Most of the data reported herein fall within ranges previously reported from prehistoric and historic samples. Exceptions consist of high values of skeletal trauma, carious lesions, and antemortem loss of teeth reported for some of the ossuary samples.

OFFICIAL PUBLICATION DATE is handstamped in a limited number of initial copies and is recorded in the Institution's annual report, *Annals of the Smithsonian Institution*.

---

### Library of Congress Cataloging-in-Publication Data

Ubelaker, Douglas H.

The ossuary of San Francisco Church, Quito, Ecuador : human skeleton biology / Douglas H. Ubelaker and Catherine E. Ripley.

p. cm. — (Smithsonian contributions to anthropology ; no. 42)

Includes bibliographical references.

1. Convento de San Francisco (Quito, Ecuador) 2. Anthropometry—Ecuador—Quito. 3. Craniology—Ecuador—Quito. 4. Human remains (Archaeology)—Ecuador—Quito. 5. Human skeleton—Ecuador—Quito—Analysis. 6. Ossuaries—Ecuador—Quito. 7. Quito (Ecuador)—Antiquities. I. Ripley, Catherine E. II. Title. III. Series.

GN58.E2U22 1999

599.9'4'0986613—dc21

99-25820

CIP

© The paper used in this publication meets the minimum requirements of the American National Standard for Permanence of Paper for Printed Library Materials Z39.48—1984.

# Contents

	<i>Page</i>
Preface .....	v
Introduction .....	1
Ossuary Excavation .....	2
Radiocarbon Dates .....	3
Ossuary Samples .....	3
Upper-Chamber Superficial Collection .....	3
Upper-Chamber Strata Cut .....	4
Lower-Chamber Superficial Collection .....	11
Lower-Chamber Strata Cut .....	19
Side-Chamber Boxes .....	21
Summary .....	28
Mortuary Practices .....	29
Ancestry .....	29
Stature .....	29
Pathology .....	29
Demographic Profiles .....	31
Literature Cited .....	32

## FIGURES

1. Cribræ orbitalia of right infant orbit, upper-chamber strata cut .....	11
2. Well-remodelled fracture of right tibia, lower-chamber superficial collection .....	14
3. Well-remodelled fracture of right tibia, lower-chamber superficial collection .....	14
4. Depressed fracture associated with metopic suture from lower-chamber superficial collection .....	15
5. Remodelled lesions on frontal and parietals of male from lower-chamber superficial collection .....	16
6. Lesion on endocranial surface of a frontal, lower-chamber superficial collection .....	17
7. Alveolar abscess in a right maxilla, lower-chamber superficial collection .....	19
8. Cut marks on female left femur, Box 3 .....	22
9. Deep pits of parturition, Box 10 .....	24
10. Abnormal porous bone formation on patella, Box 11 .....	25

## TABLES

1. Radiocarbon dates from San Francisco ossuary samples .....	3
2. Cranial measurements from upper-chamber superficial collection .....	4
3. Nonmetric observations from upper-chamber superficial collection .....	4
4. Life table for upper-chamber strata-cut sample .....	9
5. Measurements of crania and mandibles, upper-chamber strata cut .....	9
6. Nonmetric observations, upper-chamber strata cut .....	10
7. Distribution of carious lesions on permanent tooth surfaces, upper-chamber strata cut .....	11
8. Measurements of crania, lower-chamber superficial collection .....	12
9. Nonmetric observations of male crania, lower-chamber superficial collection .....	13
10. Nonmetric observations of female crania, lower-chamber superficial collection .....	13

11. Dental disease in lower-chamber superficial collection .....	18
12. Skeletal contents of each box .....	26
13. Life table for box sample .....	26
14. Measurements of male crania and mandibles, box sample .....	27
15. Measurements of female crania and mandibles, box sample .....	27
16. Nonmetric observations of male crania and mandibles, box sample .....	28
17. Nonmetric observations of female crania and mandibles, box sample .....	28
18. Lines of increased density in immature tibiae .....	30
19. Lines of increased density in mature tibiae .....	30

## Preface

The research reported herein represents part of a long-term effort on the part of the first author to collaborate with archeologists working in Ecuador in the recovery and study of human remains from archeological contexts. This new information supplements that previously available from many Ecuadorean sites dating from both prehistoric and historic times. The investigation of the San Francisco ossuary was possible because of the generous invitation to participate made to us by the staffs of the Instituto Nacional de Patrimonio Cultural del Ecuador (INPCE) and the Agencia Española de Cooperación Internacional (AECI). The authors are especially grateful for the hospitality extended to us by José Ramón Duralde, then director of the projects representing Spain, and Paulina Terán, archeologist in charge of excavations. José Ramón Duralde facilitated the authors' work through his administrative assistance and enthusiastic support. Paulina Terán supervised the excavations and provided space, interpretation, and other considerable assistance that made the research possible. The staff of the Convento de San Francisco de Quito and all project personnel were very gracious in allowing the intrusion of our research into their midst. Throughout the project, they made us feel welcome and expressed genuine interest and appreciation for the information we gradually extracted from the samples. Personnel directed by Paulina Terán assisted in the excavation, processing, and storage of the remains. Without their immense assistance this research would not have been possible.

We recognize that the information reported herein offers an incomplete vision of the physical characteristics and health of the past populations of Quito. This study also represents a relatively small contribution to the overall study of the Convento, including its archeological, architectural, and artistic history. We hope, however, that in this small way, we have allowed the past peoples of the Convento to tell their story. The remains offer us some information about the people represented, their physical characteristics, and their problems. Together with other such studies of human remains from well-controlled excavated sites, the information helps us to understand the biocultural history of the people of this area and how aspects of their lives changed through time.

# The Ossuary of San Francisco Church, Quito, Ecuador: Human Skeletal Biology

*Douglas H. Ubelaker  
and Catherine E. Ripley*

## Introduction

Recent years have witnessed a surge of scholarly interest in the human skeletal biology of archeologically recovered remains from historic contexts. Such remains usually become available for study through construction projects or other accidental discovery. As techniques in skeletal-biology analysis have improved, scholars have shifted their attention to such remains with the understanding of their rich potential to supplement the historical record.

In Ecuador, as traditionally in all of the Americas, such research has concentrated on remains from pre-European contact samples (e.g., Munizaga, 1965, 1976; Klepinger et al., 1977; Klepinger, 1979; Ubelaker, 1980a, 1980b, 1981, 1983, 1988a, 1988b, 1988c, 1988d, 1988e, 1990). This effort has produced a great deal of information about biological and biocultural aspects of the lives of these people. This information also provides a long-term context in which to view similar attributes of peoples living in Ecuador during the historic periods. Collectively, these data allow the viewing of long-term trends in health, disease, growth and development, and other biologically related aspects of human history in this area.

In Ecuador, analysis of human remains of historic-period origin has concentrated on samples from Quito recovered during

archeological/architectural study of the early historic structures in the old central part of the city. Data are available from the Hospital San Juan de Dios, Convento de Santo Domingo, and Convento de San Francisco.

The Hospital San Juan de Dios was founded March 9, 1565, and was used until about 1974. It was the first hospital formed in Ecuador, and the facility included a church, infirmaries, storage rooms, and patios. With financial support from the Instituto Ecuatoriano de Obras Sanitarias (Section of Health Ministry), excavations in 1988 and 1989 were conducted in association with the restoration and architectural examination of the facility. These excavations revealed an ossuary as well as a group of individual skeletons. The ossuary remains likely date between 1705 and 1755, whereas the individual deposits date from 1710 to 1810. Analysis was confined to crania from the ossuary and to secondary samples from the individual deposits within the church (Ubelaker and Rousseau, 1993).

A sample of historic-period human remains also has been examined from the Convento de Santo Domingo in Quito. This sample was generated through archeological activity conducted as part of a joint Ecuadorian-Belgian effort to examine the early history of the facility. Human remains were recovered as secondary bone deposits within the Capilla (Chapel) de Santa Rosa and have been broadly dated between AD 1500 and 1650 (Ubelaker, 1995).

The largest sample of human remains from the historic period in Ecuador originates from excavations conducted at the Convento de San Francisco de Quito. The Convento was founded in 1535 and was initially constructed of adobe. Construction of the ornate Church of San Francisco and the associated main cloister were completed in the early seventeenth century. Throughout its history, the facility has functioned also as a cemetery. Although a law was passed in 1829 requiring city burial in a formal cemetery located elsewhere in the city, some

---

*Douglas H. Ubelaker, Department of Anthropology, National Museum of Natural History, Smithsonian Institution, Washington, D.C. 20560-0112. Catherine E. Ripley, Department of Anthropology, Arizona State University, Tempe, Arizona 85287.*

*Review Chairperson: Dennis Stanford, Department of Anthropology, National Museum of Natural History, Smithsonian Institution, Washington, D.C. 20560-0112.*

*Reviewers: William Bass, Professor Emeritus, The University of Tennessee, Knoxville, Tennessee 37996-0720; John W. Verano, Tulane University, New Orleans, Louisiana 70118-5670.*

decedents continued to be deposited within niches of the church.

As part of the Columbus quincentenary activities, the Instituto Nacional de Patrimonio Cultural del Ecuador (INPCE) and the Agencia Española de Cooperación Internacional (AECI) began a project to restore the Convento de San Francisco and its artistic content. This effort included archeological excavations in and around the facility, conducted between 1987 and 1993, designed to supplement the historical record (Terán de Rodríguez, 1988), but which also discovered abundant samples of human remains. As a result of these efforts, considerable information has been amassed on the history of the Convento and its people (Terán de Rodríguez, 1988).

Before July 1990, archeological excavations in and around the Convento recovered over 200 well-documented human skeletons that revealed previously unknown information about the populations buried in the church, including their physical characteristics and their disease experience (Ubelaker, 1994a). These samples originated from the *zaguán* (entrance to the Convento) before AD 1570, from the atrium and *pretil*, the area in front of the church above the plaza (before 1647 until the early eighteenth century), from within the church itself (AD 1535–1858), and from under the altar of Santa Rosa in the main cloister area (AD 1730–1858) of the Convento.

#### OSSUARY EXCAVATION

In July of 1990, the archeological team headed by archeologist Paulina Terán decided to shift its investigative effort to the main ossuary of the church. The existence of the ossuary and its superficial contents had long been recognized by church officials and the archeological team; however, details of the ossuary contents, the people represented in its chambers, and the dates of its construction and use remained unknown. The common opinion held by church officials was that although some skeletal remains had been deposited in the lower chamber as recently as 30 years ago, most of the ossuary contents were very old, with some remains likely dating back to the construction of the church itself in the sixteenth century.

The entire ossuary is located beneath the Chapel of the Virgin of Pilar de Saragoza and is accessible through a trap-door in the wooden floor of the church, immediately in front of the chapel. The ossuary is divided architecturally into three chambers. The upper, dome-roofed, square-based chamber contains a large amount of mostly disarticulated human skeletal remains mixed with wood, cloth, and a great deal of loose soil. The dimensions of the floor of the upper chamber of the ossuary appear to approximate the dimensions of the chapel.

In the center of the upper chamber is a cylindrical structure covered with a lid. Removal of the lid revealed a shaft entrance to a lower level of the chamber, the ceiling of which forms the floor of the upper chamber. This square chamber is several meters below the floor of the upper chamber, and, like the up-

per chamber, it is partially filled with disarticulated human remains.

On the opposite side of the steps to the upper chamber of the ossuary is a narrow opening leading to a smaller chamber containing 12 boxes of human bones. Some of these boxes had broken open, and their skeletal contents either were visible in the boxes or had fallen out onto the floor of the room. The exterior of one box displayed a cross and another displayed initials.

To learn more about the architecture and construction of the ossuary chambers and the people represented therein, archeological excavations were initiated in July 1990 and were completed in late August 1990.

Initially, most of the remains collected were those resting on top of the more concentrated deposits from both the upper and lower chambers. These "superficial" collections were made for three principal reasons: (1) they offered a rapid means to acquire sizeable samples of the upper levels of the two chambers; (2) the remains on the surface would have been damaged unavoidably by the process of excavating and recording in the two chambers; and (3) removal of remains from the extreme upper levels might separate recent deposits of remains in the chambers from the older remains at lower levels.

The contents of all boxes in the side chamber also were removed for analysis. Each box was individually numbered, and the content of each box was analyzed separately. The boxes themselves were too large to be removed easily from the chamber.

Excavations were conducted in both the upper and lower chambers. In the upper chamber, an area measuring 1.0 m × 2.5 m was excavated along the north side of the central shaft, midway between the ossuary entrance and the entrance to the side room. The excavation proceeded downward in 20 cm levels. All articulated bones encountered were identified, numbered, and packaged separately for analysis. These articulations include three primary skeletons that were encountered at lower levels. All skeletal remains and cultural materials recovered from the excavation were labeled with content and provenience information.

The same procedure was followed in the lower chamber. In that area, an excavation was conducted along the southeast side. No articulations were noted, however, and the bones were poorly preserved because of the high humidity.

Thanks to a monumental effort by the archeological staff of the project, all remains were carefully removed, washed, dried, and prepared for analysis immediately after excavation. This magnificent organization enabled analysis to proceed simultaneously with excavation. Ultimately, it enabled analysis to be completed by the time of the authors' departure in late August 1990.

In the laboratory, all human remains were carefully inventoried, reconstructed when necessary, measured, photographed, and repacked for storage. Analysis largely followed procedures established in previous analysis of Ecuadorean human remains (Ubelaker, 1980a, 1980b, 1981, 1983, 1988a, 1988b, 1988c,

1988d, 1988e, 1988f, 1990, 1994a). Methods of estimating age at death, sex, ancestry, and stature mostly follow those outlined by Ubelaker (1989). Radiographs of pathological specimens and other special remains were taken at the medical clinic associated with the Convento de San Francisco.

The frequency of teeth lost antemortem was calculated by dividing the number of observations on teeth lost antemortem by the total number of observations on teeth present and teeth absent (as indicated by the presence of teeth and/or the condition of the bone alveolar processes).

#### RADIOCARBON DATES

Radiocarbon dates are now available for five samples recovered from the 1990 San Francisco excavations. All samples were analyzed by Beta Analytic Inc. of Coral Gables, Florida. According to Beta Analytic, bone samples were physically cleaned for removal of extraneous materials. Bones were then crushed and placed in a solution of cold acid. The acid solution was periodically renewed over a period of several days as the mineral portion of the bone dissolved. The remaining collagen fractions were then washed in deionized water and combusted in an enclosed system. Good collagen was obtained for all reported dates, although two samples of human bone yielded insufficient collagen and are not reported herein.

All rootlets were removed from the submitted wood samples. They were then soaked in a routine series of acid, alkali, and acid solutions. Benzene syntheses and counting were then reported to have proceeded normally.

The resulting dates (Table 1) are reported as radiocarbon years before AD 1950. The dates tentatively suggest that the upper-chamber superficial collection dates to about AD 1730 (AD 1670–1790). Two dates from a stratigraphic cut (strata cut) excavated in the upper chamber suggest a date between AD 1540 and 1650.

The one date for the lower-chamber superficial collection of AD 1830 suggests a date between AD 1770 and 1890; however, the intrusion of more recent bones makes this date difficult to interpret. The custodian of the church indicated he had deposited remains of some individuals in the lower chamber within the previous 20 years. He indicated that these individuals were church officials or those who worked for the church. Excavation of this sample recovered a femur wrapped in a newspaper dated 1963. The one good wood date of AD 1640 (AD 1580–1700) from the lower-chamber strata cut indicates that both upper and lower chambers most likely received their

first deposits in the early history of the church. Archeological evidence suggests that the sample from the boxes in the side chamber date from relatively modern times, likely between AD 1850 and 1940.

The five radiocarbon dates reported in Table 1 offer some chronological information; however, their relatively recent nature and the range of overlap precludes any exact dating assessment. Additional dating of other material from these contexts may help clarify these chronological issues.

The following is a result of the analysis outlined above, with separate discussion of the principal samples from the ossuary: the superficial collection of the upper chamber, superficial collection of the lower chamber, strata cut of the upper chamber, strata cut of the lower chamber, and boxes of the side chamber.

#### Ossuary Samples

##### UPPER-CHAMBER SUPERFICIAL COLLECTION

For this sample, all remains that were not imbedded in the soil were collected. All remains were disarticulated except for one adult left scapula and humerus. In the laboratory, the remains of immature and mature individuals were separated and analyzed.

**TOTAL INVENTORY.**—Immature bones present are four left and two right humeri, three left ulnae, five left and four right femora, four left and five right tibiae, two right clavicles, one right scapula, two right temporals, two right mandibles, one right ilium, eight ribs, one vertebra, six left and two right frontals, and seven left and three right parietals.

Adult bones present in the collection consist of eight left and three right humeri, two left radii, three left and two other ulnae, four left and four right femora, five left and five right tibiae, two unisided tibiae, one left and six other fibulae, three left and one right clavicle, five left scapulae, three left and three right temporals, five mandibles, three left and four right innominate, one left patella, one first cervical vertebra, three other cervical vertebrae, eight thoracic vertebrae, three sacra, two right calcanea, one right talus, one navicular, one right second metatarsal, one left third and one left fourth metatarsal, and 23 ribs. Two relatively complete crania are present and can be associated with two of the mandibles.

**AGE AT DEATH.**—Ages at death were estimated for each of the long bones by comparing their maximum lengths with long-bone growth data derived from other studies (Ubelaker, 1989). These long bones were then sorted by age at death to assess the minimum number of individuals represented. This process suggests that at least 13 immature individuals are present. The major bones present of each age category are as follows: newborn, one left femur; 6-month-old, one right femur, one left tibia, two right tibiae, and one left humerus; 6-month-old to 1-year-old, two left femora, one right femur; 1.5- to 2-year-old, one left tibia, one right tibia, one left humerus, and one right humerus; 2.5- to 3-year-old, two left femora, two left tibiae, two right tibiae, one right ulna, and one left humerus; 3.5- to 4-

TABLE 1.—Radiocarbon dates from San Francisco ossuary samples.

Sample number	Collection	Field no.	Material	Date
Beta 44482	upper superficial	801	human bone	220 ± 60 BP
Beta 40435	upper strata cut	712	wood	410 ± 80 BP
Beta 39527	upper strata cut	712	human bone	300 ± 70 BP
Beta 44481	lower superficial	800	human bone	120 ± 60 BP
Beta 39528	lower strata cut	726	wood	310 ± 60 BP



year-old, one right femur; 5-year-old, one right femur; 6- to 7-year-old, one right ulna, one right ilium, and one right humerus; 10-year-old, one right ulna; and 11.5-year-old, one left humerus.

Eight adults are represented in this sample. The innominates represent three females ages 30–40, 40–50, and 50–60, and three males, two aged 40–50 and one aged 50–60. One cranium is from the 30- to 40-year-old female. The other cranium originates from a man of greater than 70 years. The 70-year-old cranium is edentulous and shows marked thinning over much of the parietals. Areas of thinning on the left parietal measure 26 mm × 51 mm, 20 mm × 22 mm, and 18 mm × 18 mm. The right parietal displays one area of thinning, measuring 25 mm × 27 mm.

**LIVING STATURE.**—Six statures can be calculated from the adult individuals. Four femora suggest living statures of 166 cm (male), 161 cm (male), and two of 153 cm (females). Two right tibiae suggest living statures of 156 and 159 cm (sex undetermined). These data suggest a male mean of about 164 cm (two femora) and a female mean of about 153 cm (two femora).

**MEASUREMENTS AND OBSERVATIONS.**—Measurements and observations were recorded on two crania, a male and a female (Tables 2, 3). Cranium 1 is the very old male with marked parietal thinning. Cranium 2 is a 35- to 40-year-old female with no pathological alterations.

**PATHOLOGY.**—Bone pathology of the immature remains is confined to slight porosity in the left and right orbits of a 2-year-old infant. Such porosity is usually considered a minimal expression of porotic hyperostosis, a condition thought to be associated with chronic anemia.

Minimal pathological changes were noted in the adult sample. The glenoid cavity of one left scapula shows marked arthritic change. Well-remodelled periosteal lesions are present on the distal diaphysis of a left femur and also on the lateral surface of the proximal midshaft (94 mm from proximal end) of a right tibia. One right rib also shows a well-remodelled periosteal lesion about 8.5 cm from the vertebral end. The ratio of bones with periosteal lesions (3) to adults in the sample (8) is 0.38.

Among the immature individuals, only three deciduous teeth are present. These lack carious lesions, calculus, and any evidence of associated alveolar abscess.

Among the adult remains, only eight permanent teeth are present. Two of these show carious lesions (25%). One of these lesions measures 4 mm in length and is located on the lingual surface of a right second maxillary premolar. The other lesion measures 3 mm in length and was found on the crown of a left first maxillary molar. None of these eight teeth display hypoplasia.

Of 99 observations possible on the presence or absence of adult teeth, 68 presented evidence of antemortem absence (69%). Of 77 observations on alveolar abscess associated with specific teeth, only five (6%) were noted. These were all mandibular teeth: three incisors, one canine, and one first premolar.

TABLE 2.—Cranial measurements from upper-chamber superficial collection.

Measurement	Cranium 1 (male)	Cranium 2 (female)
Auricular height	113	117
Porion-bregma	109	116
Cranial length	186	169
Cranial breadth	142	140
Basion-bregma	168	136
Minimum frontal breadth	95	91
Upper facial height	61	61
Facial breadth	129	126
Nasal height	48	42
Nasal breadth	24	24
Orbital height	32	33
Orbital breadth	41	40
Maxillo-alveolar length	50	49
Maxillo-alveolar breadth	57	49
Palatal length	45	44
Palatal breadth	38	37

TABLE 3.—Nonmetric observations from upper-chamber superficial collection. Observations on skeletal features that are not sided straddle columns. (L=left, R=right, A=absent, P=present.)

Skeletal feature	Cranium 1 (male)		Cranium 2 (female)	
	L	R	L	R
Frontal grooves	A	A	A	A
Supraorbital foramen	A	A	A	A
Trochlear spur	A	A	A	A
Accessory optic canal	A	A	A	A
Infraorbital suture	A	A	P	P
Os japonicum trace	A	A	P	P
Wormian bones	A	A	P	P
Parietal process of temporal squama	A	A	A	A
Squamoparietal synostosis	A	A	A	A
Auditory exostoses	A	A	A	A
Pharyngeal fossa		A		A
Paracondylar process	A	A	A	A
Intercondylar canal	A	A	A	A
Odonto-occipital articulation		A		A
Divided hypoglossal canal	A	A	A	A
Postcondylar canal	A	A	A	A
Marginal foramen of tympanic plate	A	A	A	A
Tympanic dehiscence	P	P	A	A

As in most Ecuadorean samples, calculus was minimally expressed on the eight permanent teeth present. On the buccal surfaces, calculus was absent on one tooth, slight on four teeth, and medium on three teeth. On the lingual surfaces, calculus was absent on one tooth, and slight on seven teeth.

#### UPPER-CHAMBER STRATA CUT

Remains in this sample were recovered from a 1.0 m × 2.5 m stratigraphic cut that was excavated in the upper chamber. During excavation, notation was made of any evidence of skeletal articulation. These articulations represent bones that appeared in situ to be in correct anatomical order and/or bones of approximately the same area of the skeleton that seemed to be held together by fabric. Each of these articulations was record-

ed and bagged separately for analysis. The content of each of the articulations was cleaned and studied separately. After careful inventory of the contents of each, the remains were mixed with all of the other remains in the strata cut for the total inventory.

**ARTICULATIONS.**—The following is a complete listing of the skeletal content of each of these articulations. Presumably, these articulations represent individuals who were deposited in the ossuary relatively soon after death, before soft tissue decomposition. For each articulation identified during excavation, the following listing first provides an indication of the bones that were identified as being articulated during the excavation. The actual bones identified in the laboratory from that articulation are then presented. In some cases, several recovered bones do not normally articulate with others that were found in the same “articulation.” Presumably, these represent disarticulated bones that were located in the immediate area and were mistakenly picked up by the workers.

*Articulation 1: tibia, fibula, and patella:* Bones recovered are the left tibia and left patella of a male, 25–40 years of age.

*Articulation 2: calcaneus, talus, and cuneiform:* Bones recovered are the left calcaneus and talus of a male, 20–40 years of age.

*Articulation 3: vertebrae and ribs:* Bones recovered are all seven cervical vertebrae and four thoracic vertebrae of an adult, sex undetermined, aged 23–28 years.

*Articulation 4: vertebrae, ribs, scapula, humerus, radius, and ulna:* Bones recovered are a left humerus, left radius, left ulna, left scapula, manubrium, nine thoracic vertebrae, four lumbar vertebrae, seven left ribs, and nine right ribs. The bones appear to represent an adult of undetermined sex, aged 40–55 years.

*Articulation 5: radius and ulna:* Bones recovered consist of the left radius and left ulna of an adult male, 45–60 years of age.

*Articulation 6: vertebrae and ribs:* Bones recovered are the gladiolus, six thoracic vertebrae, one lumbar vertebra, three left ribs, and seven right ribs. The bones originate from a small adult of undetermined sex between the ages of 50 and 65 years.

*Articulation 7: radius and ulna:* Bones recovered consist of the right radius and right ulna of an adult, sex undetermined, between the ages of 20 and 40 years.

*Articulation 8: ribs and vertebrae:* Bones recovered consist of both clavicles, seven thoracic vertebrae, seven left ribs, and six right ribs of a young adult, sex undetermined, 30–35 years of age.

*Articulation 9: tibia and fibula:* Bones recovered consist of one right tibia and one right fibula of an infant about 6 months of age.

*Articulation 10: radius and ulna:* Bones recovered consist of one left radius and one right ulna of an infant 1.5 years of age.

*Articulation 11: radius and ulna:* Bones recovered consist of a right radius and right ulna of a 6-month-old infant.

*Articulation 12: ribs and vertebrae:* Bones recovered consist of seven left and seven right ribs and six vertebrae of a child between 2 and 3 years of age.

*Articulation 13: tibia and fibula:* Bones recovered consist of a left tibia and one fibula of a 1.5-year-old child.

*Articulation 14: three ribs:* Bones recovered consist of three ribs of an adult, sex undetermined, aged 60–80 years.

*Articulation 15: ribs and vertebrae:* Bones recovered consist of a left clavicle, five left ribs, and four vertebrae. The bones appear to relate to a child of between 1.5 and 3 years of age.

*Articulation 16: ribs, humerus, radius, and ulna:* Bones recovered consist of a right humerus, right radius, right ulna, left clavicle, right scapula, one left rib, three right ribs, one carpal or tarsal, and one vertebra. Most of these bones are from a newborn.

*Articulation 17: radius and ulna:* Bones recovered are a right radius and right ulna from a 6-month-old infant.

*Articulation 18: radius and ulna:* Bones recovered are a left radius and left ulna of a newborn.

*Articulation 19: ilium and femur:* Bones recovered are a left femur and a left ilium of a newborn.

*Articulation 20: ribs and vertebrae:* Bones recovered are a left radius, left ulna, and 14 vertebrae of a 6-month-old infant.

*Articulation 21: ribs:* Bones recovered are two left and two right ribs of a young infant, aged newborn to 6 months.

*Articulation 22: carpals:* Bones recovered are a left lunate, right lesser multangular, and left capitate of an adult of undetermined sex.

*Articulation 23: vertebrae and rib:* Bones recovered are two cervical vertebrae and one right rib of an adult, sex undetermined, aged 23–27 years.

*Articulation 24: sternum:* Bones recovered are a left ulna and gladiolus of an adult, sex undetermined, 25–40 years of age.

*Articulation 25: clavicles:* Bones recovered are two left clavicles and one manubrium of adults of undetermined sex.

*Articulation 26: ribs and vertebrae:* Bones recovered are one left tibia, one left clavicle, seven ribs, and 11 vertebrae of a newborn.

*Articulation 27: femur, fibula, and tibia:* Bones recovered are a left femur, right tibia, and fibula of a newborn.

*Articulation 28: radius and ulna:* Bones recovered are a left radius and left ulna of an adult, sex undetermined, aged 25–40 years.

*Articulation 29: ribs and vertebrae:* Bones recovered are a right ulna, right clavicle, three left ribs, six right ribs, and five vertebrae of a 6-month-old child.

*Articulation 30: tibia and fibula:* Bones recovered are a left tibia and left fibula of an adult, sex undetermined, aged 25–40 years.

*Articulation 31: tibia and fibula:* Bones recovered are a left tibia and left fibula of a 6-month to 1.5-year-old infant.

*Articulation 32: femur and tibia:* Bones recovered are a right femur and a right tibia of an adult male, 25–40 years of age.

*Articulation 33: ribs and vertebrae:* Bones recovered are three ribs and seven vertebrae of a 1- to 2-year-old infant.

*Articulation 34: vertebrae:* Bones recovered are five thoracic vertebrae of an adult, sex undetermined, aged 23–30 years.

*Articulation 35: tibia and fibula:* Bones recovered are a left tibia and right fibula of an adult, sex undetermined, 25–40 years of age.

*Articulation 36: ribs and vertebrae:* Bones recovered are a left pubis, three left and three right ribs, and nine thoracic vertebrae of a 2- to 4-year-old child.

*Articulation 37: femur, tibia, fibula, and patella:* Bones recovered are one left and one right femur, one left and one right tibia, one left fibula, one left and one right innominate, one left and one right patella, three cervical vertebrae, 11 thoracic vertebrae, five lumbar vertebrae, and sacrum of a male, 40–48 years of age.

*Articulation 38: radius and ulna:* Bones recovered are a right radius and right ulna of an adult, sex undetermined, aged 30–50 years.

*Articulation 39: vertebrae, ribs, humerus, and scapula:* Bones recovered are a left humerus, left scapula, 11 thoracic vertebrae, three lumbar vertebrae, one sacrum, and nine left and three right ribs of a young adult, sex undetermined, aged 23–28 years.

*Articulation 40: radius and ulna:* Bones recovered are a right radius and right ulna of a newborn.

*Articulation 41: tibia and fibula:* Bones recovered are a left ulna and left fibula of an infant aged 6 months to 1.5 years.

*Articulation 42: radius and ulna:* Bones recovered are a left radius and left ulna of a small newborn.

*Articulation 43: tibia and fibula:* Bones recovered are a left tibia and left fibula of a 6-month-old infant.

*Articulation 44: talus, calcaneus, cuboid, and cuneiforms:* Bones recovered are a left calcaneus, left talus, left cuboid, and left first and second cuneiforms of a young adult, sex undetermined, aged 25–35 years.

*Articulation 45: cranium, mandible, and vertebrae:* Bones recovered are a cranium and both sides of the mandible of a child.

*Articulation 46: vertebrae, ribs, scapula, humerus, and clavicle:* Bones recovered are a left and right humerus, left and right scapula, right temporal, and seven vertebrae of a newborn.

*Articulation 47: tarsals and metatarsals:* Bones recovered are the right calcaneus, right talus, right cuboid, and left first, second, and fourth metatarsals of a young adult of undetermined sex.

*Articulation 48: talus and calcaneus:* Bones recovered are the left calcaneus and left talus of a small female adult, aged 20–40 years.

*Articulation 49: fibula, tibia, and femur:* Bones recovered are both femora, both tibiae, two fibulae, and two ilia of an infant, aged 6 months to 1.5 years.

*Articulation 50: radius and ulna:* Bones recovered are the left radius and left ulna of an adult, sex undetermined, aged 35–50 years.

*Articulation 51: talus and calcaneus:* Bones recovered are the right calcaneus and right talus of an adult, sex undetermined, aged 30–40 years.

*Articulation 52: scapula and humerus:* Bones recovered are the left humerus and left scapula of an adult male, 35–45 years of age.

*Articulation 53: vertebra, cranium, and mandible:* Bones recovered are a cranium, both sides of the mandible, and the first cervical vertebra of an adult female, 30–40 years of age.

*Articulation 54: tibia and fibula:* Bones recovered are the right tibia and a fibula of a 6.5-year-old child.

*Articulation 55: ilium, ischium, vertebrae, ribs, and clavicle:* Bones recovered are a left clavicle, left ilium, left ischium, three ribs, and five vertebrae of a 6-month-old infant.

*Articulation 56: talus, calcaneus, and metatarsals:* Bones recovered are the left calcaneus, left talus, one rib, and four carpals and tarsals of a 2-year-old infant.

*Articulation 57: cranial fragments, mandible, and vertebrae:* Bones recovered are both temporals, both maxillae, two mandibles, and three vertebrae of a 6-month-old infant.

*Articulation 58: child skeleton:* Bones recovered are one left and two right humeri, one right radius, one right ulna, one left femur, one left and one right clavicle, one left and two right scapulae, one right mandible, one left and one right ilium, one left ischium, two right pubic bones, 28 ribs, and 11 vertebrae of two infants, each about 6 months of age.

*Articulation 59: two femora and fibula:* Bones recovered are one left and one right femur and one fibula of a small newborn.

*Articulation 60: ribs and vertebrae:* Bones recovered are four left ribs, two right ribs, and one vertebra of an infant, newborn to 6 months of age.

*Articulation 61: metacarpals:* Bones recovered are a left first metacarpal and left fourth metacarpal of a small female, aged 19–25 years.

*Articulation 62: calcaneus and talus:* Bones recovered are a left calcaneus and a left talus of an adult, sex undetermined, aged 30–40 years.

*Articulation 63: ribs and vertebrae:* Bones recovered are five left ribs and four vertebrae of a child, aged 2–3 years.

*Articulation 64: talus, calcaneus, metatarsals, femora, innominates, sacrum, tibiae, and patella:* Bones recovered are both femora, both tibiae, both fibulae, the left patella, sacrum, left calcaneus, both tali, left cuboid, five cuneiforms, all metatarsals but the right fifth, and three phalanges of a large female adult, aged 36–43 years.

*Articulation 65: mostly complete adult:* Bones recovered are both femora; right scapula; cranium; both sides of the mandible; gladiolus; manubrium; both innominates; both patellae; one first cervical vertebra; two second cervical vertebrae; five other cervicals; 12 thoracic vertebrae; six lumbar vertebrae; sacrum; two right second metacarpals; two right third metacarpals; one proximal hand phalanx; one right talus; the left first, third, and fourth metatarsals; and seven left and six right ribs of an adult male, 50–55 years of age.

*Articulation 66: tibia and fibula:* Bones recovered are the left tibia and left fibula of a 6.5-year-old child.

*Articulation 67: radius and ulna:* Bones recovered are the left radius and left ulna of a probable female adult, aged 35–45 years.

*Articulation 68: two metatarsals:* Bones recovered are two left metatarsals of a 3- to 4-year-old child.

*Articulation 69: ribs and vertebrae:* Bones recovered are a gladiolus, manubrium, thoracic vertebra, eight left ribs, and four right ribs of an adult, sex undetermined, aged 40–45 years.

*Articulation 70: tarsals:* Bones recovered are both calcanea, one right talus, and three tarsals of a 4- to 6-year-old child.

*Articulation 71: sacrum:* Bones recovered are segments of a sacrum of a 13- to 16-year-old.

*Articulation 72: immature cranial fragments:* Bones recovered are cranial fragments of a child.

*Articulation 73: radius and ulna:* Bones recovered are the right radius and right ulna of a 6-month-old infant.

*Articulation 74: ribs, vertebrae, and manubrium:* Bones recovered are a manubrium, four thoracic vertebrae, five lumbar vertebrae, and two left ribs of an adult, sex undetermined, aged 30–40 years.

*Articulation 75: talus, calcaneus, naviculars, and cuneiforms:* Bones recovered are the left calcaneus, left talus, left navicular, and the right first and second cuneiforms of an adult, sex undetermined, aged 30–45 years.

*Articulation 76: femur, tibia, ilium, and ischium:* Bones recovered are both femora, both tibiae, both ilia, and both ischia of a 1.5- to 2.5-year-old child.

*Articulation 77: femur and innominate:* Bones recovered are the left femur and left tibia of a 15- to 20-year-old female.

*Articulation 78: scapula, humerus, and clavicle:* Bones recovered are the left humerus, left clavicle, and left scapula of an adult female, aged 35–45 years.

*Articulation 79: radius and ulna:* Bones present are the left radius and left ulna of an adult, sex undetermined, aged 30–50 years.

*Articulation 80: radius and ulna:* Bones recovered are the right radius and right ulna of an adult, sex undetermined, aged 30–50 years.

*Articulation 81: ilium, tibia, calcaneus, and metatarsals:* Bones recovered are the left tibia, left fibula, left ilium, left calcaneus, and six carpals and/or tarsals of a 1.5-year-old infant.

*Articulation 82: primary skeleton in bottom of cut:* Bones recovered are both humeri; both radii; both ulnae; the right

scapula; both maxillae; both sides of the mandible; 12 thoracic vertebrae; two lumbar vertebrae; the left first and fifth metacarpals; the right first, second, third, and fifth metacarpals; six proximal hand phalanges; one middle hand phalanx; one left rib; and five right ribs. The skeleton is that of a 30- to 35-year-old female.

*Field Number 708A, primary skeleton:* Bones recovered are both humeri, left radius, both clavicles, both scapulae, both temporals, both sides of the mandible, gladiolus, four cervical vertebrae, eight thoracic vertebrae, one left hand navicular, nine left ribs, and nine right ribs of an adult male, aged 40–50 years.

*Field Number 708B, primary skeleton:* Bones recovered are the left humerus, right radius, left ulna, cranium, both sides of the mandible, gladiolus, one second and one other cervical vertebra, eight thoracic vertebrae, seven lumbar vertebrae, one left rib, and two right ribs of an adult male, aged 50–60 years.

Of the 84 articulations initially identified in the excavation, 74 were confirmed as likely articulations in the laboratory. The remaining 10 either did not consist of the bones tentatively identified during excavation or contained side differences or other problems that precluded their being actual articulations. The excluded ones are those labeled in the excavation as “articulation” 15, 20, 24, 25, 35, 41, 57, 61, 72, and 81. Bones from the 74 true articulations were then sorted by age to reveal the number of individuals represented by each bone. This process suggested that at least nine adults were represented by the articulations. The number of mature individuals represented by each type of bone is as follows: seven by left humerus, two by right humerus, eight by left radius, five by right radius, eight by left ulna, four by right ulna, four by left femur, five by right femur, five by left tibia, four by right tibia, three by left fibula, one by right fibula, three by left clavicle, two by right clavicle, five by left scapula, nine by right scapula, four by left and right temporal, four by left and right maxilla, five by left and four by right sides of the mandible, five by gladiolus, four by manubrium, two by innominate, four by left and two by right patella, three by first cervical vertebrae, four by second cervical vertebrae, four by other cervical vertebrae, eight by thoracic vertebrae, seven by lumbar vertebrae, four by sacrum, three by metacarpals, one by hand phalanges, six by left calcaneus, two by right calcaneus, six by left talus, four by right talus, two by left cuboid, one by right cuboid, two by left navicular, two by cuneiforms, three by metatarsals, two by foot phalanges, and five individuals by ribs. Males and females of adults of all ages are represented in the articulated remains.

The same sorting procedure outlined above was followed for the immature remains. Tabulation by each type of bone of all actual articulations revealed the minimum number of individuals represented by each bone. This procedure indicated that at least seven immature individuals were represented. The following listing provides the minimum number of individuals represented by each type of bone: two by left humerus, three by right humerus, three by left radius, six by right radius, three by

left ulna, six by right ulna, six by left femur, three by right femur, five by fibulae, three by left clavicle, one by right clavicle, two by left scapula, three by right scapula, two by left temporal, three by right temporal, two by left maxilla, two by right maxilla, three by left mandible, three by right mandible, five by left ilium, three by right ilium, one by left sternum, two by left ischium, one by right ischium, one by right pubis, two by left calcaneus, one by right calcaneus, four by left talus, seven by right talus, four by ribs, one by carpals and tarsals, three by vertebrae, and one by sacrum.

A more realistic estimate of the minimum number of immature individuals may be obtained by sorting the numbers of each type of bone by age. This process is obviously complicated by the fact that exact age estimates are not possible for any of the bones, and, in some cases, the estimated age range for a particular bone is somewhat large. The following listing resulted when the most probable age was assigned to each immature bone. The "aged" bones were then sorted into specific age categories. This process suggested that at least 13 immature individuals were present. Of these, three are newborns, one is older than a newborn but less than 6 months, three are 6 months to 1 year, one is 1–2 years, one is 2–3 years, one is 3–4 years, one is 5–6 years, one is 6–7 years, and one is 13–16 years.

**TOTAL INVENTORY.**—Once the articulated remains were carefully studied, they were integrated with the other disarticulated remains from the strata cut. All human remains from the strata cut were then inventoried and studied further. This inventory indicated that at least 52 immature individuals were present, as suggested by 52 left tibiae. The number of immature individuals represented by other types of bones is as follows: 27 by left humerus, 25 by right humerus, 25 by left radius, 23 by right radius, 27 by left ulna, 22 by right ulna, 41 by left femur, 49 by right femur, 52 by left tibia, 50 by right tibia, 29 by fibulae, 19 by left clavicle, 18 by right clavicle, 22 by left scapula, 20 by right scapula, 26 by left temporal, 27 by right temporal, 13 by left maxilla, 15 by right maxilla, 41 by left mandible, 35 by right mandible, 35 by left ilium, 31 by right ilium, one by sternum, 16 by left ischium, eight by right ischium, eight by left pubis, six by right pubis, one by patella, nine by left calcaneus, five by right calcaneus, three by left talus, three by right talus, 17 by ribs, two by carpals and tarsals, and seven by vertebrae.

All of the immature bones listed above were sorted by size. Individual ages were estimated using comparative long-bone growth data (Ubelaker, 1989). The numbers of individuals of each age group and each bone were then compared to determine the minimum number of individuals present. The distribution of ages of all bone types matched those estimated for the left tibia with one exception. The longest left tibia, with a length of 201 mm, suggested an age at death likely between 6 and 7 years. One immature fibula length of 270 mm indicated an age at death likely between 10 and 12 years. Thus, the total count of immature remains recovered in this excavation represents the number indicated by the 52 left tibiae plus a 10- to 12-

year-old indicated by the fibula. This suggests the following number of immature individuals represented in this sample: 16 newborns, 14 between the ages of newborn and 6 months, 7 aged 6 months to 1 year, 10 aged 1–2 years, three aged 2–3 years, one aged 3–4 years, one aged 6–7 years, and one aged 10–12 years, for a total of 53 individuals.

Inventory of the mature remains indicates that at least 21 adults are present. The number of individuals represented by each type of bone is as follows: 21 by left humerus, 18 by right humerus, 13 by radii, 13 by left ulna, 17 by right ulna, 14 by femora, 10 by left tibia, nine by right tibia, 13 by left clavicle, 17 by right clavicle, 17 by scapulae, 10 by left side of the mandible, 12 by right side of the mandible, nine by gladiolus, 12 by manubrium, nine by left innominate, 16 by right innominate, six by patellae, 13 by first cervical, nine by second cervical, eight by other cervicals, 10 by thoracic vertebrae, 11 by lumbar vertebrae, 17 by the sacrum, two by carpal bones, 7 to 15 by various metacarpals, 12 by proximal hand phalanges, one by other hand phalanges, 12 by left calcaneus, 10 by right calcaneus, 11 by left talus, 13 by right talus, four by cuboids, seven by naviculars, one to four by cuneiforms, 6 to 12 from metatarsals, two by proximal foot phalanges, one by distal foot phalanges, and 15 by ribs. Five crania are present that are sufficiently intact to allow some measurement.

**ADULT AGE AT DEATH.**—Data on adult sex distribution and age at death are available mostly from the innominates, with some information provided by crania. Ages at death were estimated for eight males and nine females. The male ages are 32–38 (2), 35–40 (2), 38–45 (2), and 40–50 (2) years. The female estimates, all provided from the right innominates, suggest ages of 33–38, 34–39, 40–45, 45–50 (3), 55–60, and 65–70 (2) years.

The combination of the mature and immature ages at death suggests that 74 individuals are present in the sample.

Table 4 presents a life table reconstructed from this sample. The table suggests that life expectancy at birth for the population represented by this sample was only about 14 years, reflecting a very high infant mortality rate. If the individual was fortunate enough to survive the first year of life, life expectancy at age 1 increased to about 26 years. Thus, all 1-year-old individuals in this population could expect to live, on the average, to the age of 27 years. The sample registered no deaths between 15 and 29 years, with only a few individuals living to the age of 70.

**LIVING STATURE.**—The best estimates for living stature in this sample are derived from the femora. The femora not only offer measurements of length, which can be converted to estimates of stature, but also measurements of maximum femoral head diameter and other dimensions that provide indications of sex (Stewart, 1979; Bass, 1987; Ubelaker, 1989). For females, stature calculations are available for the following nine femora, with femoral head diameters ranging in size from 35 mm to 43 mm (bone length (mm) precedes estimated stature (cm)): 370, 146; 368, 145; 380, 148; 405, 155; 347, 140; 417, 158; 378,

TABLE 4.—Life table for upper-chamber strata-cut sample. (Dx=total number of individuals per age interval, dx=percentage of individuals dying in each age interval, lx=number of survivors of a theoretical cohort of 100 individuals entering each age interval, qx=probability of death in each age interval, Lx=total number of years lived during each age interval, Tx=total number of years lived after a lifetime of all individuals entering each age interval, e<sup>o</sup>x=life expectancy of all individuals entering each age interval.)

Age interval	Dx	dx	lx	qx	Lx	Tx	e <sup>o</sup> x
0-0.9	37	50.00	100.00	0.5000	75.000	1382.660	13.83
1-4.9	14	18.92	50.00	0.3784	162.160	1307.660	26.15
5-9.9	1	1.35	31.08	0.0434	152.025	1145.500	36.86
10-14.9	1	1.35	29.73	0.0454	145.275	993.475	33.42
15-19.9	0	0	28.38	0	141.900	848.200	29.89
20-24.9	0	0	28.38	0	141.900	706.300	24.89
25-29.9	0	0	28.38	0	141.900	564.400	19.89
30-34.9	1	1.35	28.38	0.0476	138.525	422.500	14.89
35-39.9	8	10.81	27.03	0.3999	108.125	283.975	10.51
40-44.9	3	4.05	16.22	0.2497	70.975	175.850	10.84
45-49.9	5	6.76	12.17	0.5555	43.950	104.875	8.62
50-54.9	1	1.35	5.41	0.2495	23.675	60.925	11.26
55-59.9	1	1.35	4.06	0.3325	16.925	37.250	9.17
60-64.9	0	0	2.71	0	13.550	20.325	7.50
65-69.9	2	2.70	2.71	0.9963	6.775	6.775	2.50

148; 379, 148; 411, 156. These estimates suggest a female mean stature of 149 cm, with a range from 140 cm to 158 cm.

Estimates of male living stature are available from three right femora. These femora have femoral head diameters of 45 mm and 49 mm. The three bone lengths (in mm) and the estimated statures (in cm) are as follows: 402, 157; 511, 182; 393, 155. These estimates suggest a male mean stature of about 165 cm, with a range from 155 cm to 182 cm. All estimates of living stature were generated using Trotter's 1970 formulae for white males and white females (Ubelaker, 1989:61).

MEASUREMENTS AND OBSERVATIONS.—All measurements and observations are presented in Tables 5 and 6. The remains

appear to be largely of European origin with at least one individual of likely African descent. The African cranium is of a male, likely 30 to 40 years of age, with rectangular-shaped orbits, a wide nasal aperture, lack of a nasal sill, moderate prognathism, wide interorbital distance, prominent cheekbones, and narrow nasal bones but no postbregmatic depression.

PATHOLOGY.—All observations on pathological conditions were recorded following the inventory of all remains from the stratigraphic cut. In most cases, the bones could not be individually identified; thus, few individual designations were made within the strata-cut sample. The categories of pathological conditions presented herein are not mutually exclusive. Trauma

TABLE 5.—Measurements of crania and mandibles, upper-chamber strata cut. (F=female, M=male.)

Measurement	Feature number							
	704(M)	708A(M)	704(F)	700(F)	700(M)	700(?)	700(?)	700(?)
Auricular height	120	—	118	110	117	—	—	—
Porion-bregma	110	—	115	105	116	—	—	—
Cranial length	180	—	162	169	185	—	—	—
Cranial breadth	141	—	144	134	146	—	—	—
Basion-bregma	123	—	127	122	129	—	—	—
Minimum frontal breadth	91	—	91	83	82	—	—	—
Upper facial height	63	—	67	65	55	—	—	—
Facial breadth	131	—	121	120	135	—	—	—
Nasal height	56	54	48	45	42	—	—	—
Nasal breadth	24	27	24	23	25	—	—	—
Orbital height	38	—	36	35	31	—	—	—
Orbital breadth	41	—	39	41	38	—	—	—
Maxillo-alveolar length	—	—	44	52	52	—	—	—
Maxillo-alveolar breadth	59	—	54	59	61	—	—	—
Palatal length	36	—	35	49	51	—	—	—
Palatal breadth	41	—	36	40	44	—	—	—
Bicondylar breadth	—	—	—	—	—	109	—	—
Bigonial breadth	—	—	—	—	—	91	—	106
Height of ascending ramus	—	—	—	—	—	58	54	—
Minimum breadth of ascending ramus	—	—	—	—	—	25	31	37
Height at mandibular symphysis	—	—	—	—	—	27	—	30

TABLE 6.—Nonmetric observations, upper-chamber strata cut. Observations on skeletal features that are not sided straddle columns. (F=female, M=male, L=left, R=right.)

Skeletal feature	Feature number															
	704(M)		708AT(M)		704T(F)		700T(F)		700(M)		700(?)		700(?)			
	L	R	L	R	L	R	L	R	L	R	L	R	L	R		
Mylöhoid bridge	-	-	-	-	-	-	-	-	-	-	A	A	-	A	A	A
Accessory mental foramen	-	-	-	-	-	-	-	-	-	-	A	A	-	A	A	A
Frontal grooves	P	P	-	-	P	P	A	A	P	P	-	-	-	-	-	-
Supraorbital foramen	A	P	N	N	P	P	A	A	N	N	-	-	-	-	-	-
Trochlear spur	A	A	A	A	P	P	A	A	A	A	-	-	-	-	-	-
Accessory optic canal	A	A	-	-	P	P	A	A	A	A	-	-	-	-	-	-
Infraorbital suture	A	A	-	-	A	A	A	A	P	P	-	-	-	-	-	-
Os japonicum trace	A	A	-	-	A	A	A	A	A	A	-	-	-	-	-	-
Wormian bones	A	A	-	-	A	A	A	A	A	A	-	-	-	-	-	-
Parietal process of temporal squama	A	A	-	-	A	A	A	A	A	A	-	-	-	-	-	-
Squamoparietal synostosis	A	A	A	A	A	A	A	A	A	A	-	-	-	-	-	-
Auditory exostoses	A	A	A	A	A	A	A	A	A	A	-	-	-	-	-	-
Pharyngeal fossa		P		A		A		P		A						
Paracondylar process	A	A	-	-	A	A	A	A	A	A	-	-	-	-	-	-
Intercondylar canal	A	A	-	-	A	A	A	A	A	A	-	-	-	-	-	-
Odonto-occipital articulation		A		-		A		A		A						
Divided hypoglossal canal	A	A	-	-	A	A	A	A	A	A	-	-	-	-	-	-
Postcondylar canal	A	P	-	-	A	A	P	P	A	P	-	-	-	-	-	-
Marginal foramen of tympanic plate	A	A	-	A	A	A	A	A	A	A	-	-	-	-	-	-
Tympanic dehiscence	P	P	-	A	A	A	P	P	A	A	-	-	-	-	-	-

can lead to subsequent infection and arthritic change. Bony ankylosis can be congenital or can be induced by trauma and arthritic change

**Fusion:** Two examples of vertebral fusion were found within the sample, two thoracics and two lumbar. One other thoracic, likely a middle thoracic between numbers six and eight, shows a collapsed centrum. In spite of the alteration of the centrum, only slight osteophytosis is present.

In addition, a lower thoracic vertebra shows marked Schmorl's nodes and macroporosity of the centrum.

**Exostoses:** Small exostoses were found on four bones. A 10 mm exostosis was found on the sternal end of a right clavicle. A small 8 mm exostosis is located on the medial surface of the olecranon fossa of a right humerus. A small 2 mm exostosis is located on the lateral side of a right calcaneus. A 7 mm exostosis was found on the lateral surface of a left calcaneus.

**Trauma:** Eight bones show evidence of trauma in this sample. A slightly remodelled fracture is located on the sternal end of a left clavicle with evidence of subsequent remodelling.

A distal left humerus shows extensive destruction and malformation. The fracture was likely sustained during childhood. No evidence of recent infection is present, but the articular surface displays extensive eburnation, suggestive of cartilage destruction.

A left patella is fractured through its lateral third. Slight reactive bone is present on the anterior surface.

Two right ribs show fractures. One healed fracture is located in the middle of a lower rib. An upper rib shows a healed compression fracture 84 mm from the sternal end.

One second metacarpal shows a healed fracture of its base.

The left ulna of the 35- to 50-year-old male of Articulation 50 displays an apparent pseudoarthrosis of the proximal end. The fracture extends through the olecranon process. The proximal end is not present.

Finally, a first cervical vertebra of an 8- to 10-year-old shows a partially healed fracture of the anterior left segment between the articular facet and the midline.

The ratio of bones with fractures (8) to total individuals in the sample (74) is 0.11.

**Infection:** Sixteen bones in this sample show evidence of infection, 10 from adults and six from subadults. The adult lesions are as follows: left femur of a female, well-remodelled periosteal bone on the popliteal surface; left femur of a female, some remodelled bone on the popliteal surface; right clavicle, slight deposit on the sternal end; right clavicle, slight deposit on the acromial end; right clavicle, bone deposit on the acromial and sternal ends; right humerus, well-remodelled periosteal deposit 48 mm in length about 77 mm from the proximal end; right rib, slight periosteal deposit on the lateral surface 71 mm from the vertebral articulation; left lower rib, slight periosteal deposit on medial and lateral surface; left and right tibia, most of shaft with well-remodelled periosteal bone.

The bones from immature individuals with periosteal lesions are three left ribs and a right rib with abnormal new bone deposits over much of the lateral surface; an infant right parietal, aged 6-9 months, with fine periosteal new bone deposited over the preexisting bone surface; and a newborn humerus with fine, porous new bone at each metaphysis. This last bone is very thick, with a distal width of 18 mm, proximal width of 11 mm, and midshaft width of only 6 mm.

The ratio of bones (16) with evidence of infection to total adults in the sample (21) is 0.76. The ratio of bones with infection to all individuals in the sample (74) is 0.22.

**Porotic Hyperostosis:** The external surface of one infant right parietal, aged 6–9 months, shows porous bone continuous with the internal bone within an area 45 mm × 45 mm near the coronal suture.

Frontal orbital areas present are 29 left and 30 right. Five left orbits and three right orbits show the porosity in the upper orbital area known as cribra orbitalia (Figure 1). Two of the left orbits with this porosity also show evidence of porosity elsewhere on the frontal bone. As listed above, one of these frontal abnormalities appears to result from infection, and one reflects porotic hyperostosis likely due to anemia (porosity continuous with internal bone). The ratio of bones with evidence of porotic hyperostosis (9) to total number of individuals in the sample (74) is 0.12.

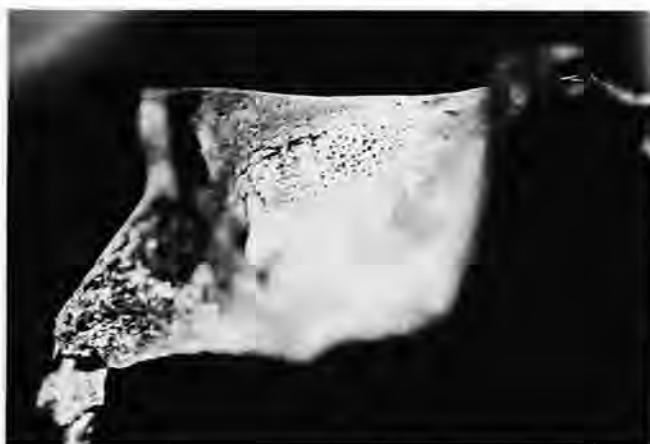


FIGURE 1.—Cribra orbitalia of right infant orbit, upper-chamber strata cut.

**Dental Disease, Deciduous Teeth:** Only 38 deciduous teeth were present from two individuals. None of the deciduous teeth had been abnormally lost antemortem. Only one carious lesion was noted, for a frequency of 2.6%. The lesion was found in the occlusal surface of a mandibular right first molar. Neither alveolar abscesses nor dental calculus were observed. Two hypoplastic tooth crowns were present on maxillary first and second molars.

**Dental Disease, Permanent Teeth:** One hundred thirty-nine permanent teeth were present. Of these, nine displayed carious lesions, for a frequency of 6.47%. The locations of these lesions are presented in Table 7. Of 365 observations on presence or absence of teeth, 40 were absent (10.96%). Of 241 observations on alveolar abscess, only three abscesses were observed (1.24%).

Dental calculus was usually present in slight deposits as follows: 28% deposits absent, 61% slight deposits, 10% medium

TABLE 7.—Distribution of carious lesions on permanent tooth surfaces, upper-chamber strata cut.

Tooth	Surface	Size of lesion (mm)
Maxillary PM <sup>1</sup>	proximal root	5
	distal root	5
Maxillary M <sup>1</sup>	distal crown	3
Mandibular I <sub>2</sub>	occlusal crown	5
Mandibular PM <sub>1</sub>	distal crown	4
Mandibular M <sub>1</sub>	occlusal crown	10
Mandibular M <sub>1</sub>	distal crown	4
	buccal root	6
Mandibular M <sub>1</sub>	distal crown	2
Mandibular M <sub>2</sub>	occlusal crown	1
Mandibular M <sub>3</sub>	occlusal crown	2

deposits, and 1% large deposits on the buccal surfaces; 31% deposits absent, 51% slight deposits, 16% medium deposits, and 2% large deposits on the lingual surfaces.

Of the 139 teeth present, only five (3.6%) show hypoplasia.

#### LOWER-CHAMBER SUPERFICIAL COLLECTION

This sample represents human remains collected from the upper surface of the deposit in the lower chamber. An effort was made to collect all loose material from the surface that would have been damaged during later excavation. This material was immediately washed and inventoried to obtain data on the content and physical characteristics of the individuals represented in the lower chamber.

The bones were well preserved. One complete left femur shows evidence of an incision likely made by the sharp edge of a shovel or similar instrument. The incision is located at the base of the head on the inferior surface and measures 33 mm in length. Coloration and soil deposits on the cut surface indicate the incision was made postmortem, but many years ago.

**TOTAL INVENTORY.**—Remains of immature individuals were confined to a left scapula of a child aged 6–7 years, a right humerus of an 11- to 13-year-old adolescent (adult size but distal epiphysis not united), and one left proximal humerus epiphysis.

Remains of at least 50 adults are present. The numbers of specific bones present are as follows: 14 left and 19 right humeri; eight left and six right radii; nine left and six right ulnae; 50 left and 37 right femora; 27 left and 35 right tibiae; four left, four right, and nine side-undetermined fibulae; two left clavicles; two left and five right scapulae; 20 left and 18 right temporals; five left and five right maxillae; five left and three right mandible halves; one gladiolus; five left and five right innominate; three thoracic vertebrae; six lumbar vertebrae; four sacra; one proximal hand phalanx; five left and nine right calcanei; one right second cuneiform; one left and two right first metatarsals; two right second and two right third metatarsals; one proximal foot phalanx; three left and 10 right ribs; 43 frontals; 45 occipitals; and various other cranial bones and other fragments.



*Sex Distribution:* Various indicators suggest that this sample is primarily composed of male individuals. Of 22 crania for which sex could be reliably estimated, 19 are male and only three are female. Of five left humeri, all are likely male (maximum head diameters of 44 mm, 46 mm, and three of 47 mm). Of nine right humeri, two with maximum head diameters of 42 mm are likely female, two of 43 mm are undetermined, and those with head diameters of 44 mm (one), 46 mm (three), and 48 mm (one) are likely male. Of the left innominates, one is female and three are male. All three right innominates are male. Of the femora, two are apparently female, with maximum head diameters of 41 mm and 42 mm, and three are male, with head diameters of 46 mm to 48 mm.

*Age Distribution:* Crania provide the most complete information on age at death in this sample. Individual ages were estimated for each cranium, when possible, using observations on the extent of cranial suture closure, dental attrition, and dental loss. In all cases, ages were estimated within a range (e.g., 30–40 years, 45–60 years). The average age within that range was then calculated for each cranium (e.g., 35 years, 52.5 years), and these estimates were used to generate summary statistics. Ages are available for only three female crania (35, 45, and 53 years). Total ranges of the estimates were from 30–60 years, with a mean of 44 years.

Twenty-five age estimates of male crania are available, ranging from 28 to 55 years. The youngest estimate is 25–30 years and the oldest is 50–60 years. These 25 estimates suggest a mean age of 38.68 years, with a standard deviation of 7.40. Only three estimates are available from crania of undetermined sex. These estimates are 30–40, 35–40, and 40–50 years. They suggest a mean age of 40 years, with a standard deviation of 5 years.

Only one estimate is available from the innominates. A left innominate of a male suggested an age at death of between 27 and 32 years.

*LIVING STATURE.*—Living stature was estimated for the tibiae and femora. All calculations utilized the formulae of Trotter for white males (Ubelaker, 1989:61). Presumably, all of the bones originated from males, but it is possible that one might have been female. These formulae suggest a standard error of 3.27 cm for estimates from the femora and 3.37 cm for estimates from the tibia. Measurements of the right femur (maximum length in mm) precede the suggested statures (in cm) and are as follows: 404, 158; 412, 160; 429, 164; 432, 164; and 435, 165. One left femur length of 460 mm suggests a living stature of 171 cm and apparently originates from a sixth individual.

Estimates from right tibiae (bone length in mm followed by estimated stature in cm) are as follows: 325, 161; 340, 164; 344, 165; 363, 170; 365, 171; 367, 171; 368, 171. Two left tibiae appear to originate from two individuals other than those listed from the right tibia. These bone lengths (in mm) and stature estimates (in cm) are 307, 156, and 322, 160.

Comparison of stature estimates from the tibiae and fibulae suggests that 10 individuals in the sample had the following living statures (in cm): 156, 160, 161, 164, 165, 165, 170, 171, 171, and 171. This suggests a mean stature of 165.4 cm with a standard deviation of 5.3 and range from 156 cm to 171 cm. Note that the formulae indicate a standard error of between 3 and 4 centimeters associated with each estimate.

*MEASUREMENTS AND OBSERVATIONS.*—Summary statistics on measurements and observations of the crania are presented in Tables 8, 9, and 10. Of the 43 mature frontals in the sample, five show metopic sutures. Four of these are from males and one originates from a frontal of undetermined sex. All of these data are consistent with a European origin of the individuals in this sample.

*PATHOLOGY.*—A wide range of pathological conditions are present in this sample. Note, however, that the superficial nature of this sample precludes meaningful interpretation of the frequency of the various conditions. Frequencies are reported

TABLE 8.—Measurements of crania, lower-chamber superficial collection.

Measurement	Female			Male		
	No.	Mean	Range	No.	Mean	Range
Maximum height	1	117	117	7	118	114–122
Auricular height	1	116	116	7	116	113–121
Porion-bregma	1	116	116	7	115	111–119
Cranial length	3	179	174–185	12	182	174–193
Cranial breadth	3	141	138–145	12	145	138–173
Basion-bregma	1	134	134	5	133	131–136
Minimum frontal breadth	3	92	91–93	15	99	89–113
Upper facial height	0	—	—	2	75	74–75
Facial breadth	0	—	—	1	133	133
Nasal height	0	—	—	2	55	54–55
Nasal breadth	0	—	—	3	26	25–26
Orbital height	1	34	34	3	36	34–39
Orbital breadth	1	40	40	3	42	41–43
Maxillo-alveolar length	0	—	—	2	54	53–54
Maxillo-alveolar breadth	0	—	—	3	59	53–66
Palatal length	0	—	—	2	44	42–46
Palatal breadth	0	—	—	2	41	40–41

TABLE 9.—Nonmetric observations of male crania, lower-chamber superficial collection.

Skeletal feature	Left			Right		
	Observations	Number present	% present	Observations	Number present	% present
Frontal grooves	17	1	6	17	0	0
Supraorbital foramina	11	1	9	12	2	17
Supraorbital notches	11	3	27	12	4	33
Trochlear spur	5	1	20	5	2	40
Accessory optic canal	3	0	0	3	0	0
Infraorbital suture	4	1	25	3	2	67
Os japonicum trace	1	0	0	2	0	0
Wormian bones	19	2	11	19	2	11
Parietal process of temporal squama	15	1	7	14	2	14
Squamoparietal synostosis	16	0	0	16	0	0
Auditory exostoses	11	0	0	11	0	0
Pharyngeal fossa	9	0	0	—	—	—
Paracondylar process	7	0	0	7	0	0
Intercondylar canal	6	0	0	6	0	0
Odonto-occipital articulation	7	0	0	—	—	—
Divided hypoglossal canal	7	0	0	7	0	0
Postcondylar canal	6	3	50	6	2	33
Marginal foramen of tympanic plate	10	0	0	9	0	0
Tympanic dehiscence	10	0	0	9	0	0
Foramen spinosum incomplete	1	1	100	—	—	—

TABLE 10.—Nonmetric observations of female crania, lower-chamber superficial collection.

Skeletal feature	Left			Right		
	Observations	Number present	% present	Observations	Number present	% present
Frontal grooves	3	0	0	3	0	0
Supraorbital foramina	3	0	0	3	0	0
Supraorbital notches	3	1	33	3	1	33
Trochlear spur	1	0	0	1	0	0
Accessory optic canal	1	0	0	1	0	0
Wormian bones	3	0	0	3	0	0
Parietal process of temporal squama	3	0	0	3	0	0
Squamoparietal synostosis	2	0	0	1	0	0
Auditory exostoses	2	0	0	2	0	0
Pharyngeal fossa	—	—	—	1	0	0
Paracondylar process	1	0	0	1	1	100
Intercondylar canal	1	0	0	1	0	0
Odonto-occipital articulation	—	—	—	1	1	100
Divided hypoglossal canal	1	0	0	1	0	0
Postcondylar canal	1	1	100	1	1	100
Marginal foramen of tympanic plate	1	0	0	—	—	—
Tympanic dehiscence	2	1	50	—	—	—
Foramen in lateral pterygoid process	1	0	0	1	0	0
Foramen spinosum incomplete	1	1	100	1	0	0
Pterygobasal bridge	1	0	0	1	0	0
Pterygospinous bridge	1	0	0	1	0	0
Clinoid bridge	1	0	0	1	0	0

herein for comparative purposes but with the caution that the bones selected for this sample are not entirely representative of the complete skeleton.

*Trauma:* Thirteen examples of trauma are present in 13 bones.

One left tibia shows a well-remodelled, healed fracture 155 mm from the proximal end.

Ossified ligaments about 25 mm in length are present on the distal lateral end of a left tibia, apparently initiated by local trauma.

A right tibia shows a healed, well-remodelled fracture of the midshaft (Figure 2).

Another right tibia shows a healed, well-remodelled fracture of the midshaft with abnormal angulation of the diaphysis (Figure 3).

A left femur displays exostoses on the linea aspera. These exostoses are approximately 24 mm in length and 6 mm in height and are located 180 mm from the distal end. Smaller exostoses are located approximately 100 mm from the distal end.

A well-remodelled, healed fracture is located on the diaphysis

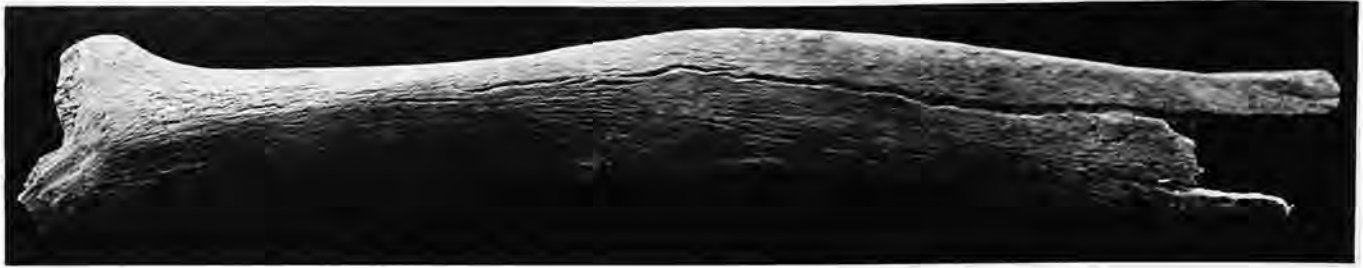

FIGURE 2.—Well-remodelled fracture of right tibia, lower-chamber superficial collection.

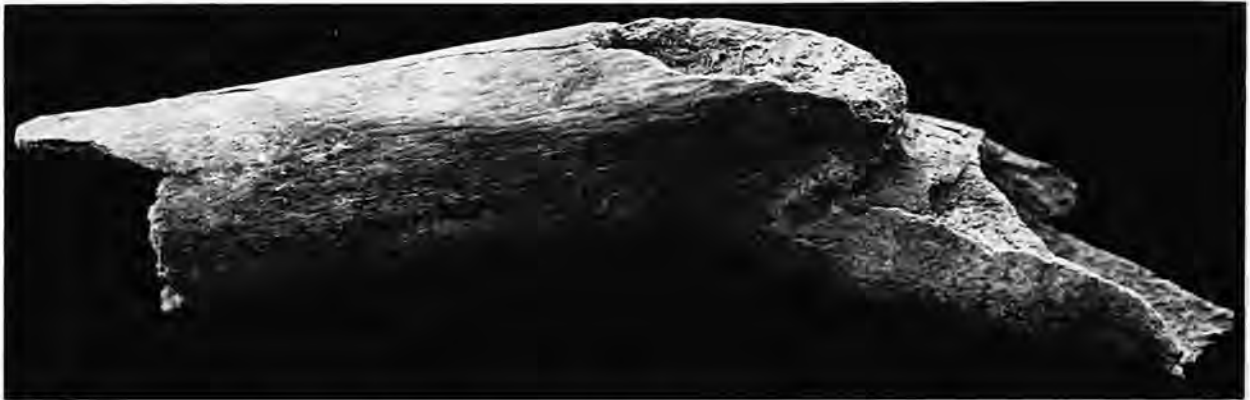


FIGURE 3.—Well-remodelled fracture of right tibia, lower-chamber superficial collection.

is of a left humerus. The fracture is located approximately 120 mm from the distal end. The humerus is missing its proximal end and measures only 180 mm in total length. Because of the fracture, the distal end is abnormally dislocated anteriorly.

One frontal displays a probable old healed depressed fracture. The fracture measures approximately 20 mm in diameter and is located in the midline above nasion. A metopic suture is diverted around the fracture and displays a complicated sutural pattern at the fracture site (Figure 4). This suggests the trauma occurred during childhood, probably at an age of 2 or 3 years.

The left parietal of a 30- to 40-year-old male shows a 96-mm fracture extending from the junction of the left coronal and squamosal sutures posteriorly across the parietal. No evidence of remodelling was noted, but the fracture shows considerable postmortem erosion. The fracture most likely represents perimortem trauma to the left temporal (bone not present). The possibility of postmortem fracture sustained many years ago, however, cannot be ruled out.

The parietals of a 40- to 50-year-old male display a slight depression on the sagittal suture in the midline. The depression is 13 mm in diameter and is located 44 mm from lambda. The lesion is well remodelled and probably represents trauma, although a developmental or infectious source cannot be ruled out.

Two small, well-remodelled depressed fractures are located on the frontal of a 30- to 40-year-old male. One depression measures about 1.16 mm  $\times$  9 mm and is located on the left superior aspect of the frontal 16 mm from the coronal suture and 15 mm from the midline. The second depression measures approximately 12 mm  $\times$  8 mm and is located 32 mm from the coronal suture and 39 mm from the midline.

One distal right humerus fragment measuring about 90 mm in length shows a fracture about 50 mm from the distal end. The fracture is well remodelled with extensive periosteal alteration, likely representing associated infection. The joint surface of the distal end also shows extensive arthritic change.

Another right humerus has a likely healed fracture of the midshaft about 140 mm from the proximal end. The length of the humerus fragment is about 250 mm.

The ratio of adult bones with fractures (13) to total adults in the sample (50) is 0.26.

*Infection:* Twenty-two bones from this sample show evidence of infection. This evidence consists of varying expressions of abnormal periosteal new bone formation, remodelling of new bone, and/or associated areas of bony destruction. Some examples of periosteal new bone formation may result from trauma, although at the time of examination all examples listed herein appeared to represent infection.

A slight periosteal deposit is present on the proximal and distal (medial surface) ends of a right fibula.

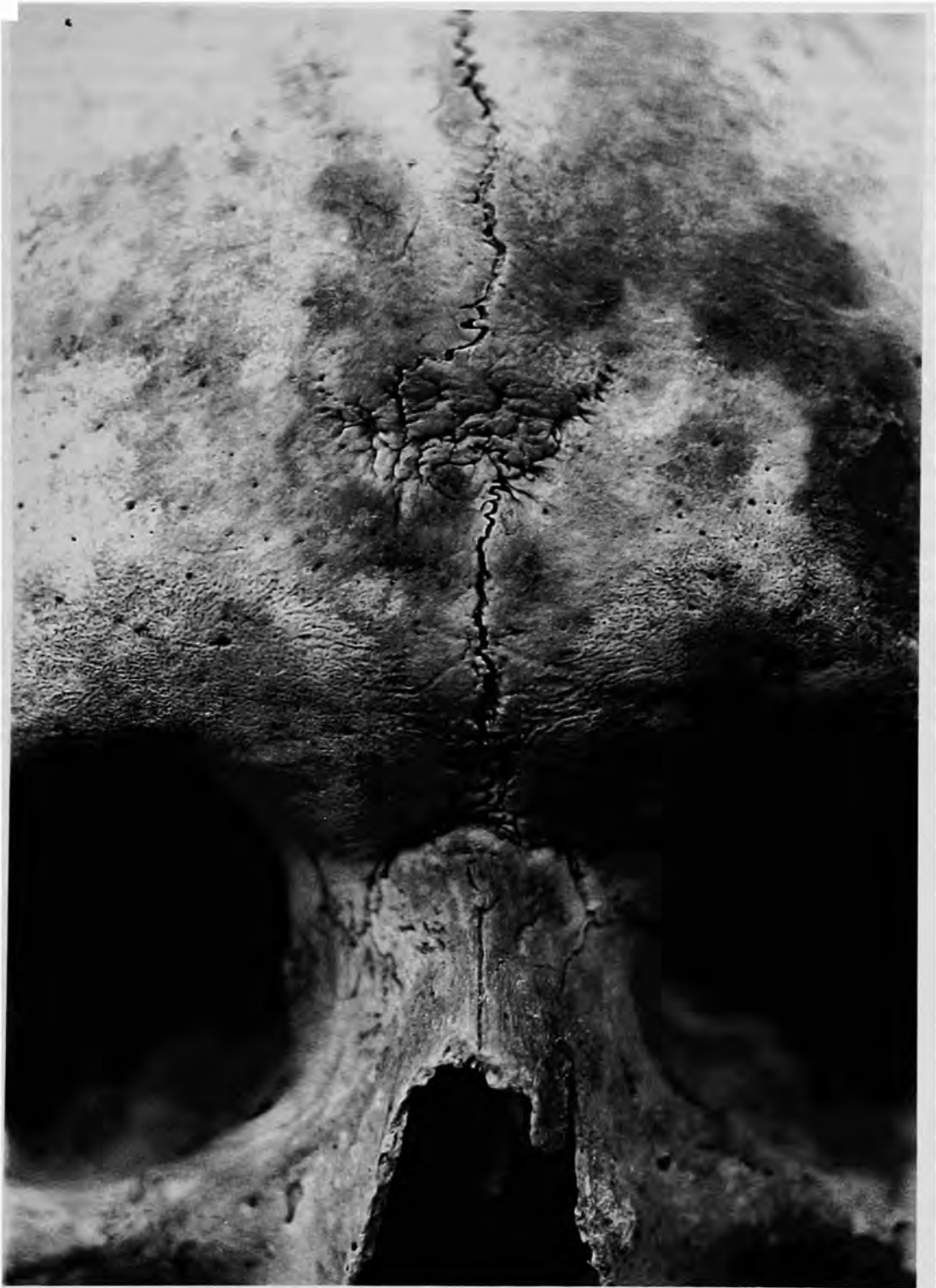

FIGURE 4.—Depressed fracture associated with metopic suture from lower-chamber superficial collection.

A left ulna shows well-remodelled reactive bone over most of the diaphyses, especially the proximal end.

A right ulna displays fine pinpoint new periosteal bone on the proximal end of the lateral surface 78 mm from the proxi-

mal end. This lesion shows no remodelling, indicating it was active at the time of death.

Another right ulna shows well-remodelled periosteal new bone formation over much of the lateral diaphysis. The external surface is rough and irregular.

A left tibia shows a minimal but detectable well-remodelled lesion about 28 mm in length on the proximal lateral surface.

A small area of active periosteal new bone formation is present on the distal and proximal ends of a left tibia. No evidence of remodelling was present.

The anterior surface of a proximal tibia shows evidence of mild periostitis in an area measuring about 14 mm × 23 mm. No evidence of remodelling is present.

A right tibia shows a well-remodelled periosteal lesion 36 mm in length on the proximal lateral surface.

A left femur displays a mild periosteal reactive lesion on the anterior midshaft.

Another left femur shows a well-remodeled lesion on the medial distal diaphysis, 94 mm in length. Approximately two-thirds of the anterior surface is abnormally thickened.

A tibia shows a lesion, active at the time of death, approximately 11 mm × 11 mm in size on the medial-distal surface.

A left femur is noticeably thickened with well-remodelled periosteal apposition. The entire diaphysis displays an irregular surface.

Another left femur displays evidence of extensive infection. Deposits of fine bone and recognizable cloacae are present at the midshaft. The fragment length is 302 mm. All proximal surfaces are involved. The bony reaction is most extensive at the proximal end.

A well-remodelled periosteal lesion is located on a right femoral midshaft just above the nutrient foramen medial to the *linea aspera*. The affected area shows a slight thickening and measures about 28 mm in length.

A right femur shows a well-remodelled periosteal lesion approximately 81 mm in length.

A left distal humerus fragment 95 mm in length is abnormally thick, with well-remodelled periosteal lesions over much of the surface.

A fragment from the frontal of a 40- to 50-year-old male shows abnormal thickening and extensive well-remodelled lesions in the bregma area. The bone is approximately 8 mm thick in this area, in contrast to only about 4 mm on the parietals. The bone is very weathered, thus postmortem effects may be present as well.

The frontal and parietals of a 40- to 50-year-old male are very rough and abnormally thickened (Figure 5). The affected areas are well remodelled. A small, smooth-walled, crater-like depression 8 mm in diameter is present on the left parietal. An



FIGURE 5.—Remodelled lesions on frontal and parietals of male from lower-chamber superficial collection.

abnormal foramen about 4 mm in diameter connects the affected area of the frontal to the frontal sinus. Fine new bone has been deposited on the inferior border of the foramen.

The frontal of a 40- to 50-year-old male shows a very large, well-remodelled, crater-like lesion. The lesion is very well remodelled but is extremely rough and irregular. The affected area covers much of the superior frontal area and extends to the right supraorbital margin. Interconnecting deep, crater-like lesions are present.

A right humerus distal diaphysis fragment 200 mm long shows extensive, well-remodelled periostitis over most of its surface.

The ratio of bones (22) with evidence of periosteal infection to adults (50) in the sample is 0.44.

*Tumors:* Evidence of tumors is confined to several examples of primary benign tumors.

The internal surface of a frontal of a 40- to 50-year-old male shows a round, sclerotic, raised lesion (Figure 6) measuring about 13 mm  $\times$  17 mm. The center of this lesion is not raised. The lesion is located about 30 mm superior to the or-

bits. A small button osteoma is located on the left frontal. It measures about 5 mm  $\times$  6 mm.

A small button osteoma is located on the left parietal of a male. The osteoma measures about 4 mm in diameter.

The left frontal area of a 30- to 40-year-old male shows a small button osteoma approximately 45 mm from the coronal suture and 22 mm from the midline.

*Developmental Anomalies:* The occipital of a male shows a slight depression in the superior occipital area just right of the midline. The depression measures about 8 mm  $\times$  15 mm and likely represents a developmental anomaly.

*Abnormal Curvature of Long Bones:* Two bones in this sample show abnormal bowing of the limbs that appear to represent problems during the growth period. One fibula shows marked lateral bowing. When the bone is resting on its medial surface against a flat table, the distance from the table surface to the lowest point of the midpoint of the shaft is 22 mm.

A left ulna shows abnormal posterior bowing. Evidence of periostitis also is present on the bone.

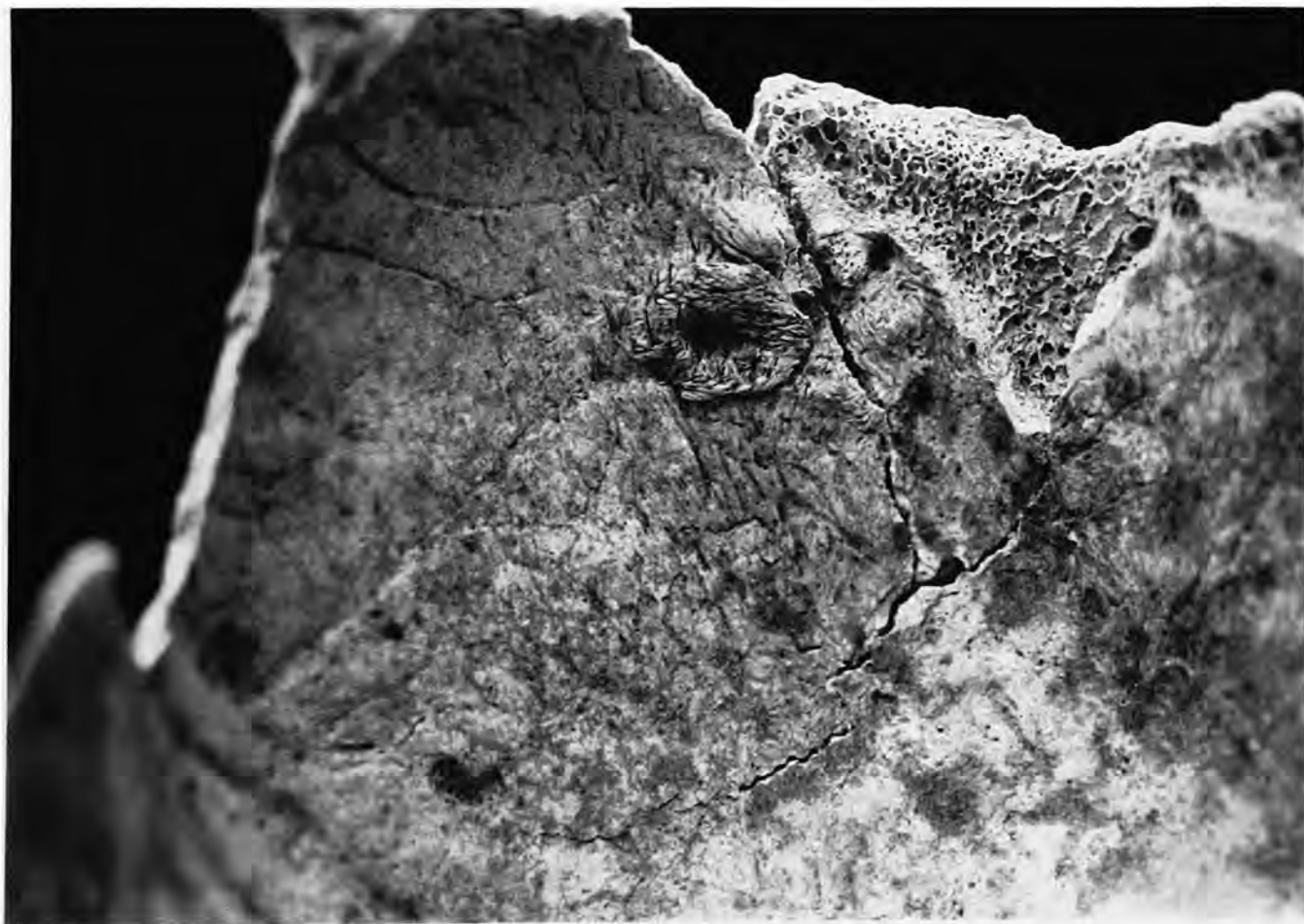


FIGURE 6.—Lesion on endocranial surface of a frontal, lower-chamber superficial collection.

*Dental Disease:* Summary statistics on dental disease are available in Table 11. This table reveals that only 28 permanent teeth were recovered (no deciduous teeth). The small number of teeth present reflects the fact that many of the maxillae and mandibles recovered had lost teeth postmortem. Such teeth lost within the ossuary would tend to fall within the bone matrix and not be recovered in a superficial collection such as this.

Of 114 observations on the presence or absence of teeth in the maxillae and mandibles, 52 had been lost antemortem (46%).

Only 19 permanent teeth were sufficiently intact to allow observations for carious lesions. Six lesions were noted, for a frequency of 32%. These six lesions were the following: Cranium 1, a 2 mm lesion in the occlusal surface of a maxillary

right first molar; and Cranium 45 (all maxillary), a 2 mm lesion in the mesial surface of a right lateral incisor, a 4 mm lesion in the occlusal surface of a right second molar, a 3 mm lesion in the mesial surface of a left lateral incisor, a 3 mm lesion in the occlusal surface of the left second molar, and a 3 mm lesion in the occlusal surface of the left third molar. Lesions on the left maxillary teeth have restorations. The restoration on the lateral incisor appears to be of porcelain, whereas that on the second molar appears to be a silver amalgam.

Of 107 observations on alveolar abscesses, only four abscesses (Figure 7) were found (3.7%).

Dental calculus was minimally present and was evenly distributed between the buccal and lingual surfaces.

No examples of hypoplasia were located.

TABLE 11.—Dental disease in lower-chamber superficial collection. (Calculus deposits: 0=none, S=slight, M=medium, L=large.)

Tooth		Absent antemortem		Carious		Alveolar abscess		Calculus										
		Present	Observations	Absent	Observations	Carious	Observations	Abscessed	Buccal				Lingual					
									0	S	M	L	0	S	M	L		
Right maxillary	I <sup>1</sup>	0	5	1	0	0	5	2	0	0	0	0	0	0	0	0	0	0
	I <sup>2</sup>	2	6	1	1	1	5	1	2	0	0	0	0	2	0	0	0	0
	C	2	4	0	1	0	5	0	1	1	0	0	0	1	2	0	0	0
	PM <sup>1</sup>	3	4	1	1	0	4	0	2	1	0	0	0	2	1	0	0	0
	PM <sup>2</sup>	2	4	1	1	0	4	0	1	1	0	0	0	0	2	0	0	0
	M <sup>1</sup>	1	4	2	1	1	4	1	0	0	1	0	0	1	0	0	0	0
	M <sup>2</sup>	4	5	1	3	1	5	0	1	3	0	0	0	2	2	0	0	0
Left maxillary	M <sup>3</sup>	1	3	1	0	0	4	0	0	1	0	0	0	1	0	0	0	0
	I <sup>1</sup>	0	4	0	0	0	3	0	0	0	0	0	0	0	0	0	0	0
	I <sup>2</sup>	1	4	0	1	1	3	0	1	0	0	0	0	1	0	0	0	0
	C	2	3	0	1	0	2	0	1	1	0	0	0	1	1	0	0	0
	PM <sup>1</sup>	2	3	1	1	0	2	0	1	1	0	0	0	1	1	0	0	0
	PM <sup>2</sup>	2	3	0	1	0	2	0	0	1	0	0	0	1	1	0	0	0
	M <sup>1</sup>	1	2	1	1	0	2	0	0	1	0	0	0	1	0	0	0	0
Right mandibular	M <sup>2</sup>	1	2	0	2	1	1	0	1	1	0	0	0	0	1	0	0	0
	M <sup>3</sup>	1	2	1	1	1	0	0	0	0	0	0	0	0	1	0	0	0
	I <sub>1</sub>	0	4	3	0	0	4	0	0	0	0	0	0	0	0	0	0	0
	I <sub>2</sub>	0	4	3	0	0	4	0	0	0	0	0	0	0	0	0	0	0
	C	0	3	2	0	0	3	0	0	0	0	0	0	0	0	0	0	0
	PM <sub>1</sub>	0	2	1	0	0	2	0	0	0	0	0	0	0	0	0	0	0
	PM <sub>2</sub>	0	2	1	0	0	2	0	0	0	0	0	0	0	0	0	0	0
Left mandibular	M <sub>1</sub>	0	2	2	0	0	2	0	0	0	0	0	0	0	0	0	0	0
	M <sub>2</sub>	1	2	1	1	0	2	0	0	0	0	0	0	0	0	0	0	0
	M <sub>3</sub>	0	2	1	0	0	2	0	1	0	0	0	0	1	0	0	0	0
	I <sub>1</sub>	0	4	3	0	0	4	0	0	0	0	0	0	0	0	0	0	0
	I <sub>2</sub>	0	4	2	0	0	4	0	0	0	0	0	0	0	0	0	0	0
	C	0	4	3	0	0	4	0	0	0	0	0	0	0	0	0	0	0
	PM <sub>1</sub>	0	4	3	0	0	4	0	0	0	0	0	0	0	0	0	0	0
Total	PM <sub>2</sub>	0	4	3	0	0	4	0	0	0	0	0	0	0	0	0	0	0
	M <sub>1</sub>	0	5	5	0	0	5	0	0	0	0	0	0	0	0	0	0	0
	M <sub>2</sub>	1	5	4	1	0	5	0	1	0	0	0	0	0	1	0	0	0
	M <sub>3</sub>	1	5	4	1	0	5	0	0	1	0	0	0	0	1	0	0	0
	Total	28	114	52	19	6	107	4	13	13	1	0	15	14	0	0	0	0

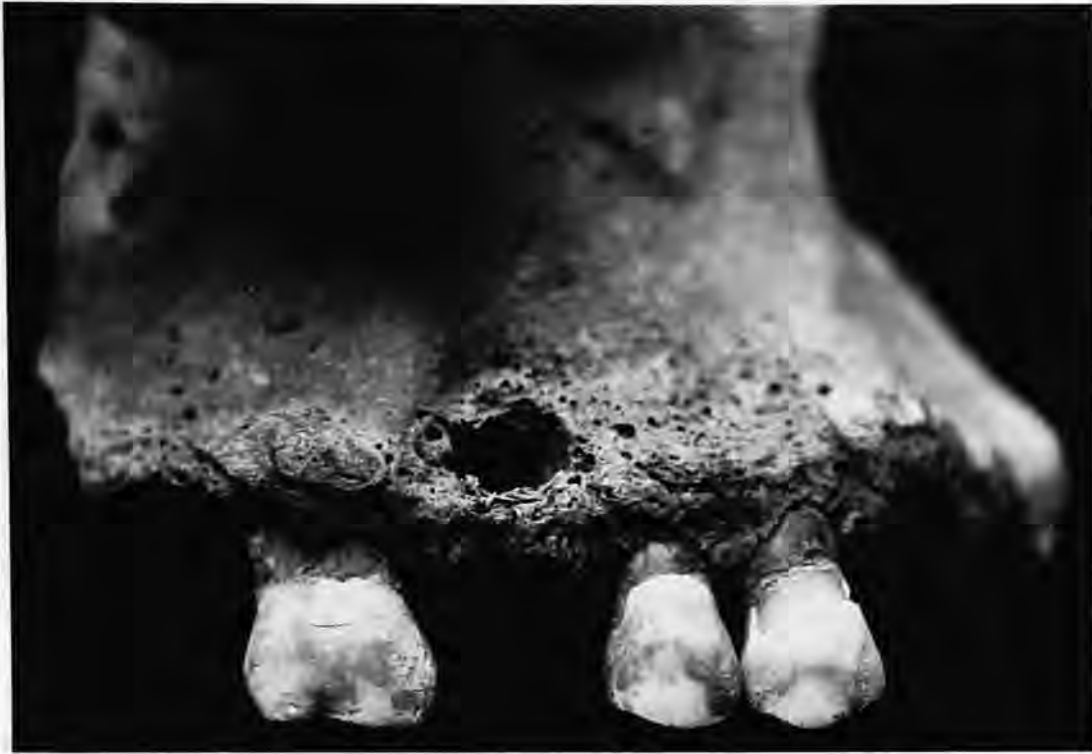

FIGURE 7.—Alveolar abscess in a right maxilla, lower-chamber superficial collection.

#### LOWER-CHAMBER STRATA CUT

Human remains from the strata cut within the lower chamber were poorly preserved. No articulations were noted during excavation. Two distal left femoral articular surfaces displayed postmortem (not recent) cut marks. One incision is 8 mm long and is located on the lateral superior border. The other incision is approximately 10 mm long and is located on the medial superior surface. Both incisions appear to have been made by a knife-like instrument. The extent of coloration of the cut surfaces and the presence of fungus and debris on the cut surfaces suggest that the incisions were made many years ago, perhaps at the time the remains were transferred to the ossuary. The lack of remodelling on the incised surfaces and the locations of the incisions suggest that they likely reflect postmortem defleshing of the remains at the time of transfer to the ossuary.

**TOTAL INVENTORY.**—At least 25 immature individuals are represented by left femora. The total numbers of other immature bones are as follows: 10 left and nine right humeri, four left and two right radii, six left and three right ulnae, 24 right femora, 13 left and 19 right tibiae, 15 fibulae, six left and five right frontals, two left and one right clavicle, one left and six right scapulae, one left and one right temporal, five mandibles, six left and five right ilia, one left ischium, one left pubis, two individuals represented by ribs, and one by vertebrae.

Comparison of the sizes of the individual bones indicates that at least 29 immature individuals are likely present. Sorting of the femora by size suggests that the following individuals are present: five newborns (71–90 mm); nine aged 6 months to 1.5 years (110–140 mm); six 1.5- to 2.5-year-old individuals (145–165 mm); four 2.5- to 3.5-year-old individuals (180–192 mm); one 4.5- to 5.5-year-old (225–230 mm); two 5.5- to 6.5-year-old individuals (250–260 mm); one 6.5- to 7.5-year-old (350 mm); and one 7.5- to 8.5-year-old (360 mm). All ages estimated from the lengths of other immature long bones and from the calcification of teeth present fall within those listed above.

At least 17 adults are represented by mature bones within the sample. The number of individuals represented by each type of bone is as follows: 12 left humeri, 13 right humeri, four left radii, seven right radii, five left ulnae, eight right ulnae, 16 left femora, 17 right femora, 12 left tibiae, 14 right tibiae, three left fibulae, three right fibulae, four left and three right clavicles, one left and three right scapulae, two left and one right temporals, four mandibles, two left and one right innominates, and one first and one second cervical vertebrae. Other bones include two other cervical vertebrae, 17 thoracic vertebrae, six lumbar vertebrae, one sacrum, eight metacarpals (representing at least two individuals), and two hand phalanges and 19 foot bones (representing at least four individuals).



The above data suggest that at least 46 individuals are represented in the sample, 29 subadults and 17 adults.

*Sex Distribution:* The sex distribution of the adults in the sample is difficult to determine because of the incomplete representation of the individuals. The sizes of the left femora indicate that eight females and six males are present. The right femora indicate that five females and seven males are present. Collectively, the femora suggest that males and females are evenly represented in the ossuary. Of the 15 adults for whom sex can be estimated reliably, eight are female and seven are male.

**ADULT AGE AT DEATH.**—Reliable estimates of age at death for adults in the sample are difficult because relatively few crania and innominates are present. Morphology of two innominates (male and female) present both suggest ages at death of 50–60 years. Three male crania indicate ages at death of 20–30 years, 35–45 years, and 50–60 years. Microscopic aging of femoral cortical bone was not attempted because of the poor preservation of the remains and the presence of extensive fungal growth that likely would preclude recognition of the relevant microscopic structures.

Because age at death can be estimated for so few adults, life table construction was not attempted. The relatively high percentage of immature remains to those of adults (29 compared with 17) indicates a relatively high subadult mortality and low life expectancy at birth, assuming adequate representation of the sample.

**LIVING STATURE.**—Estimates of living stature are available for only six adults: five females and one male. The statures were all calculated from femoral lengths using the formulae of Trotter (Ubelaker, 1989:61). The following femoral lengths (first number, in mm) and calculated statures (second number, in cm) are available for females: 383, 149; 388, 150; 410, 156; 415, 157; 425, 160. The single male estimate is femoral length 440 mm, stature 165 cm. These data suggest a female stature range from 149 cm to 160 cm with a mean of 154 cm (standard deviation 4.72). The only male stature estimate is 165 cm.

**MEASUREMENTS AND OBSERVATIONS.**—Only one cranium was complete enough to allow measurements and observations. For this male individual, minimum frontal breadth was 94 mm, and orbital breadth was 44 mm.

Observations on nonmetric cranial traits are as follows (observations from the left side precede those from the right side of the cranium; A=absent, P=present): frontal grooves, PP; supraorbital foramina, PP; trochlear spur, AA; accessory optic canal, AA; parietal process of temporal squama, AA; squamo-parietal synostosis, AA; auditory exostoses, AA; marginal foramen of tympanic plate, AA; and tympanic dehiscence, AA.

**PATHOLOGY.**—Evidence of pathology in this sample is confined to fractures (trauma), periosteal lesions (likely infection), unusual bowing of the limbs (likely developmental due to vitamin deficiency), porotic hyperostosis, and dental disease.

*Trauma:* Examples of trauma in this sample are limited to two bone fractures. One right ulna shows a fracture of the infe-

rior aspect of the olecranon process. The fracture is well remodelled, indicating the trauma occurred many years before death.

A left humerus displays a well-remodelled fracture of the distal end. The fractured area is very distorted with the medial half displaced superiorly.

The two fractures suggest a ratio of fractured bones (2) to adults (17) in the sample of 0.12.

*Infection:* Likely examples of infection are found on five bones: a right humerus, femoral midshaft of undetermined side, right tibia, left tibia, and left fibula. The right humerus diaphysis is abnormally thick and displays the irregular surface indicative of well-remodelled periostitis.

The femur is extremely thick and "club-like." The surface is very irregular and is suggestive of well-remodeled, massive infection of the upper leg.

The right tibia consists of a distal fragment approximately 260 mm in length showing extensive, well-remodelled thickening of the entire fragment. The surface shows the irregular thickening indicative of extensive periostitis.

The same pattern of extensive, well-remodelled periostitis is apparent on a left tibia and left fibula. Both bones show evidence of extensive remodelling and are fused.

The five examples suggest a ratio of bones showing evidence of infection (5) to adults (17) in the sample of 0.29.

*Porotic Hyperostosis:* No evidence of porotic hyperostosis was noted among the adult sample. Two examples of cribra orbitalia were found in the immature sample. Of six left and five right frontals, one left and one right frontal orbit displayed the fine porosity of cribra orbitalia in the superior orbit area. The bones appear to have originated from one individual, an infant. The two bones suggest a ratio of bones with porotic hyperostosis to total individuals in the sample (46) of 0.04.

*Bowing of the Limbs:* Two bones in the sample show evidence of abnormal bowing of the limbs. An adult right fibula of undetermined sex shows abnormal medial bowing. When the bone is resting on a flat table surface with the bowed medial surface of the fibula located at the highest point above the surface, the maximum distance from the table surface to the bone at the maximum point of bowing is 22 mm.

An immature fibula with an estimated maximum length of 220 mm (age of individual about 7 years) also displays marked abnormal curvature.

*Dental Disease, Deciduous Teeth:* Only 14 mandibular teeth are present. These consist of one left and one right canine, three left and three right first molars, and three left and three right second molars. Of 14 observations on the presence or absence of teeth, none were lost antemortem.

Of 14 observations on carious lesions, only one was present. One right first molar displayed a lesion 5 mm in diameter on the crown.

Of 14 observations on teeth with associated alveolar abscesses, no abscesses were noted.

All of the teeth present displayed slight dental calculus on both the buccal and lingual surfaces.

*Dental Disease, Permanent Teeth:* No permanent teeth were recovered from this sample. Of five mandibles recovered, four were completely edentulous. The fifth mandible showed antemortem loss of the molars and second premolars, but the anterior teeth had been lost postmortem. Thus, of 72 observations on the presence or absence of teeth, 64 had been lost antemortem, a rate of 88.9%. Of 72 observations on teeth with associated alveolar abscess, no abscesses were noted.

#### SIDE-CHAMBER BOXES

Because many of the boxes in the side chamber were too large and/or fragile to be removed to the laboratory for analysis, the skeletal contents were removed and processed in the normal manner. Although 12 boxes were identified, human remains were found and removed from only 11. No human remains were identified from Box 6. The following discussion first describes the skeletal content of each box and then groups the data from all boxes into a single sample.

**BOX 1.**—This box contains the mostly complete skeleton of an adult male between the ages of 33 and 38 years. Most major bones of the skeleton are present. Two right ribs and many small bones of the hands and feet are missing. The hyoid as well as ossified thyroid cartilage are present. Only four maxillary teeth are present: the first premolars, the right third molar, and the left second molar. Absent antemortem were the maxillary first molars and the right second molar. A metal restoration 3 mm in diameter is located in the occlusal surface of the right maxillary third molar. No alveolar abscesses are present.

The individual has a very European-appearing face with a metopic suture. A small depressed fracture is located in the midfrontal area about 12 mm right of the midline.

The combined lengths of the femur and tibia are 850 mm and indicate a living stature of about 174 cm, using the formulae of Trotter for white males (Ubelaker, 1989:61).

**BOX 2.**—This box contains the mostly complete skeleton of one adult male, aged 38–43 years. Bones missing are the left patella, several hand bones, and many of the small bones of the feet. Five extra rib fragments are present. The hyoid and ossified cricoid also are present. All maxillary teeth are present except for the central incisors. Mandibular teeth present are the right second premolar, right second molar, left central incisor, and left molars. All other teeth were lost postmortem except for the mandibular right first molar, absent antemortem. Five teeth show carious lesions, all located in the occlusal surface of the crown and varying in size from 2 mm to 3 mm. The teeth affected are the maxillary right first molar, maxillary left first premolar, mandibular right second molar, and mandibular left first and second molars. A metal restoration is present in the mandibular left first molar, but most of the crown has been destroyed by caries. No alveolar abscesses are present.

Femur lengths of 425 mm suggest a living stature of about 163 cm, using the formula of Trotter for white males (Ubelaker, 1989:61).

Features of the face strongly indicate a European origin. The incisor teeth are not shovel-shaped. Short, brown, straight hair is present on the mastoid processes. No pathological conditions are present on the skeleton.

**BOX 3.**—This box contains the incomplete skeletal remains of multiple individuals. At least three immature individuals are represented by the right portion of the mandible. Immature bones present are the following: one left ulna, one left and two right femora, one left tibia, two fibulae, one left and one right maxilla, two left and three right mandibles, one right ilium, one right rib, one vertebra, one left parietal, one frontal, and the right orbit area from a second frontal.

Adult bones present consist of three left and three right humeri; one right radius; one left and one right ulna; three left, two right, and two side-undetermined femora; four left and three right tibiae; two left and one side-undetermined fibula; one left and two right scapulae; four left and four right temporals; four left and three right maxillae; three left and one right mandible; one manubrium; three left and two right innominate; one cervical vertebra; four thoracic vertebrae; six lumbar vertebrae; two sacra, one distal hand phalanx; one left and one right calcaneus; two left and one right talus; and five ribs.

One female left femur displays two parallel cut marks on the lateral-anterior side of the head (Figure 8). The incisions are 10 mm and 15 mm long, respectively, and are located about 3 mm apart. The incisions were made with a knife-like fine blade and are not of recent origin. The incisions show no evidence of remodelling, thus they are of perimortem or postmortem origin. The location of the incisions suggests they result from attempts to disarticulate or to remove flesh from the bones, rather than a homicidal type of stabbing.

Lengths of the long bones and the extent of dental maturation for the three immature individuals suggest ages at death of about 3, 5, and 7 years of age.

For the adult individuals, pubic symphysis morphology, the extent of dental attrition and cranial suture closure, and other observations suggest that one male, aged 37–45 years, is present as well as three females, aged 22–37 years, 40–45 years, and 45–60 years.

Maximum lengths of the femora and tibiae suggest a living stature of 172 cm for the male and living statures of 155 cm, 159 cm, and 164 cm for the three females.

Measurements and observations on the facial bones and teeth of these individuals suggest a European origin.

Gross pathology on these remains is confined to slight cribriform orbitalia on both orbits of the youngest child.

Six deciduous teeth are present: the four maxillary molars and two right mandibular molars. Of 22 observations on the presence or absence of teeth, none were absent antemortem.

Of the six deciduous teeth present, all are carious. The crowns on all of the teeth present are mostly destroyed. One of

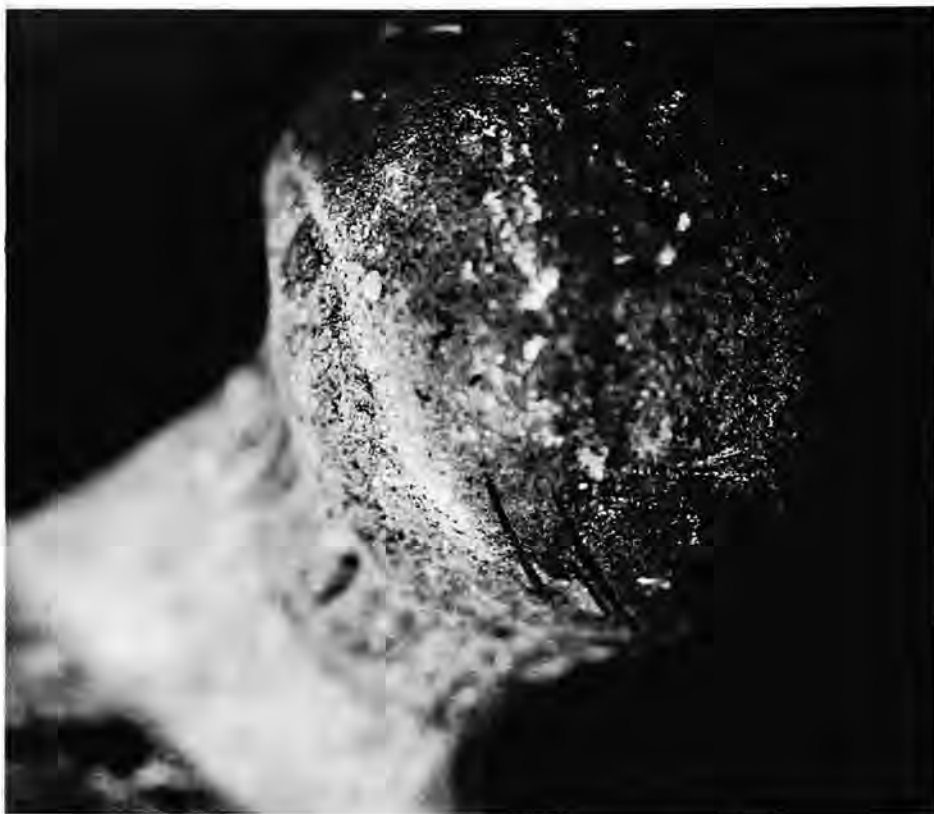

FIGURE 8.—Cut marks on female left femur, Box 3.

the six teeth (maxillary left second molar) also has an associated alveolar abscess.

All of the deciduous teeth show slight calculus deposits on both the buccal and lingual surfaces.

Fourteen permanent teeth are present. Of 72 observations on the presence or absence of teeth, 25 were absent antemortem.

Three of the 14 permanent teeth present are carious. The distal half of the crown of a maxillary right second molar is destroyed. A 5 mm lesion is located on the mesial surface of a maxillary left third molar. The crown is destroyed on a maxillary left first molar.

Of 57 observations on alveolar abscesses, only four are present, all associated with maxillary teeth: right first, second, and third molars, and a left first molar.

Dental calculus was minimally expressed within this sample. Observations were five deposits absent, five slight deposits, and two medium deposits on the buccal surfaces and 12 slight deposits on the lingual surfaces.

No examples of hypoplasia were noted.

BOX 4.—This box contains the incomplete remains of multiple individuals. Immature remains consist of one left ilium, two ribs, and three vertebrae. The size of the ilium suggests it originates from a 6-year-old child.

Most of the mature remains originate from an adult female, aged 35–45 years. At least three adults are present, however, two females and one male. Specific bones present are the fol-

lowing: one left and one right humerus, one left and one right radius, one left and one right ulna, one left and one right femur, one left and one right tibia, one left and one right fibula, one left clavicle, one left scapula, one left and one right maxilla, one gladiolus and manubrium of the sternum, one left and one right innominate, one left and one right patella, two cervical vertebrae, two thoracic vertebrae, one sacrum, one left first metacarpal, one middle hand phalanx, one right calcaneus, one right talus, one right first cuneiform, one right first and one right second metatarsal, two foot phalanges, and five left and five right ribs. Frontal bones from three individuals, two females and one male, also are present.

Maximum length of the right fibula of the 35- to 45-year-old female of 319 mm suggests a living stature of about 153 cm.

In addition to the 35- to 45-year-old female (most of the remains), an incomplete cranium of a 60- to 70-year-old female also is present.

A right femur displays a series of horizontal incisions made with a blade-type instrument. Five incisions are located between the greater trochanter and the head. The lesions lack evidence of remodelling and thus were inflicted perimortem or postmortem. The presence of dark staining and debris within the incisions indicates they are not of recent origin. The location of the incisions indicates they likely were made postmortem in the process of disarticulating or defleshing the remains.

A bony exostosis is present on the anterior surface of a tibia approximately 52 mm from the distal articular surface. The exostosis is 16 mm long and 5 mm wide.

Eight permanent teeth are present, all maxillary. Although the deciduous left canine is present, the occlusal tip of the unerupted permanent left canine is visible near the roots of the permanent first premolar.

Of 16 observations on the presence or absence of teeth, two had been lost antemortem, the maxillary first molars. None of the eight teeth are carious.

Observations of dental calculus deposits are one absent and seven slight on both the buccal and lingual surfaces.

**BOX 5.**—This box contains the incomplete remains of multiple individuals. Immature bones present are as follows: four left and four right humeri, two left and one right radii, two left and one right ulna, three left and five right femora, three left and five right fibulae, one left clavicle, two right scapulae, one left and five right temporals, one left and two right maxillae, two mandibles, two left and three right ilia, one left ischium, one left and one right pubis, two ribs, two carpals and tarsals, eight vertebrae, and various other cranial fragments.

Comparison of the sizes of the bones present as well as the stage of dental development suggests that at least seven immature individuals are present. Their ages at death were newborn, 6 months, 1.5 years, 2 years, 3 years, 6 years, and 7.5 years.

Mature remains present consist of one left and one right femur and one left and one right tibia. The bones are small and thus likely originate from a female. The estimated length of the right tibia, about 320 mm, suggests a living stature of about 154 cm.

No evidence of disease was noted, and no fully erupted teeth are present.

**BOX 7.**—This box also contains the incomplete remains of multiple individuals. Immature remains are limited to a left humerus, left ischium, two ribs, and a femoral distal epiphysis. The size of the humerus indicates it likely originates from a 1.5-year-old infant. The femoral epiphysis likely originates from a 12- to 14-year-old.

The following bones of adults are present: one right humerus, one left ulna, two left and four right femora, one left and one right tibia, one right fibula, one right temporal, one left and one right maxilla, two mandibles, one first cervical vertebra, one right second metacarpal, one right fourth metatarsal, and one cranium missing most of the left side.

The cranium appears to originate from a female between the ages of 35 and 40 years. One femur appears to represent a female with a living stature of about 171 cm.

A well-remodelled healed fracture of the right humerus is located approximately 90 mm from the proximal end. Alignment of the proximal and distal segments is abnormal, with the medial aspect of the distal segment rotated anteriorly.

Of 48 observations on the presence or absence of teeth, seven were lost antemortem. Of the 27 teeth present, one is carious and one shows hypoplasia. The carious lesion is 3 mm in diameter and is located on the occlusal surface of the mandibular

right second molar. The hypoplastic defect is located on the mid-crown area of the mandibular left canine.

Observations on dental calculus were 26 slight deposits on the buccal surfaces and 23 slight deposits and 3 medium deposits on the lingual surfaces.

**BOX 8.**—This box contains the relatively complete skeleton of an adult male. Bones missing are confined to the left patella; one thoracic vertebra; all of the carpal bones; and several metacarpals, phalanges, ribs, and bones of the feet. The extent of metamorphosis of the symphyseal face of the right innominate and other skeletal indicators suggest an age at death of between 36 and 40 years. Maximum lengths of the fibulae, about 370 cm, suggest a living stature of about 171 cm.

The complete cranium reveals a well-remodelled, healed fracture of the nasal bones. The nose would have been slightly dislocated to the right, with a deviated nasal septum.

All maxillary teeth and the mandibular molars, right second premolar, and the left first premolar are missing antemortem. Teeth present are the right canine and right first premolar, which lack carious lesions and hypoplasia and show medium calculus deposits.

**BOX 9.**—This box contains the skeletal remains of one child and one adult. All bones of the immature individual are present except for the pubis; patella; calcaneus; talus; and several ribs, carpal and tarsal bones, and vertebrae. The remains appear to represent a 6-year-old child. Five deciduous teeth are present: the maxillary canines, maxillary right second molar, mandibular right canine, and mandibular left second molar. Three deciduous teeth (maxillary right second molar, mandibular right first molar, mandibular left second molar) had been lost abnormally antemortem with extensive remodelling of the alveolar surface.

Three of the five deciduous teeth present are carious. These teeth and the size and locations of the lesions are as follows: maxillary right canine, buccal surface, 1 mm; mandibular right canine, buccal surface, 1 mm; left second molar, all of the crown surface.

Of 11 observations on alveolar abscess, one abscess is present, associated with the mandibular left second molar.

Slight dental calculus is present on both the buccal and lingual surfaces.

Two permanent teeth also are present in the child maxilla. The two first molars show no caries and have slight calculus deposits.

All adult bones are present except for several small bones of the hands and feet. The large size of the bones and the appearance of the pelvis indicate male sex.

Various morphological details on the skeleton indicate an age at death of between 60 and 70 years. Lengths of the left femur (441 mm) and the tibia (357 mm) suggest a living stature of about 167 cm.

The cranium displays very large styloid processes (46 mm in length), a button osteoma on the left frontal (4 mm in height), and copper staining on the inferior aspect of the occipital.

Three ribs of this individual show healed fractures. Fractures are located in the upper one-third of a left third or fourth rib, 50

mm from the sternal end of a right third or fourth rib, and 110 mm from the sternal end of a ninth or tenth rib.

All teeth were lost antemortem, and no active abscesses are present.

BOX 10.—The incomplete skeletal remains of two adults are present. Bones missing are a right radius, left ulna, left and right tibia, several vertebrae, several ribs, and several hand and foot bones. Two complete crania and one hyoid are present.

Both skeletons appear to be female, one aged 25–35 years and one aged 35–45 years. Pubic bones from both skeletons show deep pits of parturition (Figure 9). The pits are larger and deeper in the older woman.

Maximum fibula lengths of 318 mm and 326 mm suggest living statures of 157 cm and 159 cm.

One proximal hand phalanx shows a well-healed fracture on the distal end. One right greater multangular also shows a well-healed fracture with extensive eburnation.

In the dentition of the younger female, seven teeth are present, of which one (the mandibular right first molar) has a

metal restoration 2 mm in length on the buccal surface. Six of the 32 teeth had been lost antemortem, and no alveolar abscesses are associated. Observations on dental calculus deposits were two deposits absent, four slight deposits, and one medium deposit on the buccal surfaces; two deposits absent, three slight deposits, and two medium deposits on the lingual surfaces.

All teeth of the older individual had been lost antemortem with no associated active alveolar abscesses.

BOX 11.—This box contains the mostly complete skeletons of two adult males. All bones are present except for several ribs, vertebrae, and bones of the hands and feet, and one left femur. Morphology of the innominates indicates ages at death of 40 to 50 years and 65 to 75 years. Parietal thinning (parietals very irregular) is present on the older male.

Long-bone measurements suggest living statures of about 164 cm and 169 cm.

Four bones show evidence of disease. A right tibia has extensive destruction and new bone proliferation over much of the proximal end.

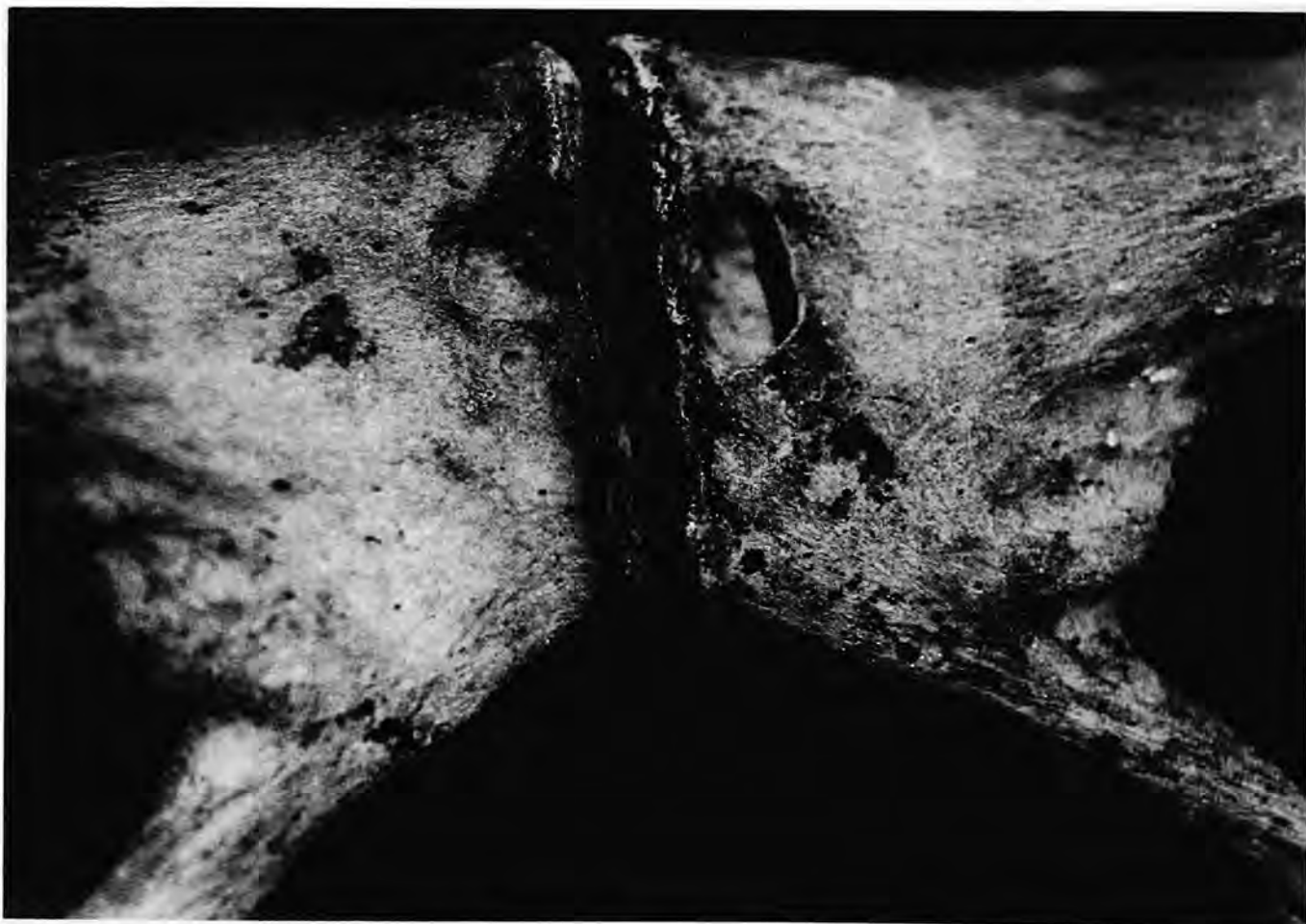

FIGURE 9.—Deep pits of parturition, Box 10.

A right femur has a well-remodelled, healed fracture on the distal one-third of the diaphysis, approximately 120 mm from the distal end. The distal end is abnormally rotated medially. The fracture extends from a point on the lateral surface 65 mm superior to the distal articular surface to a point on the medial surface 165 mm superior to the distal articular surface. The distal articular surface is very uneven, with extensive new bone formation. Apparently, infection followed fracture of the bone.

A right radius shows an old, healed, well-remodelled fracture of the midshaft. The distal half is abnormally displaced posteriorly.

A right patella displays large porous bone formation on most of the posterior surface (Figure 10). The abnormality most likely represents infection.

The older individual is completely edentulous, with no evidence of active alveolar abscess.

Twenty-two teeth of the younger individual are present. Three of the mandibular teeth (both second molars and the left third molar) are carious. All lesions are on the occlusal surface and measure about 2 mm in diameter. No hypoplasia is present. Slight deposits of dental calculus are present on both the buccal and lingual surfaces of all teeth except for medium deposits on the buccal surface of the right maxillary first molar, both surfaces of the mandibular canine and first premolar, and the lingual surface of the left first premolar.

Only the mandibular right first molar had been lost antemortem. No active alveolar abscesses are present.

BOX 12.—This box contains the mostly complete remains of two adults. Bones missing include one left and one right fibula, one cervical vertebra, and various bones of the hands and feet. Morphological details suggest both individuals are females between the ages of 45 and 60 years. One individual has slight scars of parturition on the pubic bones. The other individual lacks such pits.

Femoral long-bone lengths of 430 mm and 442 mm suggest living statures of 160 cm and 163 cm.

The maxilla and left portion of the mandible (right portion not present) of one individual are edentulous, with no alveolar abscesses.

Two teeth are present on the other individual, a maxillary left canine, and a mandibular right first premolar. Neither of these teeth are carious. The canine lacks calculus, whereas slight deposits are present on the premolar. No hypoplasia is present. Nineteen teeth had been lost antemortem, but no active alveolar abscesses are present.

TOTAL INVENTORY.—The 11 boxes contained at least 33 individuals (Table 12): 14 immature individuals and 19 adults (eight males and 11 females). Three boxes (1, 2, 8) contained only one individual. Each of these individuals were males between the ages of 33 and 43 years. The other boxes contained multiple individuals ranging in number from two (Boxes 9, 10,

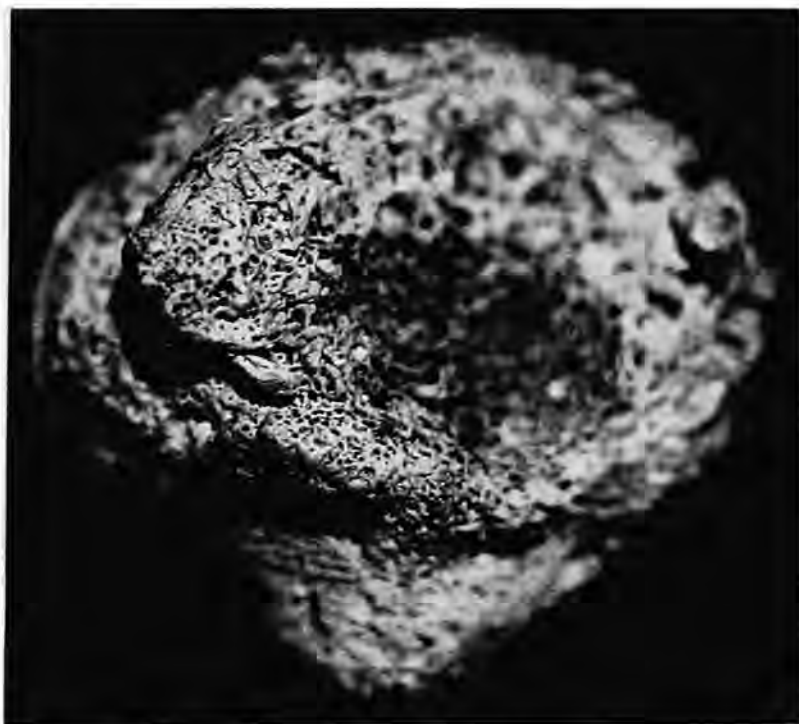


FIGURE 10.—Abnormal porous bone formation on patella, Box 11.

TABLE 12.—Skeletal contents of each box.

Box number	Individuals	Age (years)	Sex
1	1	33-38	male
2	1	38-43	male
3	7	3	?
		5	?
		7	?
		37-45	male
		22-37	female
		40-45	female
4	4	45-60	female
		6	?
		20-60	male
		35-45	female
5	8	60-70	female
		newborn	?
		0.5	?
		1.5	?
		2	?
		3	?
		6	?
		7.5	?
7	3	20-60	female
		1.5	?
		12-14	?
8	1	35-40	female
		36-40	male
9	2	6	?
		60-70	male
10	2	25-35	female
		35-45	female
11	2	40-50	male
		65-75	male
12	2	45-60	female
		45-60	female

11, 12) to eight (Box 5). None of the remains in the boxes were articulated, thus, they apparently had been transferred to the boxes from another location after the soft tissue had de-

composed or had been removed. Incisions of the upper femur area of adults from Boxes 3 and 4 suggest that at least some of the flesh had been removed with the use of a knife or large blade.

**AGE AT DEATH.**—Table 13 presents the age at death data in the form of a life table. The data suggest a life expectancy at birth of about 29 years and life expectancy at age 15 of about 31 years.

**LIVING STATURE.**—Estimates of living stature are available for six males and 10 females. All estimates were calculated using the formulae of Trotter for whites (Ubelaker, 1989:61). For individuals in the boxes, living stature for males ranged from 163 cm to 174 cm, with a mean of 168.6 cm. Female stature ranged from 153 cm to 171 cm, with a mean of 159.5 cm.

**MEASUREMENTS AND OBSERVATIONS.**—Observations on cranial and dental morphology of remains within the boxes suggest that all individuals are of predominately European ancestry. These observations include the lack of shovel-shaped incisor teeth, the presence of metopic sutures in the crania, and especially the appearance of the face. Detailed measurements and observations on the crania and mandibles are presented in Tables 14 through 17.

**PATHOLOGY.**—Many of the bones show evidence of disease and abnormalities, especially trauma.

**Trauma:** Eleven bones from five boxes show trauma of the humerus, nasal bones, ribs, hand phalanges, carpal bones, femur, radius, and frontal. The 11 bones with trauma suggest a ratio of bones with trauma to the total number of adults (19) in the sample of 0.58.

**Infection:** Evidence of infection is limited to a right tibia, right femur, and right patella, all from Box 11. Infection on these three bones suggests a ratio to the total number of adults (19) of 0.16.

TABLE 13.—Life table for box sample. (Dx=total number of individuals per age interval, dx=percentage of individuals dying in each age interval, lx=number of survivors of a theoretical cohort of 100 individuals entering each age interval, qx=probability of death in each age interval, Lx=total number of years lived during each age interval, Tx=total number of years lived after a lifetime of all individuals entering each age interval, e<sup>o</sup>x=life expectancy of all individuals entering each age interval.)

Age interval	Dx	dx	lx	qx	Lx	Tx	e <sup>o</sup> x
0-0.9	2	6.06	100.00	0.0606	96.970	2897.430	28.97
1-4.9	5	15.15	93.94	0.1613	345.460	2800.460	29.81
5-9.9	6	18.18	78.79	0.2307	348.500	2455.000	31.16
10-14.9	1	3.03	60.61	0.0500	295.475	2106.500	34.76
15-19.9	0	0	57.58	0	287.900	1811.025	31.45
20-24.9	0	0	57.58	0	287.900	1523.125	26.45
25-29.9	1	3.03	57.58	0.0526	280.325	1235.225	21.45
30-34.9	1	3.03	54.55	0.0555	265.175	954.900	17.50
35-39.9	3	9.09	51.52	0.1764	234.875	689.725	13.39
40-44.9	7	21.21	42.43	0.4999	159.125	454.850	10.72
45-49.9	1	3.03	21.22	0.1428	98.525	295.725	13.94
50-54.9	3	9.09	18.19	0.4997	68.225	197.200	10.84
55-59.9	0	0	9.10	0	45.500	128.975	14.17
60-64.9	0	0	9.10	0	45.500	83.475	9.17
65-69.9	2	6.06	9.10	0.6659	30.350	37.975	4.17
70-74.9	1	3.03	3.04	0.9967	7.625	7.625	2.51

TABLE 14.—Measurements of male crania and mandibles, box sample. (S.D.=standard deviation.)

Measurement	Box number							Total	Mean	S.D.	Range
	1	2	3	8	9	11	11				
Maximum height	116	123	—	111	120	125	123	6	120	5.28	111–125
Auricular height	116	119	—	109	120	122	122	6	118	4.94	109–122
Porion-bregma	111	116	—	108	118	121	120	6	116	5.16	108–121
Cranial length	177	183	—	166	181	181	186	6	179	7.01	166–186
Cranial breadth	141	145	—	138	142	144	144	6	142	2.58	138–145
Basion-bregma	132	134	—	131	139	134	122	6	132	5.62	122–139
Minimum frontal breadth	102	98	—	90	95	102	102	6	98	4.92	90–102
Upper facial height	68	67	—	72	70	74	78	6	72	4.09	67–78
Facial breadth	—	125	—	120	133	135	129	5	128	6.07	120–135
Nasal height	46	48	—	53	57	58	54	6	53	4.80	46–58
Nasal breadth	21	22	—	25	23	25	25	6	24	1.76	21–25
Orbital height	35	34	35	38	34	35	35	7	35	1.35	34–38
Orbital breadth	41	41	38	41	46	41	42	7	41	2.37	38–46
Maxillo-alveolar length	54	51	47	47	51	56	53	7	51	3.40	47–56
Maxillo-alveolar breadth	56	62	56	56	55	62	50	7	57	4.19	50–62
Palatal length	46	49	41	40	48	50	46	7	46	3.86	40–50
Palatal breadth	36	36	38	34	40	36	31	7	36	2.85	31–40
Bicondylar breadth	—	115	—	110	127	129	127	5	122	8.53	110–129
Bigonial breadth	—	94	—	91	88	97	102	5	94	5.41	88–102
Height of ascending ramus	—	58	—	67	66	62	65	5	64	3.65	58–67
Minimum breadth of ascending ramus	—	36	—	26	34	35	28	5	32	4.49	26–36
Height at mandibular symphysis	—	31	—	32	30	32	33	5	32	1.14	30–33
Total facial height	—	114	—	—	—	122	—	2	118	5.66	114–122

TABLE 15.—Measurements of female crania and mandibles, box sample. (S.D.=standard deviation.)

Measurement	Box number						Total	Mean	S.D.	Range	
	3	3	4	10	10	12					12
Maximum height	119	114	113	110	112	—	121	6	115	4.26	110–119
Auricular height	118	107	112	110	110	—	116	6	112	4.12	107–118
Porion-bregma	117	107	110	108	108	—	113	6	111	3.83	107–117
Cranial length	173	168	170	164	172	—	179	6	171	5.06	164–173
Cranial breadth	149	—	136	130	133	—	142	5	138	7.58	130–149
Basion-bregma	137	121	—	117	119	—	125	5	124	7.95	117–137
Minimum frontal breadth	101	93	91	84	87	94	94	7	92	5.48	84–101
Upper facial height	71	—	—	67	61	66	71	5	67	4.15	61–71
Facial breadth	—	—	—	116	118	—	122	3	119	3.06	116–122
Nasal height	52	45	—	49	50	52	54	6	50	3.14	45–52
Nasal breadth	25	22	—	24	24	25	24	6	24	1.10	22–25
Orbital height	38	38	—	34	34	35	34	6	36	1.97	34–38
Orbital breadth	44	40	—	38	37	41	40	6	40	2.45	37–44
Maxillo-alveolar length	51	47	—	49	46	46	56	6	49	3.87	46–56
Maxillo-alveolar breadth	59	55	—	58	46	53	50	6	54	4.93	46–59
Palatal length	46	39	—	42	40	43	46	6	43	2.94	39–46
Palatal breadth	40	32	—	36	37	41	33	6	37	3.62	32–40
Bicondylar breadth	—	—	—	108	122	—	116	3	115	7.02	108–122
Bigonial breadth	—	94	—	87	99	—	87	4	92	5.85	87–99
Height of ascending ramus	—	—	—	59	60	53	55	4	57	3.30	53–60
Minimum breadth of ascending ramus	—	—	—	27	28	23	30	4	27	2.94	23–30
Height at mandibular symphysis	—	32	—	29	—	—	25	3	29	3.51	25–32

*Tumors:* One small benign "button" osteoma tumor is present on a frontal from Box 9.

*Porotic Hyperostosis:* Two frontal orbits show evidence of cribra orbitalia in remains from Box 3. This suggests the percentage of individuals (2) with porotic hyperostosis among the total number of individuals in the sample (33) is 6.

*Dental Disease, Deciduous Teeth:* Eleven deciduous teeth are present. Nine of these have carious lesions (82%). Of 30

observations on the presence or absence of teeth, three (10%) were abnormally absent antemortem. Of 17 observations for the presence or absence of alveolar abscesses, two (12%) abscesses were noted. All calculus deposits (11) were slight on both the buccal and lingual surfaces.

*Dental Disease, Permanent Teeth:* Of 108 permanent teeth in the box sample, 14 (13%) are carious. Of 434 observations on the presence or absence of teeth, 214 (49%) were absent ante-



TABLE 16.—Nonmetric observations of male crania and mandibles, box sample. Observations on skeletal features that are not sided straddle columns. (L=left, R=right, A=absent, N=notch, P=present.)

Skeletal feature	Box number													
	1		2		3		8		9		11		11	
	L	R	L	R	L	R	L	R	L	R	L	R	L	R
Mylohyoid bridge	-	-	A	A	-	-	A	A	A	A	A	A	A	A
Accessory mental foramen	-	-	A	A	-	-	A	A	A	A	A	A	A	A
Frontal grooves	A	A	A	A	P	-	A	A	A	A	P	P	P	P
Supraorbital foramina	P	P	A	A	P	N	N	N	N	N	N	N	N	N
Trochlear spur	A	A	A	A	A	A	A	A	A	A	A	A	A	A
Accessory optic canal	A	A	A	A	A	A	A	A	A	A	A	A	A	A
Infraorbital suture	-	A	A	A	A	A	A	A	A	A	A	A	A	A
Os japonicum trace	-	A	A	A	-	-	A	A	A	A	A	A	A	A
Wormian bones	P	P	A	A	-	-	A	A	A	A	A	A	A	A
Parietal process of temporal squama	A	A	A	A	-	-	A	A	A	A	A	A	A	A
Squamoparietal synostosis	A	A	A	A	A	-	A	A	A	A	A	A	A	A
Auditory exostoses	A	A	A	A	A	-	P	P	A	A	A	A	A	A
Pharyngeal fossa		A		A		P		A		A		P		A
Paracondylar process	A	A	A	A	-	-	A	A	A	A	A	A	A	A
Intercondylar canal	A	A	A	A	-	-	A	A	A	A	A	A	A	A
Odonto-occipital articulation		A		A		-		A		A		A		A
Divided hypoglossal canal	A	A	A	A	-	-	A	A	A	A	A	A	A	A
Postcondylar canal	A	A	A	A	-	-	P	P	P	A	P	P	P	P
Marginal foramen of tympanic plate	A	A	A	A	A	-	A	A	A	A	A	A	A	A
Tympanic dehiscence	A	A	A	A	A	-	A	A	A	A	A	A	A	A

TABLE 17.—Nonmetric observations of female crania and mandibles, box sample. Observations on skeletal features that are not sided straddle columns. (L=left, R=right, A=absent, N=notch, P=present.)

Skeletal feature	Box number													
	1		2		4		10		10		12		12	
	L	R	L	R	L	R	L	R	L	R	L	R	L	R
Mylohyoid bridge	-	-	A	A	-	-	P	A	A	A	A	-	A	A
Accessory mental foramen	-	-	A	A	-	-	A	A	A	A	A	-	A	A
Frontal grooves	A	A	A	A	A	A	A	A	P	P	A	A	P	P
Supraorbital foramina	N	P	A	A	P	N	A	A	N	N	P	P	P	P
Trochlear spur	-	-	A	A	A	A	A	A	A	A	A	A	A	A
Accessory optic canal	A	A	A	A	-	-	A	A	A	A	A	A	A	A
Infraorbital suture	A	A	A	A	-	-	A	A	P	A	A	A	A	A
Os japonicum trace	-	-	-	-	-	-	A	A	A	A	-	A	A	A
Wormian bones	A	A	A	A	A	A	A	A	A	A	-	-	A	A
Parietal process of temporal squama	A	A	A	A	A	A	A	A	A	A	-	-	A	A
Squamoparietal synostosis	A	A	A	A	A	A	A	A	A	A	-	-	A	A
Auditory exostoses	A	A	A	A	A	A	A	A	A	A	-	-	A	A
Pharyngeal fossa		A		A		-		A		A		-		A
Paracondylar process	A	A	A	A	-	-	A	A	A	A	-	-	A	A
Intercondylar canal	A	A	A	A	-	-	A	A	A	A	-	-	A	A
Odonto-occipital articulation		A		A		-		A		A		-		A
Divided hypoglossal canal	A	A	A	A	-	-	A	A	A	A	-	-	A	A
Postcondylar canal	P	P	A	A	-	-	P	P	P	P	-	-	P	P
Marginal foramen of tympanic plate	A	A	A	A	-	-	A	A	A	A	-	-	A	A
Tympanic dehiscence	A	A	A	A	A	A	A	A	A	A	-	-	P	-

mortem. Of 397 observations on alveolar abscess, only four (1%) abscesses were noted. Observations for dental calculus were made on 104 permanent teeth. The frequencies of these observations are 10 deposits absent, 87 slight deposits, seven medium deposits, and no large deposits on the buccal surfaces; four deposits absent, 88 slight deposits, 12 medium deposits, and no large deposits on the lingual surfaces. Only one dental hypoplastic defect was present (1%).

### Summary

The above analysis suggests that 226 individuals are present in the entire sample, 111 subadults and 115 adults. Note that although complete inventories were made of all material in the superficial samples and in the boxes, the strata cuts represent only a minimal sampling of the entire ossuary. These recovered remains, coupled with the minimal 201 individuals represented

in the nonossuary samples (Ubelaker, 1994a), produce a sample of at least 427 individuals from the San Francisco facility. Comparative data from Ecuador are available from the following sources: Ubelaker, 1980a, 1980b, 1981, 1983, 1988a, 1988b, 1988c, 1988d, 1988e, 1990, 1994a, 1994b, 1995, 1996, and Ubelaker and Rousseau, 1993.

#### MORTUARY PRACTICES

Articulated skeletons were found only in the stratigraphic excavation of the upper chamber. Analysis indicates that 22 individuals (9 adults, 13 subadults) are represented by the 74 articulations. Four individuals appeared to be generally complete, three males and one female. This indicates that about 30% of the upper-chamber sample was at least partially articulated at the time of deposit in the ossuary. All other remains in the ossuary were secondary, indicating that the flesh had decomposed or had been altered before their transfer. Note that several of the bones show evidence of intentional removal of the flesh. The bones provide no clues regarding the original repository of the bodies before ossuary burial. Presumably they were interred in the ground or in niches. All samples except the superficial sample of the lower chamber appear to represent cross sections of the population, i.e., infants, children, men, and women are present. The exception is the superficial sample of the lower chamber, which is primarily composed of middle-aged men. It seems probable that during the period from AD 1770 to 1890, the disarticulated remains of church officials were deposited in this lower chamber, or for some other reason only adult males were selected for burial at this site. As noted earlier, remains of recent individuals are present in this sample as well.

#### ANCESTRY

Morphological analysis and observations indicate that nearly all of the individuals in these samples are of mostly European origin. The exception is the individual of apparent African ancestry found within the excavation of the upper chamber. Evidence of African ancestry also was found in the church sample (Ubelaker, 1994a). Individuals of the *zaguán* and atrium samples were exclusively of South American Indian origin, whereas those of the main cloister and church samples likely were of European as well as of South American Indian origin (Ubelaker, 1994a).

#### STATURE

Average values for living stature of adult males in these samples ranged from 164 cm (upper-chamber superficial sample) to 170 cm, and female values ranged from 149 cm to 160 cm. All of these values, except those for the modern boxes, fall within the range of variation documented for prehistoric populations (157–164 cm for males, 148–161 cm for females), even

though they likely represent individuals of very different ancestries. Mean stature values for the previously reported historic Quito samples ranged from 145 cm to 161 cm for males and from 149 cm to 155 cm for females.

#### PATHOLOGY

**PERIOSTEAL LESIONS.**—Lesions of the bone periosteal surfaces likely represent skeletal response to infection, although other causes, such as trauma, cannot be ruled out in some cases. To make these data comparable with those recorded from other samples, they are expressed as the ratio of bones with lesions to the total number of adults in the sample and to the total number of individuals in the samples. The ratios of bones with lesions to adults in the ossuary samples range from 0.16 to 0.76. These values fall within the ranges of this ratio previously documented for historic Quito samples (0.06–1.00) but exceed those of prehistoric samples (0–0.61). Values for the ratio using the total number of individuals in the ossuary samples (0.09–0.42) extend the previously documented range for historic Quito samples (0.03–0.26) but fall within the prehistoric range (0–0.55). No temporal trend in periosteal lesions is apparent within the ossuary samples.

Most evidence of infection from all samples suggests non-specific periostitis. The possible exceptions are the frontal lesions from the lower-chamber superficial sample. The multiple, small, cavitating lesions appear consistent with those produced by tertiary syphilis of the cranial vault, although other types of infection cannot be ruled out.

**TRAUMA.**—Comparative data on traumatic lesions are expressed as the ratios of bones with evidence of trauma to the total number of adults in the sample and to the total number of individuals in the sample. Within the ossuary samples, the former values range from 0 to 0.58, whereas the latter values range from 0 to 0.33. The high values exceed the range previously documented for other historic Quito samples (0–0.19 for adults; 0–0.09 for individuals) as well as the prehistoric range (0–0.33 for adults; 0–0.19 for individuals). The modern box sample shows the lowest level of infectious disease but shows a high frequency of trauma. The data suggest a trend toward increasing trauma within the ossuary samples. Although no examples of trauma were found in the upper-chamber superficial sample, values for the comparatively recent box sample and lower-chamber superficial sample are substantially greater than those from the upper and lower strata-cut samples. This trend likely reflects an increase in frequency of urban accidents and perhaps, to some extent, urban violence.

**LINES OF INCREASED DENSITY.**—Another general measure of morbidity in the population involves assessment for evidence of disruptions in the normal long-bone growth due to dietary or disease stress. Temporary slowdown in growth in response to stress may leave behind lines of increased density that can be detected through radiography. In the ossuary samples, distal tibiae of mature and immature individuals were ex-

amined for these lines. Radiographs of 58 immature tibiae from both strata cuts (upper and lower chambers) revealed 22 bones with 44 lines. The size of each bone and the distance from the line (if present) to the distal end of the bone was measured. These measurements were then used to estimate the age of the individual represented by each bone as well as the age of formation of each line. As shown in Table 18, of 19 tibiae from the lower-chamber strata cut, from individuals aged newborn to 6 years, four bones (21%) revealed nine lines for an average of 0.47 lines per individual. The mean age of line formation was 1.1 years, with a range from 1 to 1.5 years.

The possibly slightly earlier sample from the upper-chamber strata cut showed a higher frequency of lines, with 46% of bones showing lines, 0.90 lines per bone, and a mean age of line formation of 1.3 years. The data perhaps suggest a temporal decrease in morbidity as indicated by lines of arrested growth.

Lines of increased density from mature tibiae show a similar pattern. Mature tibiae were available from three samples: the modern box sample and the superficial samples from both the upper and lower chambers. Table 19 reveals that the percentage of bones with lines and the number of lines per individual are greatly reduced in the modern box sample in comparison to the earlier samples.

Differences in age of line formation between the immature and mature samples likely reflect the elimination, by the remodelling process, in mature bones of lines formed early in life. The immature bones indicate that the first year of life was especially stressful in the early populations of Quito. The mature bones indicate that stress also occurred in the later childhood years, especially between 6 and 11 years.

**CARIOUS LESIONS.**—The frequency of carious permanent teeth ranged from 6% to 32% in the ossuary samples, whereas the prehistoric range is 0% to 11%. The range of mean carious teeth values previously recorded for Quito samples is 5%–15%. Of particular notice is the 82% caries rate for deciduous teeth in the box sample. Values for the three most recent samples

(box and superficial collections) are much higher than those for the strata cuts. These values likely represent the availability and extensive use of sugar in modern times.

**DENTAL HYPOPLASIA.**—Very few permanent hypoplastic teeth were noted, with frequencies ranging from 0% to 3.6%. These values fall well within the prehistoric range of 0%–6% and are similar to those reported for other historic Quito samples (0%–3%).

**ANTEMORTEM LOSS OF TEETH.**—Many teeth had been lost antemortem in the ossuary samples. Frequencies of antemortem loss ranged from 11% to 89%, largely reflecting the longevity of many of the individuals in the samples. This range is greater than that documented for prehistoric samples (1%–42%) and for other previously reported historic Quito samples (4%–24%).

**ALVEOLAR ABSCESSSES.**—Frequencies of active alveolar abscesses ranged from 0% to 6%, in contrast to a prehistoric range of 0% to 12% and the previously reported historic range of 1% to 6%. Again, this comparatively low frequency likely reflects the advancing age of many adults in these samples who likely had many abscessed teeth earlier in their lives.

**POROTIC HYPEROSTOSIS.**—Several examples of porotic hyperostosis of the immature frontal orbits (cribra orbitalia) were noted in the ossuary samples. The origin of this condition is not clear, although considering the European origin of the individuals represented, congenital anemias cannot be ruled out. Analysis of precontact samples shows such conditions are confined to coastal populations and likely represent acquired anemia.

**OTHER DISEASES.**—The presence of tumors, exostoses, and abnormal long-bone curvature depart from the prehistoric pattern but are consistent with findings from other historic samples in the Quito area (Ubelaker, 1994a).

The San Francisco ossuary samples document that early historic peoples of Quito were plagued with problems of disease. For the most part, however, although levels of morbidity were high, they were similar to those experienced by the indigenous populations during the late precontact period. Although the fre-

TABLE 18.—Lines of increased density in immature tibiae.

Sample	Number of bones	Bone size (mm)	Bone age (yrs)	Bones with lines		Total lines	Lines per individual	Age of line formation	
				number	%			Mean	Range
Lower-chamber strata cut	19	64–200	newborn to 6	4	21	9	0.47	1.1	1–1.5
Upper-chamber strata cut	39	61–208	newborn to 5	18	46	35	0.90	1.3	0.5–5

TABLE 19.—Lines of increased density in mature tibiae.

Sample	Number of bones	Bones with lines		Total number of lines	Lines per individual	Age of line formation	
		Number	%			Mean	Range
Box	11	1	9	1	0.09	9	9–9
Lower-chamber superficial	12	5	42	6	0.50	10	8–11
Upper-chamber superficial	11	4	36	4	0.36	7	3–11

quency of the evidence for disease does not increase dramatically in this historic sample in comparison with that documented for precontact samples, the diversity of such evidence certainly does increase.

The evidence of morbidity reported herein not only adds to the emerging geographical and temporal pattern gleaned from skeletal analysis, but it complements the historic record as well. Much of the archival evidence for the disease experience in Ecuador has been summarized and interpreted by Alchon (1991) and Newson (1995). Newson's reading of the archival evidence indicates a likely precontact presence of chronic and endemic diseases, especially respiratory and intestinal problems. Her list of specific diseases present include bartonellosis (carrion's disease, called Oroya fever in its acute phase and verruga peruana in its chronic phase), leishmaniasis (uta), Chagas' disease, treponemal disease, and possibly typhus. Alchon suggests that the following specific diseases likely were also present: toxoplasmosis, amebiasis, giardiasis, enterobiasis (pinworms), trichuriasis (whipworms), ancylostomiasis (hookworms), tuberculosis, bacterial pneumonia, blastomycosis, and possibly leptospirosis and herpes.

In historic times, new diseases arrived from the Old World with severe impact on Ecuadorians. According to Newson (1995) and Alchon (1991), these may have included smallpox, pneumonic plague, measles, influenza, mumps, diphtheria, scarlet fever, and malaria. These newly introduced diseases inflicted severe mortality on early historic populations of Ecuador. Newson and Alchon suggest major epidemics for the Quito area in the periods 1524–1528, 1531–1533, 1546, 1558–1589, 1585–1591, and 1691–1695, resulting in significant depopulation. In addition, Alchon suggests that less severe epidemics occurred in 1611, 1618, and 1648 and occurred during the eighteenth century on an average of one epidemic every six years.

It is difficult to correlate exactly the skeletal record of disease in the ossuary samples with the suggested historical record of epidemics. Most of the severe diseases fueling the epidemics resulted in rapid mortality that would not likely produce skeletal reaction. In addition, the samples reported herein cannot be dated with sufficient precision to allow accurate comparison with the historic record of epidemic disease. General discussion of this correlation is provided by Ubelaker (1994b, 1995, 1996).

#### DEMOGRAPHIC PROFILES

Demographic data from the ossuary samples suggest high levels of mortality, especially during the earliest sample, the upper-chamber strata cut. Because the lower-chamber superficial sample represents mostly adult males, it clearly does not offer information about the general population. The other four samples appear to show a normal distribution of sexes and ages at death and thus may represent a cross section of the general

population. Life tables were constructed only for the upper-chamber strata cut and box samples, where the sample sizes were large and reliable ages at death could be established. Values for life expectancy at birth in these samples were 14 and 29, respectively. The value for 14 for the oldest sample, the upper-chamber strata cut, approaches the lowest value recorded for precontact samples (12, precontact range 12–31). The box value of 29 falls at the upper end of the precontact range. Similarly, the values for life expectancy at age 15 of 30 and 31 for the ossuary samples are above the entire precontact range (18–26). Clearly, adult longevity increased in the populations represented by the ossuary samples over those of precontact populations. The range of life expectancy at birth for the non-ossuary San Francisco samples was only 16 to 18. Values for life expectancy at age 15 for these samples was 15 to 22 years.

The mean age of the ossuary samples ranged from 14 to 38 years. This range is substantially greater than that previously documented for prehistoric Ecuadorean samples (12–31 years) and for other historic samples (10–25 years).

The mean age at death for males in the ossuary samples was calculated to range from about 39 to 54 years. These values are considerably greater than those values previously reported for prehistoric samples (23–43 years) and other historic samples (25–41 years).

Mean age at death of females (44–55 years) also is greater than values previously reported for prehistoric samples (22–40 years) and other historic samples (18–55 years).

The ratio of individuals less than 15 years of age to those age greater than 15 years also provides a comparative context. The ossuary samples suggest this ratio decreased through time from 2.52 in the upper-chamber strata cut, to 1.71 in the lower-chamber strata cut, to 1.63 in the upper-chamber superficial sample, and to only 0.74 in the box sample. This temporal trend indicates an early very high rate of subadult mortality that gradually declined. This trend likely reflects the high demographic impact among the young of epidemic disease during the early colonial history of Quito. These values fall within those reported for precontact Ecuador, which range from 0.11 at the highland site of Cumbaya to 2.50 in the small sample from the coastal site of Agua Blanca. The range reported herein is similar to that previously reported for historic samples from Quito (0.35–2.80).

The data presented herein supplement those available from other historic samples from Quito and those dated to prehistoric times throughout Ecuador. The opportunity to study these ossuary samples greatly contributes to the growing knowledge about biological aspects of past Ecuadorean populations. Although the health problems encountered by the historic populations who were buried within the ossuary at San Francisco Church were considerable, they were not dramatically different from those endured by their South American Indian predecessors in ancient Ecuador.

## Literature Cited

- Alchon, Suzanne Austin  
1991. *Native Society and Disease in Colonial Ecuador*. viii+151 pages. Cambridge: Cambridge University Press.
- Bass, William M.  
1987. *Human Osteology. A Laboratory and Field Manual*. Third Edition, xviii+327 pages. Columbia, Missouri: Missouri Archaeological Society, Special Publication, number 2.
- Klepinger, Linda L.  
1979. Paleodemography of the Valdivia III Phase at Real Alto, Ecuador. *American Antiquity*, 44(2):305-309.
- Klepinger, L.L., J.K. Kuhn, and J. Thomas, Jr.  
1977. Prehistoric Dental Calculus Gives Evidence for Coca in Early Coastal Ecuador. *Nature*, 269:506-507.
- Munizaga, J.R.  
1965. Skeletal Remains from Sites of Valdivia and Machalilla Phases, Appendix 2. In B.J. Meggers, C. Evans, and E. Estrada, Early Formative Period of Coastal Ecuador: The Valdivia and Machalilla Phases. *Smithsonian Contributions to Anthropology*, 1:219-234.  
1976. Intentional Cranial Deformation in the PreColumbian Populations of Ecuador. *American Journal of Physical Anthropology*, 45: 687-694.
- Newson, Linda A.  
1995. *Life and Death in Early Colonial Ecuador*. xii+505 pages. Norman: University of Oklahoma Press.
- Stewart, T.D.  
1979. *Essentials of Forensic Anthropology, Especially as Developed in the United States*. xvii+300 pages. Springfield: Charles C. Thomas.
- Terán de Rodríguez, Paulina  
1988. Estudio de Investigación Arqueológica. Convento de San Francisco de Quito, Sitio OPQSF-2. 6 pages. [Unpublished report, Instituto de Cooperación Ibero Americana de España and Instituto de Patrimonio Cultural del Ecuador, Quito, Ecuador.]
- Ubelaker, Douglas H.  
1980a. Human Skeletal Remains from Site OGSE-80, A Pre-Ceramic Site on the Sta. Elena Peninsula, Coastal Ecuador. *Journal of the Washington Academy of Sciences*, 70(1):3-24.  
1980b. Prehistoric Human Remains from the Cotocollao Site, Pichincha Province, Ecuador. *Journal of the Washington Academy of Sciences*, 70(2):59-74.  
1981. The Ayalán Cemetery: A Late Integration Period Burial Site on the South Coast of Ecuador. *Smithsonian Contributions to Anthropology*, 29: 175 pages, 119 figures, 170 tables.  
1983. Human Skeletal Remains from OGSE-172, an Early Guangala Cemetery Site on the Coast of Ecuador. *Journal of the Washington Academy of Sciences*, 73(1):16-26.
- 1988a. Human Remains from OGSE-46, La Libertad, Guayas Province Ecuador. *Journal of the Washington Academy of Sciences*, 78(1):3-16.  
1988b. Prehistoric Human Biology at La Tolita, Ecuador, A Preliminary Report. *Journal of the Washington Academy of Sciences*, 78(1): 23-37.  
1988c. A Preliminary Report of Analysis of Human Remains from Agua Blanca, A Prehistoric Late Integration Site from Coastal Ecuador. *Journal of the Washington Academy of Sciences*, 78(1):17-22.  
1988d. Restos Humanos Prehistóricos del Sitio Cotocollao, Provincia del Pichincha, Ecuador, Appendix II. In Marcelo Villalba, Cotocollao: Una Aldea Formativa del Valle de Quito. *Miscelánea Antropológica Ecuatoriana*, serie monográfica, 2:557-571. Quito: Museos del Banco Central del Ecuador.  
1988e. Restos de Esqueletos Humanos del Sitio OGSE-80. In Karen E. Stothert, *La Prehistoria Temprana de la Península de Santa Elena, Ecuador: Cultura Las Vegas*, pages 105-132. Guayaquil: Museos del Banco Central del Ecuador.  
1988f. Skeletal Biology of Prehistoric Ecuador: An Ongoing Research Program. *Journal of the Washington Academy of Sciences*, 78(1):1-2.  
1989. *Human Skeletal Remains: Excavation, Analysis, Interpretation*. Second edition, xi+172 pages. Washington, D.C.: Taraxacum.  
1990. Human Skeletal Remains from "Jardín del Este," Cumbaya, Pichincha, Ecuador. In Jozef Buys, editor, *La Preservación y Promoción del Patrimonio Cultural del Ecuador*, pages 22-52. Quito: Instituto Nacional de Patrimonio Cultural, Cooperación Técnica Ecuatoriana-Belga No. 4.  
1994a. *Biología de los Restos Humanos Hallados en el Convento de San Francisco*. 225 pages. Quito: Instituto Nacional de Patrimonio Cultural del Ecuador and Agencia Española de Cooperación Internacional, Smithsonian Institution. [In Spanish, also published in English.]  
1994b. The Biological Impact of European Contact in Ecuador. In C.S. Larsen and G.R. Milner, editors, *In the Wake of Contact: Biological Responses to Conquest*, pages 147-160. New York: Wiley-Liss.  
1995. Osteological and Archival Evidence for Disease in Historic Quito, Ecuador. In S.R. Saunders and A. Herring, editors, *Grave Reflections: Portraying the Past Through Cemetery Studies*, pages 223-239. Toronto: Canadian Scholars' Press, Inc.  
1996. The Impact of Infectious Disease. In E.P. Fischer and S. Klose, editors, *Infectious Diseases: The Diagnostic Challenge*, pages 157-198. München: Piper.
- Ubelaker, D.H., and A. Rousseau  
1993. Human Remains from Hospital San Juan de Dios, Quito, Ecuador. *Journal of the Washington Academy of Sciences*, 83(1):1-8.