

Human Remains from La Florida, Quito, Ecuador

Douglas H. Ubelaker



Smithsonian Institution Press

Washington, D.C.

2000

ABSTRACT

Ubelaker, Douglas H. Human Remains from La Florida, Quito, Ecuador. *Smithsonian Contributions to Anthropology*, number 43, 28 pages, 14 figures, 10 tables, 2000. Excavations from 1984 to 1988 at the site of La Florida in suburban Quito, Ecuador, discovered six very deep shaft tombs dating to about AD 340 (Chaucpicruz phase of the Regional Development period).

Analysis of the human remains recovered from the tombs indicates the presence of at least 76 individuals. Data are presented to support archeological interpretations of mortuary procedure and social status of individuals. Cultural observations include perimortem sharp-force trauma, cranial deformation, interproximal grooves, and evidence of squatting postures on foot bones. Frequencies of skeletal indicators of pathology are low compared to other prehistoric samples from Ecuador, suggesting relatively good health. Biological evidence of status differences were largely confined to carbon isotopes, suggesting high-status individuals consumed more maize.

OFFICIAL PUBLICATION DATE is handstamped in a limited number of initial copies and is recorded in the Institution's annual report, *Annals of the Smithsonian Institution*.

Library of Congress Cataloging-in-Publication Data

Ubelaker, Douglas H.

Human remains from La Florida, Quito, Ecuador / Douglas H. Ubelaker.

p. cm.—(Smithsonian contributions to anthropology ; no. 43)

Includes bibliographical references.

I. Florida Site (Quito, Ecuador) 2. Indians of South America—Ecuador—Quito Region—Antiquities. 3. Indians of South America—Anthropometry—Ecuador—Quito Region. 4. Human remains (Archaeology)—Ecuador—Quito Region. 5. Burial—Ecuador—Quito Region. 6. Quito Region (Ecuador)—Antiquities. I. Title. II. Series.

F3721.1.Q55 U24 2000

986.6'13—dc21

99-049217

© The paper used in this publication meets the minimum requirements of the American National Standard for Permanence of Paper for Printed Library Materials Z39.48—1984.

Contents

	<i>Page</i>
Introduction	1
Methods	2
Tomb Contents	2
Tomb C-1	2
Tomb C-2	4
Tomb P-1	9
Tomb P-2	13
Tomb P-3	14
Tomb P-4	17
Test Excavations	21
Biological Analysis and Interpretation of Human Remains	21
Individual Representation	21
Cultural Alterations	23
Living Stature	24
Pathology	24
Cranial and Mandibular Measurements and Observations	25
Stable Isotope Analysis	25
Summary	27
Literature Cited	28

FIGURES

1. Location of La Florida site, Ecuador	1
2. Depression on posterior sagittal suture of 17- to 19-year-old female, C-1, E-2 ...	3
3. Colles fracture of distal right radius of 20-year-old adult, sex undetermined, C-2, E-7	5
4. Sheared surface of second cervical vertebra, P-1, Cranium 1, inferior surface ...	11
5. Sheared surface of second cervical vertebra, P-1, Cranium 1, ventral surface ...	11
6. Occlusal surfaces of mandibular teeth, P-1, Cranium 2	12
7. Interproximal grooves on mandibular right first premolar (distal surface) and sec- ond premolar (mesial surface), P-1, Level 3	13
8. Pubic bones of 45- to 50-year-old female, P-3, E-5, showing deep pitting	15
9. Exposure of pulp cavity through extreme attrition in the maxillary left first molar of the 45- to 50-year-old female, P-3, E-5	16
10. Interproximal groove on the distal buccal surface of the maxillary first molar illustrated in Figure 9, P-3, E-5	17
11. Healed fracture on sternal end of right rib, P-4, E-1B	18
12. Cribra orbitalia in both orbits of 18- to 19-year-old female, P-4, E1-D	19
13. Polished indentation of human femur, P-4, Cranium 2	20
14. Polished indentation of human femur, P-4, Cranium 2	21

TABLES

1. Permanent teeth recovered from tomb P-1, La Florida	13
2. Deciduous teeth recovered from tomb P-1, La Florida	13
3. Individuals represented within tombs at La Florida	23
4. Distribution of ages at death for each tomb at La Florida	23

5. Frequencies of antemortem tooth loss, carious lesions, alveolar abscesses, and hypoplasia in the La Florida samples	24
6. Distribution of dental calculus in La Florida samples	25
7. Cranial and mandibular measurements of high- and low-status males and females from La Florida	25
8. Cranial and mandibular observations of high- and low-status males and females from La Florida	26
9. Age at death, sex, status, and stable carbon (C) and nitrogen (N) isotope data in La Florida samples	26
10. Comparison of stable carbon (C) and nitrogen (N) isotope values of high- and low-status individuals from La Florida	27

Human Remains from La Florida, Quito, Ecuador

Douglas H. Ubelaker

Introduction

Excavations in the area of suburban Quito, highland Ecuador (2940–3030 m altitude), known as “La Florida” (0°08′45″S, 78°30′10″W) revealed six high-status shaft tombs that have been radiocarbon dated (Doyon, 1995:70) to about AD 340 (uncalibrated) ±80 (Figure 1). The excavations were sponsored by the Museum of the Banco Central del Ecuador in Quito, Ecuador, and were concentrated within section OPQLF-1 of the one kilometer La Florida site. The shaft tombs invade a slightly earlier mound, and according to project director Leon G. Doyon (1988), fill for the construction of the mound was taken from an earlier midden.

The tombs are of complex construction and extraordinary depth (12.5–15.1 m) and are laden with diverse and exotic offerings. Artifacts such as metals, marine shell, fine textiles, abundant ceramics, and two emerald beads attest to the high status of the occupants. Doyon (pers. comm., 1988) interprets the tombs as being constructed for the noble elite of a ranked social structure existing at that time. Human interments recovered represent the elite, accompanied by sacrifices, severed heads, or interments of representatives of other classes in service to the elite (Doyon, 1995). The tombs are temporally assigned to the Chaupicruz phase (ca. AD 1–500) of the Regional Development period.

At the invitation of Doyon, during the months of August 1988 and July to August 1989 I analyzed the human skeletal re-

mains recovered from the excavations. The analysis presented herein is largely limited to biological information gleaned from the recovered human remains. All archeological details, including mortuary analysis, interpretation of burial position, and procedure, will be reported separately by Doyon, supplementing published information (Doyon, 1988, 1995). Detailed skeletal inventories of each relevant unit are presented herein to facilitate future interpretations of this complex and ritually significant site.

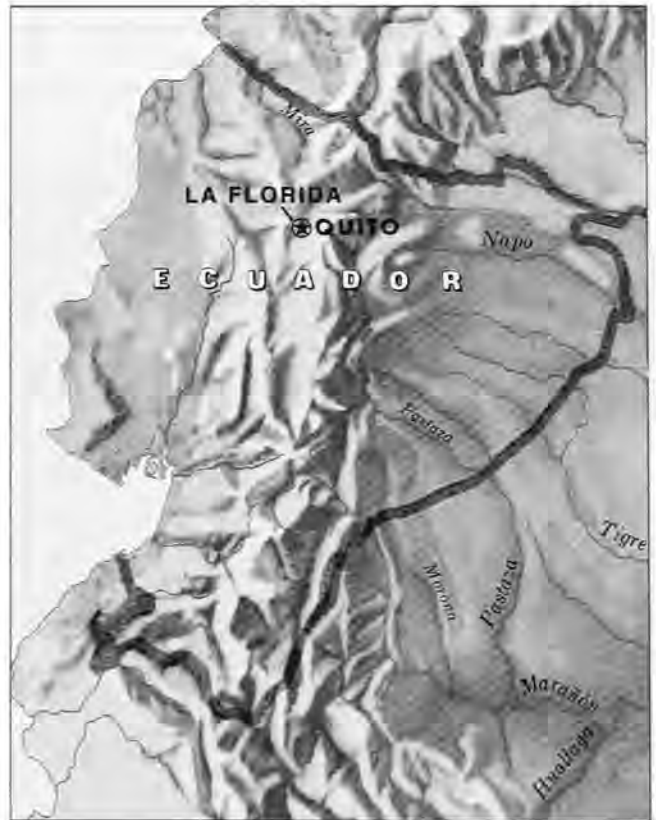

FIGURE 1.—Location of La Florida site, Ecuador.

Douglas H. Ubelaker, Department of Anthropology, National Museum of Natural History, Smithsonian Institution, Washington, D.C. 20560-0112.

Review Chairperson: Dennis Stanford, Department of Anthropology, National Museum of Natural History, Smithsonian Institution, Washington, D.C., 20560-0112.

Reviewers: William M. Bass, Department of Anthropology, The University of Tennessee, Knoxville, Tennessee, 37996-0720; Leon G. Doyon, Department of Anthropology, Yale University, New Haven, Connecticut, 06520-8277; John Verano, Department of Anthropology, Tulane University, New Orleans, Louisiana, 70118-5670.

METHODS

The analysis was completed in Doyon's laboratory near the site with the able assistance of Doyon and Megan Criley. All of the human remains had been cleaned prior to my arrival, greatly facilitating the study.

The six tombs had been labeled by Doyon with "P" or "C." The P numbers refer to those tombs that had been refilled by the La Florida population to the original surface level, apparently using the same soil that had been removed. The C numbers refer to those tombs with entrances that had collapsed. Apparently, all the tombs included a central internal pit that, except in P-2, was left empty and was covered with wood before fill material was added above. Eventually, the wood covering collapsed, allowing the fill above to enter the central pit, resulting in considerable mixing. Burials in P-2 were placed within the central pit, which was not covered, and only the burial bundle itself collapsed.

Within each tomb, bone concentrations were labeled with "E" or "S" numbers or with some other individual indication. The E numbers refer to what appeared at excavation to be concentrations of human remains. The S numbers refer to "special" materials that appeared at excavation to be nonceramic and nonhuman. Each tomb contained two or more high-status individuals as indicated by inclusion of a bundle burial in the organic remains as well as by the quantity and type of associated sumptuary materials. Within most tombs, one individual displayed a burial pattern and was associated with cultural materials that suggested that his/her death was the reason for the tomb's construction. This individual is termed the "principal burial." High-status individuals in addition to the principal burial were termed "companion burials." These individuals, found adjacent to the principal burial, were associated with high-status artifacts, but the associated artifacts were less abundant and were of inferior quality to those associated with the principal burial. Many of these high-status skeletons were incomplete, frequently missing bones of the legs, and some are represented only by cranial bones.

A third category of interment found within the tombs was termed "sacrificial burials." These remains generally lacked associated artifacts and were found in a variety of positions. The nature of these positions (hands in faces, protective positions) suggested to Doyon (pers. comm., 1988) that many of them, if not all, were buried alive as sacrifices.

In addition, articulated crania, mandibles, and some bones of the upper torso were found at the entrance (surface level) of four of the tombs. These were interpreted by Doyon (pers. comm., 1988) as representing body parts. Disarticulated groups of bones also were encountered in association with the articulated crania.

Identification of individual skeletons during excavation and analysis was complicated by (1) the collapse of the soil fill into the central pit (except in P-2), (2) the proximity and frequent superimposition of individuals, (3) modifications of postcranial remains and the possible placement of disarticulated body parts

near completely articulated individuals, (4) highly variable bone preservation, and (5) partial looting of two tombs (P-1 and C-2). All individual groups of human bones were given E numbers, and distinct crania were so labeled when identifiable as human. In addition, some skeletal evidence that either was recovered from passing soil through a screen or that for some other reason could not be associated securely with only one human skeleton during excavation is referred to in the text as "general."

Tomb Contents

TOMB C-1

INVENTORY.—This tomb was 15.1 m deep and about 52.1 m³ in volume. Nine groups of bones were identified.

C-1, E-1 (sacrifice): Field notes indicate this feature was found separately within the tomb and is believed to represent a sacrifice. Bones present include fragments of both humeri, both ulnae, and both femora; both tibiae; one left temporal and two right temporals; both sides of the mandible; one second cervical vertebra; four thoracic vertebrae; one lumbar vertebra; one right fourth metatarsal; and two ribs. The size of the right temporal and united epiphyses on the distal tibia and femoral head suggest an age at death of about 15 to 16 years. The maximum diameter of the femoral head is about 36 mm, suggesting female sex. The one orbit present lacks evidence of disease. All permanent teeth of one individual are present except for the right second maxillary molar and the mandibular third molars. The roots of the maxillary third molars are only about 50% complete, supporting the age estimate of about 15 to 16 years. Teeth present representing a second individual include the maxillary first and second right premolars.

C-1, E-2 (principal burial): This represents the fragmentary skeleton of a young adult or late-adolescent female. Bones present include all long bones except the tibia and fibula. Also present are a fragmentary cranium, fragments of both sides of the mandible, pelvis, all cervical vertebrae, 11 thoracic vertebrae, five lumbar vertebrae, sacrum, 13 ribs, and the following bones of the hand: both lunates, right greater multangular, both capitates, left hamate, left second metacarpal, left fifth metacarpal, six proximal hand phalanges, and 10 middle hand phalanges. The right greater multangular of a second individual also is present.

Various features of the pelvis, including a wide sciatic notch, elevated auricular area, and a well-developed preauricular sulcus indicate female sex.

The extent of epiphyseal union indicates an age at death of between 17 and 19 years. Epiphyses are not united on the sternal ends of the clavicles and are partially united on the proximal humerus and iliac crest. The roots of the maxillary third molars are 50% formed, and those of the mandibular third molars are about 75% formed.

The sagittal suture of the cranium is prematurely closed endocranially. The cranium shows marked flattening on its supe-

rior surface, with a circular depression 45 mm in diameter along the posterior sagittal suture (Figure 2). Presumably, this represents an old, healed, depressed fracture that could have initiated the early union of the sagittal suture. Other anomalies include a bony extension on the right fifth lumbar vertebra between the transverse process and the sacrum.

A shallow, thin incision approximately 6 mm long is located on the superior surface of the head of the right femur. This incision appears fresh and most likely was made during excavation.

The maximum length of the right humerus (29.5 cm) suggests a living stature of about 157 cm (5 ft, 2 in) using Trotter's 1970 formulae for white females (Ubelaker, 1989:61).

Maxillary teeth present include the right central incisor, left lateral incisor, right canine, left premolars, both first molars, right second molar, and both third molars. All 16 mandibular teeth are present.

C-1, E-3 (sacrifice): Only fragments of the following bones are present: right ulna, cranium, and both sides of the mandible. The bones appear to represent a young adult, probably between the ages of 23 and 26 years. Sex cannot be estimated.

All maxillary teeth are present except the left second molar. Mandibular teeth present include the left central incisor, left canine, all four premolars, and right first molar.

C-1, E-4 (sacrifice): This individual is represented only by a fragmentary cranium, the left mandible, and the second cervical vertebra. The extent of dental attrition suggests an age at

death of between 22 and 26 years. No reliable estimate of sex can be made.

Maxillary teeth present include the canines, right premolars, right first molar, and left third molar. Mandibular teeth present include the right lateral incisor, right first premolar, left second molar, and right third molar.

C-1, E-5 (companion burial): This individual is represented by all major long bones except the tibiae and fibulae. Other bones present include the right scapula; cranium; mandible; first and second cervical vertebrae; two other cervical vertebrae; 10 thoracic vertebrae; first, second, and third left metacarpals; two proximal hand phalanges; one middle hand phalanx; and 13 ribs.

All permanent teeth are present. Twenty-nine teeth representing at least two other individuals also are present. These consist of two maxillary right central and lateral incisors, two right canines, and two right first premolars. Additional teeth present consist of the maxillary second premolars, first molars, left second molar, third molars, and the following mandibular teeth: right central incisor, lateral incisors, canines, first premolars, and first molars.

All cranial sutures are ununited. The following epiphyses were not united: proximal femur, greater trochanter of femur, iliac crest, proximal humerus, proximal ulna, distal radius, proximal radius, and proximal clavicle. The ilium and ischium were not united. The distal humerus was in the process of uniting. The roots of the third molars were about 50% complete. These data collectively suggest an age at death of about 15 years.



FIGURE 2.—Depression on posterior sagittal suture of 17- to 19-year-old female, C-1, E-2.

TOMB C-2

Female sex is suggested by the small size of the bones and the appearance of the cranium.

C-1, S-1 (human remains found mixed with a large quantity of animal bones): Bones labeled S-1 consist of cranial fragments and fragments of the left humerus, one left tibia, one fragmentary fibula, one left and one right temporal, and one middle hand phalanx. Teeth represent at least two adults: two of all maxillary right teeth, two left maxillary central incisors, two left maxillary lateral incisors, one left maxillary canine, two left maxillary first premolars, one maxillary left second premolar, two of each of the left maxillary molars, one right mandibular lateral incisor, two right mandibular canines, two of all mandibular premolars, two of all mandibular first and second molars, two mandibular right third molars, and one mandibular left third molar.

The bones appear to be mature, but no reliable estimate of age at death or sex can be made.

C-1, S-2: The following fragments were mixed with animal bones: both femora, one tibia, one right innominate, one lumbar vertebra, and one left talus. The individual appears to represent a young adult, but no reliable estimate of sex can be made.

C-1, S-4 (mixed with animal bones): The following bones of an immature skeleton are present: left humerus, left radius, right clavicle, both scapulae, left temporal, right mandible, left innominate, one first cervical vertebra, and two left ribs. Maxillary teeth present are the right central incisor, both canines (crowns complete, roots 80% formed), right first premolar, and both second molars (crowns complete, roots 50% formed). Mandibular teeth present are the right canine, right first premolar (crown complete, root 80% formed), right second premolar (crown complete, root 50% formed), right first molar (crown complete, root complete), and right second molar (crown complete, root 50% formed).

The size of the bones and the extent of dental calcification suggest an age at death of about 10 years.

C-1, General: A small quantity of human remains was recovered from sifted soil. These bones apparently originate from the other identified individuals within C-1. They consist of a right temporal, a manubrium, a fragment from an adult acetabulum, and a very eroded femoral head. Teeth include one each of all maxillary teeth except the left incisors. Also present are the mandibular right first premolar, mandibular left and right first molars, and mandibular left and right second molars.

SUMMARY.—Analysis of all human remains recovered from tomb C-1 suggests that at least eight individuals are present. Among these, the context of two young females, aged approximately 17 to 19 years (E-2) and 15 years (E-5), suggested to Doyon (pers. comm., 1988) that they represent high-status individuals. The remaining six individuals consist of a female aged about 15 to 16 years (E-1), a 23- to 26-year-old adult of undetermined sex (E-3), a 22- to 26-year-old adult of undetermined sex (E-4), two adults of undetermined sex (S-1, S-2), and a child (S-4) of about 10 years of age.

INVENTORY.—This tomb was 15.1 m deep and about 56.5 m³ in volume. Thirty-two groups of bones were available for analysis.

C-2, E-1 (sacrifice): Bones present include fragments from all long bones; the right scapula; cranium; both sides of the mandible; right innominate; both patellae; four thoracic vertebrae; one lumbar vertebra; sacrum; both hand naviculars; right lunate; right triquetrum; right greater multangular; right lesser multangular; right capitate; right hamate; all metacarpals except the left fifth metacarpal; seven proximal hand phalanges; one middle hand phalanx; right calcaneus; both tali; both cuboids; both foot naviculars; right first cuneiform; both second cuneiforms; left third cuneiform; left and right first, second, and third metatarsals; left fourth metatarsal; one foot phalanx; and eight ribs.

Teeth present include all right maxillary teeth, the left maxillary incisors, canine, and second and third molars, and all mandibular teeth.

Epiphyses are united on the proximal femur, distal ulna, distal radius, and the head of the humerus and are not united on the distal femur and proximal fibula. The third molars show completely formed crowns, but the roots are only about 75% formed. These data suggest an age at death of about 16 to 17 years.

A wide sciatic notch and elevated auricular area strongly suggest female sex for this individual.

A left humerus length of 27.8 cm suggests a living stature of about 151 cm (4 ft, 11.5 in) using various stature equations of Trotter (Ubelaker, 1989:61).

C-2, E-2 (sacrifice): Only fragments of the cranial vault, left maxilla, and mandible are present. All teeth are present. Extra teeth belonging to a second adult also are present and include the maxillary canines, maxillary right first premolar, maxillary right first and second molars, maxillary left third molar, mandibular canines, mandibular right first premolar, and all six mandibular molars.

The extent of dental attrition suggests an age at death of between 22 and 25 years. No reliable estimate of sex or stature can be made.

C-2, E-3 (sacrifice): Bones present consist of the right humerus, both radii, both ulnae, left femur, right tibia, one fragmentary fibula, left clavicle, left scapula, both temporals, right maxilla, both sides of the mandible, left patella, first cervical vertebra, four other cervical vertebrae, right calcaneus, right talus, both cuboids, right foot navicular, right first metatarsal, all five left metatarsals, left distal first foot phalanx, two left ribs, and one right rib.

Teeth present include all maxillary teeth and all mandibular teeth except the left second premolar and left second molar.

The small size of the bones suggests likely female sex. The extent of dental formation of the third molars (maxillary roots 75% formed, mandibular roots 50% formed) suggests an age at

death of between 16 and 18 years. No estimate of stature can be made.

The left femur shows extreme platymery on the proximal end, with an anterior-posterior diameter of 18 mm and a medial-lateral diameter of 29 mm.

C-2, E-4 (sacrifice): Bones present consist of the left humerus, left femur, right innominate, both patellae, two cervical vertebrae, five thoracic vertebrae, two lumbar vertebrae, left calcaneus, left talus, left second cuneiform, and ribs. The bones are nearly of adult size, but the ischium is not united to the ilium, and the epiphysis for the iliac crest is separate. The epiphysis for the proximal end of the humerus is partially united and small. These data suggest the remains originate from a female of between probably 15 and 17 years of age. No teeth are present.

C-2, E-5 (sacrifice): Bones present consist of the distal end of a tibia, distal femoral epiphysis, fragments of a fibula, left temporal, left calcaneus, and a right talus. Lack of union of the distal femoral epiphysis and a humeral head diameter of 37 mm suggest the remains represent a female between the ages of 14 and 17 years.

C-2, E-6 (sacrifice): Bones present consist of both femora; both tibiae; both fibulae; both scapulae; left innominate; both patellae; four cervical vertebrae; five thoracic and five lumbar vertebrae; both calcanei; both tali; both cuboids; both foot naviculars; three right cuneiforms; both first, second, and fifth metatarsals; two left first foot phalanges; six other foot phalanges; two middle foot phalanges; one distal foot phalanx; four other distal foot phalanges; and several ribs.

The right innominate shows a deep preauricular sulcus and other strong indications of female sex.

The epiphysis for the iliac crest is not united, although the bones are of adult size. The proximal right tibia shows recent epiphyseal union. This suggests an age at death of between 16 and 19 years.

The maximum length of the right tibia was estimated at 30.2 cm, which suggests a living stature of about 146 cm (4 ft, 9.5 in) using Genovés' regression equation for Mexican females (Ubelaker, 1989:62).

C-2, E-7 (sacrifice): Bones present include both humeri; both radii; both ulnae; both femora; left tibia; one fibula; both temporals; both maxillae; both sides of the mandible; both patellae; first cervical vertebra; two other cervical vertebrae; both hand naviculars; both lunates; left triquetral; one pisiform; both lesser multangulars; left capitate; right hamate; left first, second, third, and fourth metacarpals; right third and fifth metacarpals; four proximal hand phalanges; two middle hand phalanges; left calcaneus; left talus; both foot naviculars; right second and third cuneiforms; five left metatarsals; two proximal foot phalanges; and three distal foot phalanges.

All teeth are present. The right mandibular third molar is impacted. The right maxillary third molar shows a root 90% formed.

The appearance of the bones and the extent of dental formation suggest an age at death of about 20 years. No reliable estimate of sex can be made. The estimated length of the left tibia (32.4 cm) suggests a stature of about 157 cm using the male formula or 152 cm using the female formulae of Genovés (Ubelaker 1989:62); an average estimate is about 155 cm (5 ft, 1 in).

The right radius shows a Colles fracture near the distal end, with considerable destruction of the distal articular surface (Figure 3). The right femur displays considerable platymery.

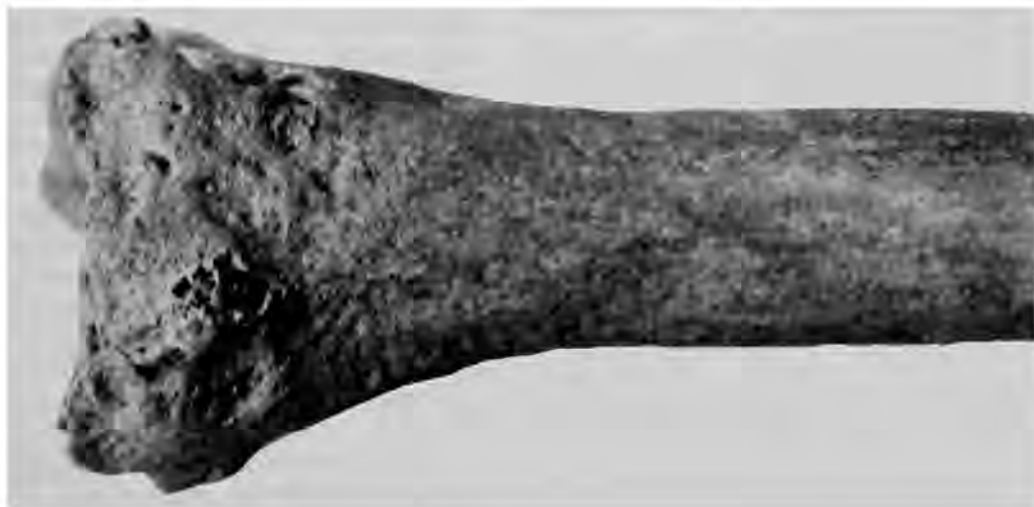

FIGURE 3.—Colles fracture of distal right radius of 20-year-old adult, sex undetermined, C-2, E-7.

C-2, E-8 (sacrifice): Bones present consist of both humeri, right radius, both ulnae, both femora, right tibia, one fragmentary fibula, right clavicle, both scapulae, both temporals, both maxillae, both sides of the mandible, both innominates, one cervical vertebra, seven thoracic vertebrae, three lumbar, one sacrum, one right hand navicular, one right lunate, one right lesser multangular, one right capitate, one right hamate, one left second metacarpal, one right third metacarpal, one right fourth and one right fifth metacarpal, four proximal hand phalanges, three middle hand phalanges, one distal hand phalanx, one left first cuneiform, and several rib fragments. All teeth are present.

Various features of the innominates strongly indicate female sex.

The extent of dental attrition and other aging data suggest an age at death of between 25 and 30 years.

Maximum lengths of the right ulna (22.0 cm) and the right radius (20.4 cm) suggest a living stature of about 150 cm (4 ft, 11 in) using combined white female and black female formulae of Trotter (Ubelaker 1989:61).

A well-remodeled healed fracture is located on the midshaft of the left radius.

C-2, E-9 (sacrifice): Bones present include all of the long bones except the right tibia and right clavicle. Also present are the scapulae, temporals, maxillae, both sides of the mandible, innominates, patellae, first and second cervical vertebrae, two other cervical vertebrae, four thoracic vertebrae, two lumbar vertebrae, sacrum, all carpal bones except the pisiforms and right lesser multangular, all metacarpals, four proximal hand phalanges, seven middle hand phalanges, six distal hand phalanges, both calcanei, both tali, left cuboid, both foot naviculars, left first cuneiform, both second cuneiforms, right third cuneiform, both second metatarsals, left third metatarsal, both fifth metatarsals, both proximal first foot phalanges, six other proximal foot phalanges, two middle foot phalanges, three distal foot phalanges, and several ribs.

All teeth are present except the maxillary left central incisor.

Various features on the innominates as well as the morphology of the other bones strongly indicate female sex.

The extent of dental attrition suggests an age at death of between 21 and 24 years.

Maximum length of the left tibia (31.6 cm) suggests a living stature of about 150 cm (4 ft, 11 in) using the formula of Genovés for Mexican females (Ubelaker, 1989:62).

C-2, E-10 (sacrifice): Bones present consist of the right humerus, right femur, right tibia, one fibula, right scapula, mandible, and left pubis. All teeth are present. Teeth of a second adult individual also are present. These consist of all maxillary teeth except the left central incisor and all mandibular teeth except the canines, right second molar, and third molars. The third molars of the main individual show only initial root formation, suggesting an age at death of about 13 years; no estimate of age can be made for the second individual. No reliable estimate of sex can be made for either individual.

C-2, E-11 (sacrifice): Bones present consist of one left and one right humerus, one left and one right radius, one left and one right ulna, one tibia, one left and one right clavicle, one left and one right scapula, one left and one right temporal, one left and one right maxilla, both sides of the mandible, seven cervical vertebrae, six thoracic vertebrae, one left and one right hand navicular, both lunates, one left and one right pisiform, one left greater multangular, one right capitate, one right hamate, 10 metacarpals, 12 proximal hand phalanges, eight middle hand phalanges, four distal hand phalanges, one left calcaneus, one left and one right talus, one left first and one left fifth metatarsal, two foot phalanges, and 14 ribs. A second individual is probably indicated by the 12 proximal hand phalanges (normal number for one person is 10).

All teeth of one individual are present except the maxillary right canine and left first molar, missing postmortem, and the mandibular second molars, missing antemortem.

The size of the bones indicates female sex. The extent of dental attrition suggests an age at death of between 23 and 26 years.

Maximum length of the right radius (21.0 cm) suggests a living stature of about 153 cm (5 ft, 0 in) using the formulae for females of Trotter (Ubelaker, 1989:61).

C-2, E-12 (sacrifice): Bones present consist of the left humerus, both femora, both tibiae, right clavicle, both scapulae, left temporal, both maxillae, both sides of the mandible, first cervical vertebra, right calcaneus, right talus, and six ribs.

All maxillary teeth are present except the left incisors. Mandibular teeth present consist only of the right first molar, left premolars, and left molars. The mandibular left third molar is not yet erupted. The roots of the maxillary third molars are about 50% formed.

The extent of root formation on the maxillary third molars suggests an age at death of about 16 years. No estimate of sex can be made.

C-2, E-13 (sacrifice): Bones present consist of both humeri, left radius, left ulna, left femur, both tibiae, both clavicles, left scapula, both temporals, both maxillae, both sides of the mandible, both innominates, three cervicals, four thoracics, three lumbar, and eight ribs.

There are seven deciduous and 11 permanent teeth present. The deciduous teeth are the maxillary right canine, all four maxillary molars, and the mandibular first molars. All permanent teeth except the mandibular left lateral incisor are present, but only the four maxillary incisors, two maxillary first molars, mandibular central incisors, mandibular right lateral incisor, and mandibular first molars have erupted. The extent of formation of the permanent teeth suggests an age at death of about nine years.

C-2, E-14 (sacrifice): These immature remains consist of the right humerus, right radius, right ulna, left femur, right clavicle, left scapula, right temporal, both maxillae, both sides of the mandible, left ilium, six ribs, six carpal and tarsal bones, and three vertebrae. Ten deciduous teeth and all permanent

teeth are present. The deciduous teeth are the maxillary right lateral incisor, right maxillary canine, all four maxillary molars, the mandibular left canine, the mandibular first molars, and the mandibular right second molar.

The extent of dental formation suggests an age at death of about eight years.

C-2, E-15 (sacrifice): Bones present consist of both humeri; right radius; both ulnae; both femora; left tibia; fragments of at least one right fibula; both scapulae; both temporals; both maxillae; both sides of the mandible; one gladiolus of the sternum; both innominates; both patellae; first and second cervical vertebrae; three other cervical vertebrae; seven thoracic vertebrae; five lumbar vertebrae; right-hand navicular; both lunates; right triquetral; one pisiform; right greater multangular; right lesser multangular; both hamates; all right metacarpals; first four left metacarpals; 11 proximal hand phalanges; three middle hand phalanges; one distal hand phalanx; both calcanei; both tali; left cuboid; both foot naviculars; left second cuneiform; right third cuneiform; all left metatarsals; first, second, fourth, and fifth right metatarsals; two first proximal foot phalanges; two other middle foot phalanges; two first distal foot phalanges; five distal foot phalanges; and six ribs.

All permanent teeth are present except the maxillary right second molar and the maxillary left second premolar.

The morphology of the left innominate as well as the size and appearance of the other bones suggests male sex.

The extent of dental attrition as well as other features suggests an age at death of between 22 and 25 years.

The maximum length of the right ulna (24.0 cm) suggests a living stature of about 160 cm (5 ft, 3 in) using Trotter's formula for Mexican males (Ubelaker, 1989:62).

C-2, E-16 (sacrifice): Bones present include all long bones except the left clavicle. Also present are the scapulae, temporals, both maxillae, both sides of the mandible, ilia, ischia, pubes, 22 ribs, a total of 28 carpals and tarsals, and 18 vertebrae. Deciduous maxillary teeth present include the right lateral incisor, the canines, and the molars. Deciduous mandibular teeth include the right central incisor and the four molars. All permanent teeth are present, but only the mandibular right lateral incisor, mandibular first molars, and maxillary left first molar are erupted.

The extent of calcification of the permanent teeth suggests an age at death of about seven years. No estimate of sex can be made reliably.

C-2, E-17 (sacrifice): The bones present are immature and consist of both humeri, both radii, right ulna, both femora, left tibia, left clavicle, left scapula, both ilia, right ischium, left pubis, both patellae, various ribs, a total of 10 carpals and tarsals, and 27 vertebrae. All permanent teeth are present.

The extent of dental calcification suggests an age at death of between 13 and 14 years. No reliable estimate of sex or stature can be made.

C-2, E-19 (principal and companion burials): This numeration refers to multiple burials that had been disturbed by looters

during the excavation. The numbers 19A, 19B, and 19C had been assigned to leg bones of what were originally believed to be three individuals that had not been disturbed by the intruders. The remaining bones were mixed.

C-2, E-19A: Bones present, representing two individuals, include two left femora and one right femur, one left tibia, one fibula, two left patellae, one right patella, one proximal hand phalanx, one proximal first foot phalanx, and one other foot phalanx.

The size and morphology of the bones suggest that one individual is a young female between the ages of 22 and 26 years, and the other is a young male between the ages of 19 and 22 years.

C-2, E-19B: This individual is represented only by the right ulna, both femora, left tibia, right patella, right lunate, right greater multangular, right capitate, left second metacarpal, one proximal hand phalanx, and one distal hand phalanx.

The individual appears to represent a large, young adult male between the ages of 22 and 30 years.

C-2, E-19C: Bones present include a left ulna, left femur, two right tibiae, one fibula, two patellae, left talus, two left naviculars, one right cuneiform, and one right first metatarsal. Most bones appear to represent a young adult male between the ages of 20 and 25 years. One tibia present has a maximum length of 33.5 cm, suggesting a living stature of about 159.4 cm (5 ft, 3 in) using Genovés' formula for Mexican males (Ubelaker, 1989:62).

C-2, E-19ABC, General: Bones labeled in this manner consist of one left humerus; both radii; one left ulna; fragments of a femur, tibia, and fibula; one left innominate; one lumbar vertebra; one right navicular; one left capitate; one left hamate; one left and one right second metacarpal; one left and one right third metacarpal; one right fourth metacarpal; one left fifth metacarpal; 11 proximal hand phalanges; six middle hand phalanges; two distal hand phalanges; one right talus; and one right rib. One left pubis from this bone group shows slight parturition pits on the dorsal surface and appears to represent a 25- to 30-year-old female. One femoral head diameter measures 37 mm, well within the female range.

C-2, E-19, Bones Mixed by Looters: Bones labeled in this manner consist of three left and two right humeri, one left and two right radii, two left ulnae and one right ulna, one right femur, one right tibia, fragments of a fibula, two left and two right clavicles, three left and two right scapulae, three left and three right temporals, three mandibles, one gladiolus, two manubria, one left and one right innominate, two first cervical vertebrae, two second cervical vertebrae, nine other cervical vertebrae, 13 thoracic vertebrae, two lumbar vertebrae, one sacrum, two left naviculars, one right navicular, one right lunate, one left and two right greater multangulars, one left and one right capitate, one right hamate, one left and one right first metacarpal, one left and one right second metacarpal, one right third metacarpal, one right fifth metacarpal, three proximal

hand phalanges, four middle hand phalanges, two distal hand phalanges, one right second metatarsal, and various ribs.

One left pubis is from a male, aged about 28 to 30 years. One right scapula appears to be male, another female. A right radius, right femur, and right ulna show recent epiphyseal union. The head of one left humerus, stained green (apparently from exposure to copper salts), measures 38 mm in diameter and thus probably represents a female. The head of a right humerus, also stained green, measures about 43 mm in diameter, probably indicative of male sex. Three left temporals present appear to represent at least one male and one female.

Twenty teeth are labeled as originating from a "large male with copper." Maxillary teeth include the canines, premolars, first molars, and right second molar. Mandibular teeth include all right teeth, except the right central incisor, and the left second premolar and molars. The teeth represent a young adult between the ages of 22 and 28 years.

Teeth labeled as "extra teeth" and "robbed, mixed," consist of 107 permanent teeth from at least four individuals. These include one complete set of 32 teeth and one set of 31 teeth missing only the mandibular left central incisor. The remaining maxillary teeth consist of two of each incisor, two right canines, two of each right premolar, one right first molar, one right second molar, one left canine, one left first premolar, and one of each left molar. The remaining mandibular teeth are two left and two right lateral incisors, two right canines, one left canine, two left and two right first premolars, two right second premolars, one left second premolar, two right first molars, two right second molars, one right third molar, one left first molar, two left second molars, and one left third molar.

Overall, the dental and skeletal inventory total for E-19 shows that four individuals are represented by the teeth, left humeri, left ulnae, and left femora. These appear to represent two males and two females. The two females are of ages 22 to 26 and 25 to 30 years. The two males are of ages 19 to 22 years and 22 to 30 years.

C-2, E-20 (sacrifice): Bones consist of both humeri, left ulna, both femora, both tibiae, left scapula, left mandible, left and right innominates, 10 thoracic vertebrae, five lumbar, one sacrum, one right navicular, right lunate, right greater multangular, left lesser multangular, right capitate, left second metacarpal, right third metacarpal, four proximal hand phalanges, two middle hand phalanges, and four ribs.

Maxillary teeth present include the right incisors, right canine, right first premolar, right first molar, and left first and third molars. Mandibular teeth present are the right incisors, right canine, right and left molars, left lateral incisor, and left premolars.

The extent of dental formation suggests an age at death of between 17 and 20 years.

C-2, Cranium 1 (severed head): An isolated cranium was found with nonhuman scapula at the tomb entrance. Bones present are a right frontal and other cranial fragments. The bones approach adult size but are very gracile. They represent

an individual between the ages of 12 and 25 years. No teeth are present.

C-2, Section 1, General: These few bone fragments were recovered from the general area of C-2, section 1, and could represent E-6, E-7, E-8, or E-11. Bones present are two distal hand phalanges, three (2-5) proximal foot phalanges, and one middle foot phalanx. The bones are of adult size, but no estimate of sex or age can be made.

C-2, Section 2, General: The following bone fragments and teeth were found within C-2, section 2, and could relate to E-1, E-3, E-4, E-5, E-6, E-7, or E-8. Bones present are a right fibula, right scapula, right maxilla, right patella, five thoracic vertebrae, five proximal and two middle hand phalanges, one right fourth metatarsal, one right fifth metatarsal, one proximal first foot phalanx, eight (2-5) proximal foot phalanges, and three ribs. Only three teeth are present: one maxillary third molar with initial root formation and the first and second right mandibular premolars.

C-2, Section 3, General: The following immature fragmentary remains were recovered from C-2, section 3; ulna, right scapula, a total of 12 carpals and tarsals, and one vertebra. Teeth present include one deciduous right maxillary lateral incisor with occlusal dentin exposure, the permanent central right maxillary incisor, and the maxillary right first molar (root 25% formed). These bones probably relate to E-14 and/or E-16.

C-2, Section 4, General: Bones mixed from this sector include one left capitate, one proximal hand phalanx, two middle hand phalanges, one distal hand phalanx, and one right first metatarsal. Permanent teeth present are the maxillary right incisors. An immature left pubis (child) also is present.

C-2, Section 5, General: The following permanent teeth were recovered from this feature: the maxillary left second molar, mandibular right incisors, mandibular first premolar, and mandibular second molar. The mandibular second molar shows 80% root formation.

C-2, Section 6, General: Adult bones from this sector include the right humerus, right ulna, left temporal, right maxilla, left innominate, left patella, one (3-7) cervical vertebra, right triquetral, left fourth metacarpal, two proximal hand phalanges, one proximal first foot phalanx, and one (2-5) proximal foot phalanx. Permanent teeth present include all incisors, all canines, the maxillary right premolars, mandibular right premolars, all four first molars, maxillary right second molar, and maxillary right third molar. Many of these remains likely represent the same individual as E-5.

C-2, General: These bones consist of two left humeri and one right humerus; two left and two right radii; two left and two right ulnae; one right femur; two left tibiae; one right patella; one left navicular; one left lunate; one left capitate; one left hamate; two left first metacarpals and one right first metacarpal; one left second metacarpal; one right third metacarpal; one left fifth metacarpal; four proximal hand phalanges; one middle hand phalanx; two right calcanei; one left and two right tali; one right cuboid; two left naviculars; one right first cuneiform;

two right second cuneiforms; two left third cuneiforms; one each of the left and right first, second, third, and fourth metatarsals; one right fifth metatarsal; one proximal first foot phalanx; three distal foot phalanges; and various cranial fragments.

Teeth in this category include one each of all permanent teeth except the maxillary left central incisor, the mandibular right first premolar, the mandibular right third molar, and the mandibular left central incisor.

SUMMARY.—At least 21 individuals are represented by human remains from C-2. Burials interpreted by Doyon (pers. comm., 1988) as representing principal and companion burials consist of four individuals, an adult male likely between the ages of 19 and 22 years, a male between ages 22 and 30, a female aged 22 to 26, and a female aged 25 to 30.

Interpretation of the remaining individuals is complicated by the likely commingling within the tomb of remains of different individuals. Careful inventory and sorting of the remains by age, sex, and bone morphology suggest that at least 17 additional individuals are present. These individuals consist of a 16- to 17-year-old female (E-1), a 22- to 25-year-old adult of undetermined sex (E-2), a 15- to 17-year-old female (E-4), a 14- to 17-year-old female (E-5), a 16- to 19-year-old female (E-6), a 25- to 30-year-old female (E-8), a 21- to 24-year-old female (E-9), a 13-year-old of undetermined sex (E-10), a 23- to 26-year-old female (E-11), a 16-year-old of undetermined sex (E-12), a nine-year-old (E-13), an eight-year-old (E-14), a 22- to 25-year-old male (E-15), a seven-year-old (E-16), a 13- to 14-year-old (E-17), a 17- to 20-year-old of undetermined sex (E-20), and the cranium of a 12- to 25-year-old. The remains in E-3 and E-7 may relate to other burials in tomb C-2 (see "Biological Analysis and Interpretation of Human Remains," below).

TOMB P-1

INVENTORY.—This tomb was almost completely disturbed by looters during excavation. It measured 14.2 m deep and about 51.3 m³ in volume. Thirteen groups of remains were available for analysis.

P-1, E-1 (sacrifice): Originally, this was identified as a complete skeleton, but it was disturbed by looters. Bones present are a fragmentary left scapula, both temporals, right maxilla, right mandible, one cervical vertebra, and several ribs. All permanent teeth are present except the maxillary right second molar, maxillary left canine, mandibular left central incisor, and mandibular left second premolar.

No estimate of sex can be made, but the extent of dental attrition suggests an age at death of 18 to 21 years.

P-1, E-2 (sacrifice): Although E-2 was recognized during excavation, no remains were recovered specifically from this feature.

P-1, E-3 (sacrifice): This feature was disturbed, and remains originating from E-1 and E-2 possibly are mixed in. The following fragmentary remains are present: both humeri, left radius, left ulna, fibula, scapula, nine thoracic vertebrae, one

lumbar, one right third metacarpal, both fourth and fifth metacarpals, three proximal hand phalanges, and six middle hand phalanges.

Adult teeth present consist of the maxillary lateral incisors and right canine and the mandibular right lateral incisor, right premolars, and right first molar.

The skeleton appears to represent a young adult of undetermined sex, 18 to 25 years of age.

Three middle hand phalanges of a child, six to nine years of age, also are present.

No evidence of disease was noted.

P-1, E-4 (sacrifice): This originally complete skeleton was disturbed by looters. Very fragmentary remains of a right humerus and an unside femur, fibula, and patella are present. The remains are of young adult size (perhaps between 20 and 24 years of age). Sex cannot be estimated reliably.

P-1, E-5 (sacrifice): The bones recovered from this feature generally relate to a single individual but were disturbed by looters. A large quantity of very fragmentary bones are present. Recognizable fragments include one left and one right humerus, one left radius, one left and one right ulna, one left femur and two right femora, two tibiae, one right fibula, one left and one right clavicle, one right scapula and one other scapula, three left and two right temporals, two mandibles, one left and one other innominate, one left and one other patella, one (3-7) cervical vertebra, one thoracic vertebra, five lumbar vertebrae, one left hand navicular, one right hamate, one left first metacarpal, one left and one right third metacarpal, one right fourth and one right fifth metacarpal, two proximal hand phalanges, four middle hand phalanges, two distal hand phalanges, one left calcaneus, one left and one right talus, one cuboid, one left first metatarsal, one left and one right fourth metatarsal, one left and one right fifth metatarsal, two proximal first foot phalanges, two (2-5) proximal foot phalanges, one distal first foot phalanx, and fragments of ribs.

One left pubis within these remains shows characteristics of a female between the ages of 27 and 32 years. Other bones appear to originate from a large male. An ununited distal femoral epiphysis of adult size indicates that an adolescent also is represented.

A large number of teeth are present, including three complete sets of permanent teeth. A fourth set is complete except for the mandibular left central incisor, mandibular left canine, mandibular left second premolar, mandibular right second premolar, and maxillary left second premolar. Additional fully formed permanent teeth include the maxillary right and left lateral incisors, left central incisor, right first premolar, right first molar, both third molars, and the mandibular right second molar.

Twenty-five additional developing permanent teeth are present. Maxillary teeth present are the right incisors, the left central incisor, both canines, all four premolars, the four second and third molars, and the left first molar. Mandibular teeth present are the left canine and all premolars and molars.

Deciduous teeth present consist of the following maxillary teeth: two right lateral incisors, one right canine, one first and one second right molar, one left lateral incisor, and two first and two second left molars. Mandibular teeth present include one right and one left canine, one right first molar, two right second molars, and two first and two second left molars. The deciduous teeth all originate from at least two children between the ages of six and seven years.

P-1, E-6 (sacrifice): This isolated cranium and mandible was identified in the field after other aspects of this feature were disturbed by looters. Analysis revealed cranial fragments, a left temporal, and both sides of the mandible. The bones were of adult size. A small mastoid process on the left temporal suggests female sex.

Maxillary teeth present are only the central incisors and right canine. Mandibular teeth are the right lateral incisor, both first premolars, the right second premolar, the right first and second molars, and the left second molar. The extent of dental wear suggests an age at death of about 30 years.

P-1, E-7 (severed head): An isolated cranium, mandible, and clavicle were recovered from this feature. Analysis revealed a right clavicle, both temporals, both maxillae, both sides of the mandible, first and second cervical vertebrae, and three other cervical vertebrae. A fragment of the acromial process of a right scapula also is present. All 32 permanent teeth are present.

The size and robusticity of the remains indicate male sex.

The extent of dental eruption, dental attrition, and epiphyseal union indicates an age at death of between 20 and 23 years.

No evidence of disease was noted, but a slight incision, 4 mm in length, is located on the dorsal surface of one of the lower cervical vertebrae. The presence of soil within the incision indicates it was not of recent origin. The fine nature of the incision suggests it was made with a sharp blade.

P-1, E-8 (principal and companion burials): Originally, this feature consisted of multiple complete skeletons with associated high-status artifacts. The principal burial and companion burials were represented but were subsequently disturbed and mixed by looters. Analysis revealed the presence of two left humeri and one right humerus, two left and two right radii, two left and three right ulnae, one left and one right femur, one right tibia, one fragmentary fibula, one left and one right clavicle, one left and one right scapula, two left and two right temporals, one right maxilla, both sides of the mandible, two gladioli of the sternum, one manubrium, one left and one right innominate, one second cervical vertebra, three (3-7) cervical vertebrae, three thoracic vertebrae, five lumbar vertebrae, one sacrum, one right hand navicular, one left lunate, one right lesser multangular, one right capitate, one right hamate, one left first metacarpal, one right second metacarpal, two right third metacarpals, one left fourth metacarpal, one right fifth metacarpal, four proximal hand phalanges, three middle hand phalanges, one distal hand phalanx, one left calcaneus, one left talus, and fragments from nine ribs. Copper stains are located on the left scapula, one right temporal, and the left mandible.

Two complete adult permanent dentitions are present, missing only one left mandibular central incisor.

Bone morphology suggests at least one male and one female are present. Both are between 20 and 24 years of age.

No evidence of disease was noted.

P-1, E-9 (sacrifice): This feature consists of a distinct, partially disturbed skeletal assemblage. Bones present include one right humerus, one left radius, and one (3-7) cervical vertebra. Teeth present include all maxillary teeth from two adults except for one left central incisor. Mandibular teeth present are one right canine, the 12 molars, and one right first premolar. The four deciduous second molars from one immature individual also are present.

One adult right humeral head measures 35 mm in diameter, suggesting female sex.

The extent of dental formation suggests the adults are of ages 16 to 19 and 21 to 26 years.

P-1, Shelf: This feature was originally identified as likely representing a complete, articulated skeleton, but it was disturbed by looters. Analysis revealed the following very fragmentary bones: right radius, right ulna, left mandible, three (3-7) cervical vertebrae, one first metacarpal, one right second metacarpal, and one proximal hand phalanx. The following maxillary teeth were identified: both lateral incisors, right canine, right first premolar, and right second molar.

No estimate of sex can be made. The extent of dental attrition suggests an age at death between 18 and 25 years. No disease was noted. Some of these remains may have originated from E-3.

P-1, Cranium 1 (severed head): This cranium, with articulated mandible and cervical vertebrae, was found at the entrance to the tomb with an associated tibia and fibula. Bones present are cranial fragments, left tibia, fibula fragments, both temporals, both maxillae, both sides of the mandible, and the first and second cervical vertebrae. All permanent teeth are present except the maxillary central incisors.

Cranial morphology suggests male sex.

The extent of dental attrition indicates an age at death of about 20 years.

No evidence of disease is present, but the inferior surface of the second cervical vertebra has been sheared. The affected surface is very planar along all of the body, with soil embedded within the exposed trabeculae (Figures 4, 5). No fine cut marks are present. The alteration apparently was produced by a large blade applied with considerable force.

P-1, Cranium 2 (severed head): This cranium, with articulated mandible and cervical vertebrae, also was found at the tomb entrance. Bones present are both temporals, both maxillae, both sides of the mandible, and the first three cervical vertebrae. All 32 permanent teeth are present.

Morphology of the cranium indicates male sex. The extent of dental attrition (Figure 6) and other factors indicate an age at death of 25 to 30 years.

No cut marks were noted, however, an oval-shaped lesion is present on the right medial surface of the mandible just above

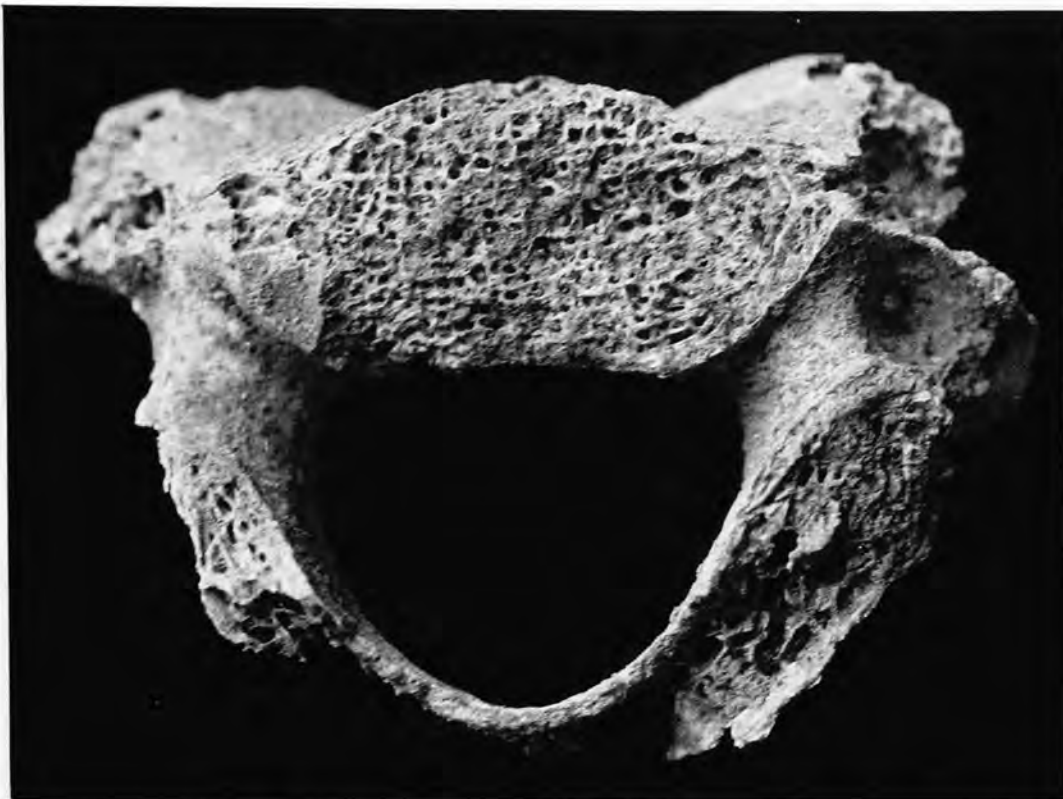

FIGURE 4.—Sheared surface of second cervical vertebra, P-1, Cranium 1, inferior surface.



FIGURE 5.—Sheared surface of second cervical vertebra, P-1, Cranium 1, ventral surface.

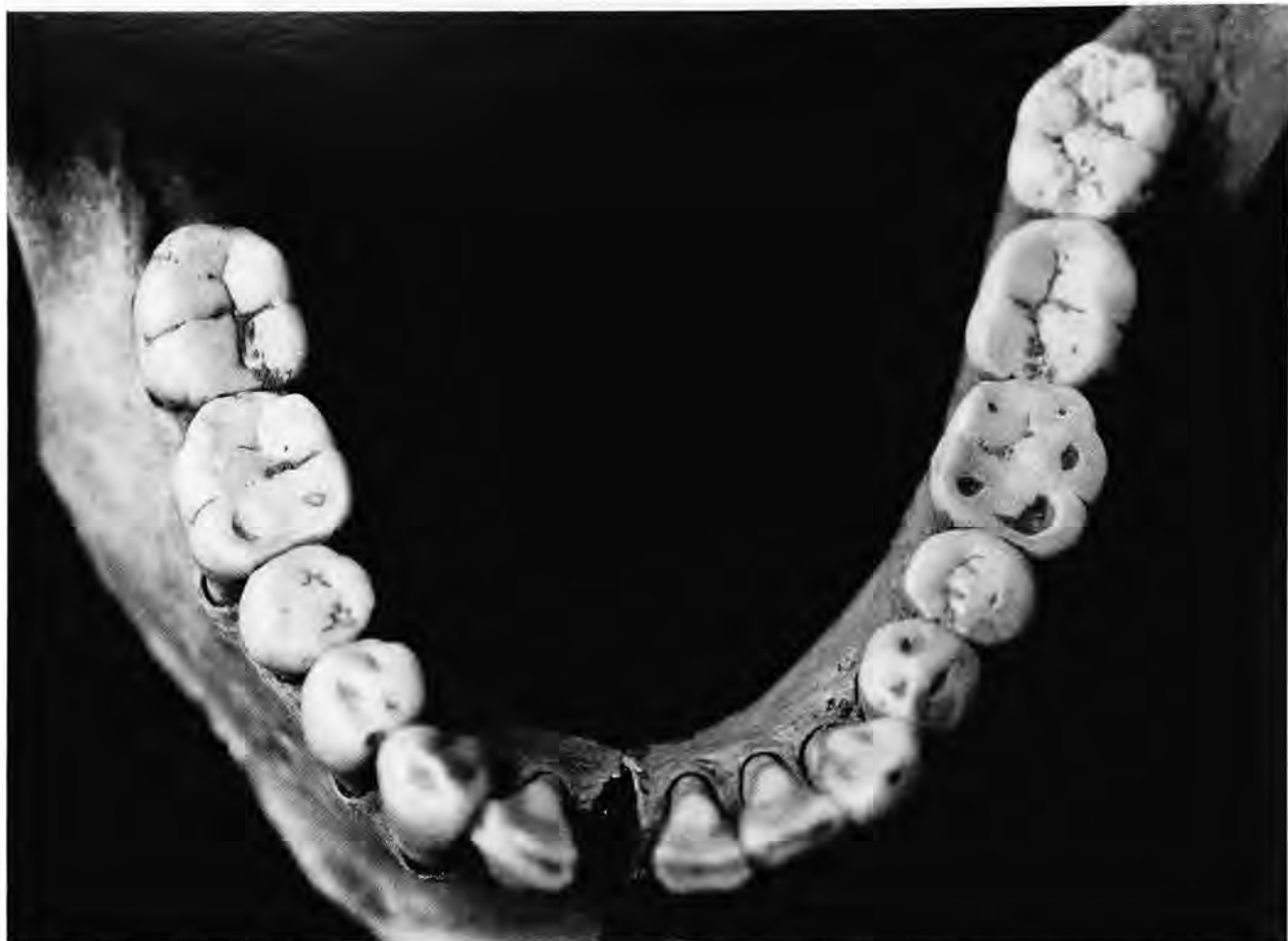

FIGURE 6.—Occlusal surfaces of mandibular teeth, P-1, Cranium 2.

the lower margin. Some reactive bone is present at the superior surface. The depression measures 7 mm × 13 mm × 3 mm deep. The lesion is smooth-walled and opens internally.

P-1, Level 3: This isolated mandible was found at the tomb entrance. In addition to both sides of the mandible, a left tibia is present. All mandibular teeth except the central and right lateral incisors are present.

No estimate of sex can be made. The extent of dental attrition indicates an age at death of between 25 and 30 years.

Interproximal grooves are located at the cervical junctions of the distal surface of the mandibular right first premolar and the mesial surface of the contiguous second premolar (Figure 7). The grooves are 2 mm and 1 mm wide, respectively.

P-1-H: This feature consists of general mixed bone disturbed by looters. Bones present are a left humerus, left scapula, left and right temporal, left maxilla, left mandible, left patella, second cervical vertebra, and one other (3-7) cervical vertebra.

All maxillary teeth from one individual are present. Additional maxillary teeth are the right incisors, left lateral incisor, right canine, right molars, and left third molar. Mandibular teeth present are the right incisors, both canines, both first premolars, both left molars, and the second and third right molars. An additional mandibular third molar is present with 25% root formation.

One temporal shows a very large mastoid process, indicating male sex. This left temporal also is copper stained.

SUMMARY.—Analysis suggests that at least 20 persons are represented by the human remains originating in Tomb P-1. The principal and companion burials (E-8) consist of a male and female, both likely between the ages of 20 and 24 years. The remaining 18 individuals include an 18- to 21-year-old of undetermined sex (E-1), an 18- to 25-year-old of undetermined sex (E-3), a young adult of undetermined sex (E-4), a 27- to 32-year-old female (E-5), a six- to seven-year-old child (E-5), a female of about 30 years (E-6), a 20- to 23-year-old male (E-7), a

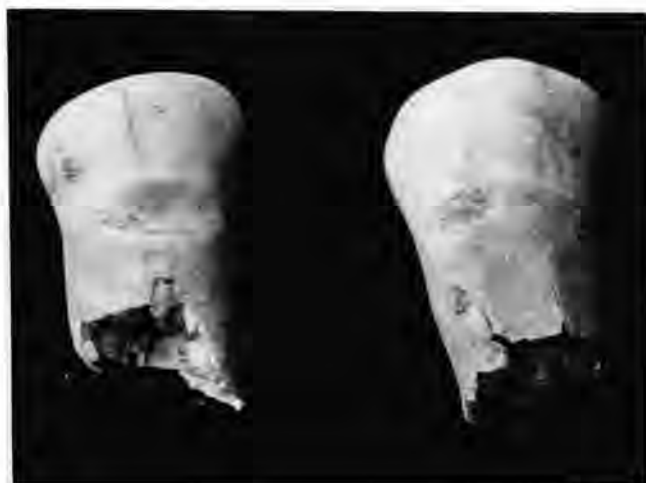

FIGURE 7.—Interproximal grooves on mandibular right first premolar (distal surface) and second premolar (mesial surface), P-1, Level 3.

16- to 19-year-old of undetermined sex (E-9), a 21- to 26-year-old of undetermined sex (E-9), a 20-year-old male (severed skull number 1), a 25- to 30-year-old male (severed skull number 2), and a mandible from a 25- to 30-year-old of undetermined sex (Level 3).

The minimum of 20 individuals was suggested by analysis of both permanent and deciduous teeth present (Tables 1, 2). The dental data suggest the presence of at least two additional children and four additional adults.

TOMB P-2

INVENTORY.—Human remains from this tomb originate from three individuals, an adolescent and two children. Bones from all three individuals were commingled. Individual E numbers were assigned but are difficult to assess. All burials in this tomb were assigned high status by Doyon (pers. comm., 1988). The tomb measured 12.5 m deep and about 27.2 m³ in volume. Four groups of remains were available for analysis.

Adolescent: Bones of the adolescent consist of the left humerus; left radius; fragments of an ulna; right femur; right scapula; left temporal; both innominates; first and second cervical vertebrae; two thoracic vertebrae; two lumbar vertebrae; sacrum; one left lunate; left triquetral; left capitate; left hamate; left second, third, fourth, and fifth metacarpals; four proximal, two middle, and two distal hand phalanges; and several ribs.

Teeth of the adolescent consist of the permanent maxillary right lateral incisor, right canine, right premolars, right first molar, and first and second left molars. Permanent mandibular teeth are the right second premolar, first and second right molars, and first and second left molars.

The extent of dental formation, bone size, and epiphyseal union suggest an age at death of between 17 and 19 years.

The appearance of the ilium and other bones suggests female sex.

The mandibular right third molar is peg-shaped and unerupted. In addition, a left orbit shows active porosity (cribra orbitalia).

Children: Bones of the two children consist of one left and one right humerus, one left and one right radius, two left and two right clavicles, two left and two right scapulae, one left temporal and two right temporals, two left maxillae and one right maxilla, two left mandibles and one right mandible, one right ilium, one sternum, three left and five right ribs, and 23 centra and six transverse processes of the vertebrae.

The younger child is represented by the following deciduous teeth: maxillary lateral incisors, canines, and molars, and mandibular canines and molars. Permanent teeth include an unerupted first molar with about 25% root formation, a canine with initial root formation, and a second molar with 50% crown formation. These data suggest an age at death of about five years.

Erupted teeth of the older child are the four deciduous maxillary and mandibular first and second left molars, the permanent maxillary right first molar, and the mandibular right first molars. Other permanent teeth are present, but they are neither erupted nor fully formed. The extent of dental development suggests an age at death of about 7.5 years.

TABLE 1.—Permanent teeth recovered from tomb P-1, La Florida.

Maxillary teeth	Number present	Mandibular teeth	Number present
Right I1	15	Right I1	11
Right I2	18	Right I2	13
Right C	18	Right C	13
Right PM1	16	Right PM1	15
Right PM2	14	Right PM2	13
Right M1	15	Right M1	17
Right M2	15	Right M2	17
Right M3	16	Right M3	16
Left I1	14	Left I1	7
Left I2	17	Left I2	11
Left C	13	Left C	13
Left PM1	14	Left PM1	15
Left PM2	13	Left PM2	10
Left M1	14	Left M1	14
Left M2	14	Left M2	16
Left M3	16	Left M3	14

TABLE 2.—Deciduous teeth recovered from tomb P-1, La Florida.

Maxillary teeth	Number present	Mandibular teeth	Number present
Right I1	0	Right I1	0
Right I2	2	Right I2	0
Right C	1	Right C	1
Right M1	1	Right M1	1
Right M2	2	Right M2	3
Left I1	0	Left I1	0
Left I2	1	Left I2	0
Left C	0	Left C	1
Left M1	2	Left M1	2
Left M2	3	Left M2	3

TOMB P-3

INVENTORY.—This tomb was 14.9 m deep and about 59.7 m³ in volume. Thirteen groups of remains were available for analysis.

P-3, E-1 (sacrifice): Bones labeled as E-1 consist of two humeri, two radii, two femora, two tibiae, two fibulae, one left ulna, one right clavicle, two temporals, both sides of the mandible, one gladiolus, one left innominate, one left patella, two right patellae, one cervical vertebra, two calcanei, two tali, two foot naviculars, six cuneiforms, one right cuboid, one right first metatarsal, eight second through fifth metatarsals, one proximal first foot phalanx, five other proximal foot phalanges, four middle foot phalanges, one distal first foot phalanx, four other distal foot phalanges, and fragments of ribs.

All permanent teeth from one individual are present except the maxillary central incisors, the maxillary left third molar, the mandibular right third molar, and the mandibular left first molar. The maxillary third molars are not completely erupted and display roots only 80% formed.

A right patella of a second individual is present.

The extent of epiphyseal union and dental formation suggests the age at death likely was between 17 and 18 years. The appearance of the pelvis and other bones suggests female sex.

P-3, E-2 (sacrifice): Two individuals are represented in this group. Bones present consist of one left and one right humerus, one right radius, one left ulna and two right ulnae, two left and two right femora, two left and two right tibiae, one left fibula, one left and one right scapula, one right temporal, one right mandible, one left and one right innominate, one left and one right patella, one right hand navicular, one right greater multangular, one right first metacarpal, one left second metacarpal, one right third metacarpal, two proximal hand phalanges, one distal hand phalanx, one left calcaneus and two right calcanei, two left and two right tali, two left and two right cuboids, two left and two right foot naviculars, one left and one right first cuneiform, two left and one right second cuneiforms, two left and two right first metatarsals, two left and one right second metatarsals, two left and one right third metatarsals, one left and two right fourth metatarsals, two left and two right fifth metatarsals, two first proximal foot phalanges, 10 other proximal foot phalanges, seven middle foot phalanges, two distal first foot phalanges, and two other distal foot phalanges.

Teeth representing E-2 include all 16 maxillary teeth, all right mandibular teeth, and the following left mandibular teeth: canine, both premolars, and three molars. The third molars are fully formed but are not completely erupted.

The extent of dental formation, dental eruption, and epiphyseal closure suggests the age at death was likely between 17 and 18 years for the individual represented by the most bones.

The right innominate shows a wide sciatic notch, deep preauricular sulcus, and irregular auricular area. These features, plus the size and morphology of other bones, indicate female sex for the individual represented by the most bones.

The left maxillary lateral incisor is peg-shaped.

P-3, E-3 and E-4 (sacrifices): Apparently, bone groups recognized as E-3 and E-4 were commingled. Analysis indicates that at least three individuals are represented by some bones. The following adult bones are present: one left and one right humerus, one right radius, one left ulna, two left and two right femora, three left and two right tibiae, one fibula, one left and one right scapula, two left and two right temporals, one left and one right maxilla, two left and two right mandibles, innominate fragments, two first cervical vertebrae, two second cervical vertebrae, two other cervical vertebrae, 10 thoracic vertebrae, three lumbar vertebrae, one sacrum, one left and one right lunate, one right triquetral, one left and one right lesser multangular, one right capitate, one right hamate, one right first metacarpal, one left second metacarpal, one right third metacarpal, one left fourth metacarpal, two proximal hand phalanges, one left and two right calcanei, two left and two right tali, two left cuboids and one right cuboid, two left and two right naviculars, two left and two right first and second cuneiforms, one left and two right third cuneiforms, two left first metatarsals and one right first metatarsal, one left and two right second metatarsals, two right third metatarsals, one left and two right fourth metatarsals, one left and two right fifth metatarsals, three first proximal foot phalanges, 13 other proximal foot phalanges, eight middle foot phalanges, one distal first foot phalanx, two other distal foot phalanges, and several ribs.

Sixty-three permanent teeth are present. These represent 12 maxillary incisors, two maxillary canines, nine maxillary premolars, 15 maxillary molars, six mandibular incisors, three mandibular canines, six mandibular premolars, and 10 mandibular molars.

Morphology of the bones suggests that one male (perhaps 25 to 30 years old) and two females are present. The extent of dental attrition on one female skull indicates an age at death of between 24 and 28 years. There is cranial and dental evidence for an additional adult-sized young female, but it is possible these remains originate from one of the other young females found in this area of the tomb.

Estimated lengths of a left femur (37.0 cm) and a right tibia (30.0 cm) both suggest a living stature of about 145 cm (4 ft, 9 in) using Genovés' formulae for Mexican females (Ubelaker, 1989:62).

The maxillary right third molar on the 24- to 28-year-old female is peg-shaped.

P-3, E2 and E3, General: A small quantity of adult bones was recovered from screening and likely relates to E-2 and/or E-3. These consisted of a fragmentary femur, one left metacarpal, one distal hand phalanx, and one left fifth metatarsal.

P-3, E-5 (principal burial): Bones present include both humeri, both radii, both ulnae, both femora, both clavicles, both scapulae, both temporals, both maxillae, both sides of the mandible, gladiolus, manubrium, both innominates, all cervical vertebrae, 13 thoracic vertebrae, four lumbar vertebrae, one sacrum, two coccygeal vertebrae, all carpals except the left

pisiform, all metacarpals, all proximal and middle phalanges, and six distal hand phalanges. Bones of the feet were not present. The hyoid is present, in three parts. Ossified larynx tissues and costal cartilage also are present.

Female sex is strongly suggested by the bones of the pelvis. The pubic bones show very deep pitting on the dorsal margins of the symphysis (Figure 8).

An age at death of 45 to 50 years is suggested by the extent of rib end metamorphosis, arthritic changes, cranial suture closure, dental attrition, and pubic symphysis morphology.

Maximum length of a right radius (23.5 cm) suggests a living stature of about 162 cm (5 ft, 3.5 in) using combined black female and white female formulae of Trotter (Ubelaker, 1989:61).

The dentition reveals the extensive occlusal attrition expected of an individual of this age. The mandibular central incisors and the mandibular third molars were lost antemortem. An apical abscess is located on the lingual alveolus in association with the maxillary left first molar. It appears to have been pro-

duced by exposure of the pulp cavity (Figure 9) through attrition. Interproximal grooves are located on both the mesial and distal (Figure 10) sides of this tooth. Both grooves angle toward the front of the mouth. Grooves also are located between the maxillary right second premolar and first molar. These grooves are located on the distal surface of the premolar and mesial surface of the first molar. The area also shows extensive evidence of periodontal disease.

P-3, E-6 (companion burial): Bones represented are both humeri, left ulna, head of the left femur, both clavicles, left temporal, both maxillae, both sides of the mandible, left innominate, second cervical vertebra, five other cervical vertebrae, 12 thoracic vertebrae, left capitate, and seven left and five right ribs.

Maxillary teeth present include the incisors, canines, first premolars, left second premolar, left first molar, and right second molar. Mandibular teeth present are the central incisors, right lateral incisor, premolars, and molars. The mandibular third molars are not erupted and have 33% root formation.

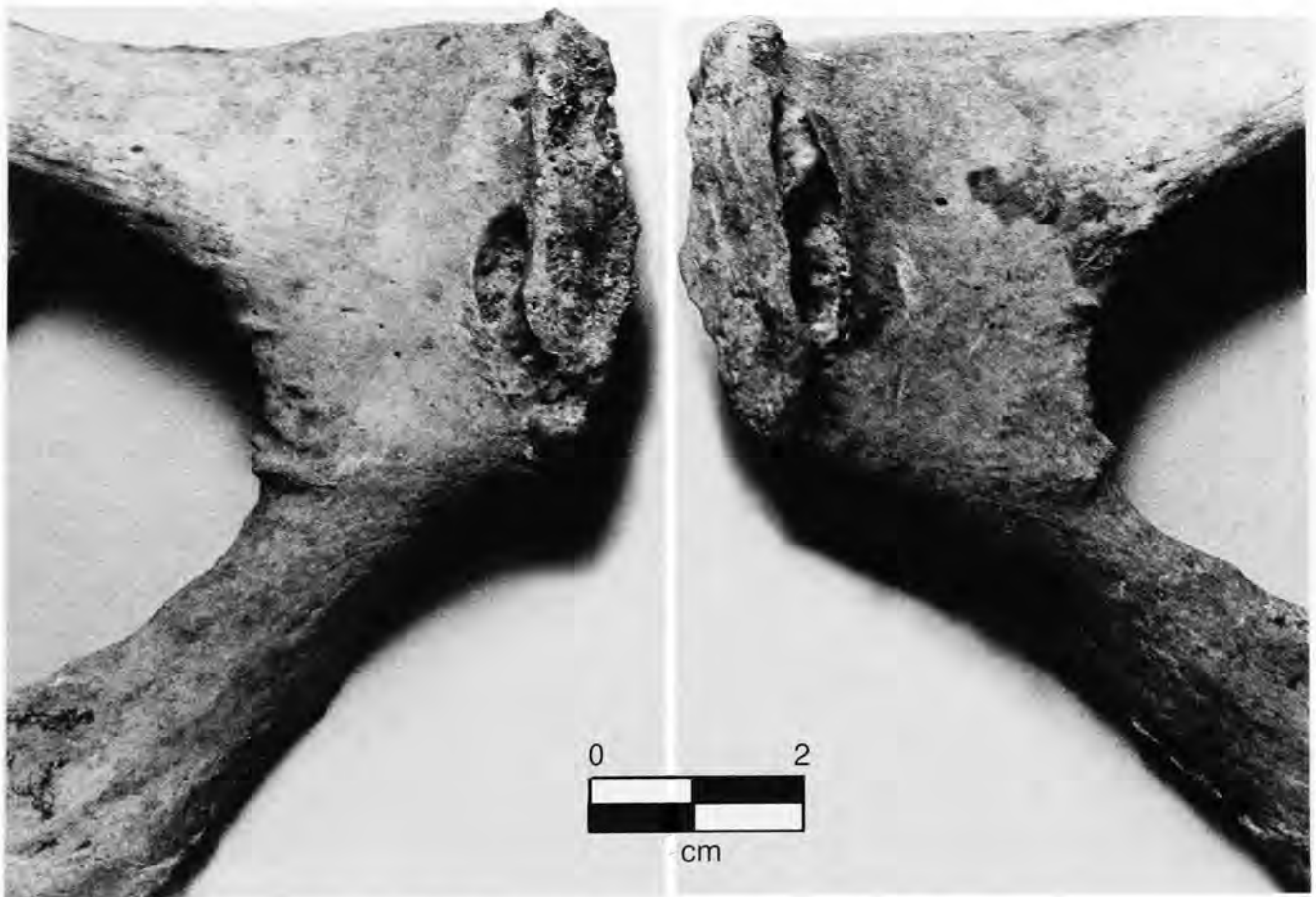

FIGURE 8.—Pubic bones of 45- to 50-year-old female, P-3, E-5, showing deep pitting.

The extent of dental formation and epiphyseal union suggests an age at death of between 14 and 16 years. The gonial angle of the mandible suggests male sex.

P-3, E-7 (sacrifice): According to Doyon (pers. comm., 1988), this bone assemblage was found near the bottom of the central pit and may be commingled with remains from E-4. Bones present consist of two left temporals and two right patellae. Otherwise, only a single individual is represented. Other bones present include both humeri, left radius, left ulna, both femora, right tibia, both fibulae, both scapulae, left mandible, left innominate, first cervical vertebra, two thoracic vertebrae, three lumbar vertebrae, one sacrum, two proximal hand phalanges, all tarsals and metatarsals except the left first cuneiform, all proximal foot phalanges, and seven middle and seven distal foot phalanges.

All permanent teeth of two individuals are present. Additional teeth include three maxillary incisors, four maxillary premolars, six maxillary molars, two mandibular incisors, one mandibular canine, and six mandibular molars.

The morphology of the left pubis strongly indicates female sex.

Lack of union of the left iliac crest and other morphological indicators suggest an age at death of between 17 and 20 years.

The maximum length of the right tibia (32.8 cm) suggests a living stature of about 153 cm (5 ft, 0.5 in) using the formulae of Genovés (Ubelaker, 1989:62).

P-3, General Bones from Bottom of Tomb: A number of extra bones and teeth were recovered from P-3 that could not be associated with any of the E numbers. These bones are one right tibia; one left clavicle; one left scapula; one thoracic vertebra; three middle hand phalanges; two distal hand phalanges; one left and one right cuboid; one left and two right foot naviculars; one left and one right first cuneiform; one left and one right second cuneiform; one left third cuneiform; two right first, second, third, and fifth metatarsals; one right fourth metatarsal; one proximal first foot phalanx; five other proximal foot phalanges; two distal first foot phalanges; and four other distal foot phalanges.

Extra teeth include one maxillary premolar, one immature left maxillary third molar (root 50% formed), and two mandibular premolars.

P-3, General: These fragmentary adult remains were found in an area of P-3, section 7, suggesting they could have originated from E-2, E-3, E-4, or E-7. They consist of fragments of a right fibula, left lunate, left first cuneiform, first proximal foot phalanx, and two (2-5) proximal foot phalanges.

P-3, Bones at Entrance, Cranium 1 (sacrifice): This refers to a complete cranium, both sides of the mandible, and an upper torso complete to lower rib area. The remainder of the skeleton was not found. Bones recovered consist of both humeri, right radius, both ulnae, left scapula, both temporals, both maxillae, and one mandible. Large supraorbital ridges on the crani-

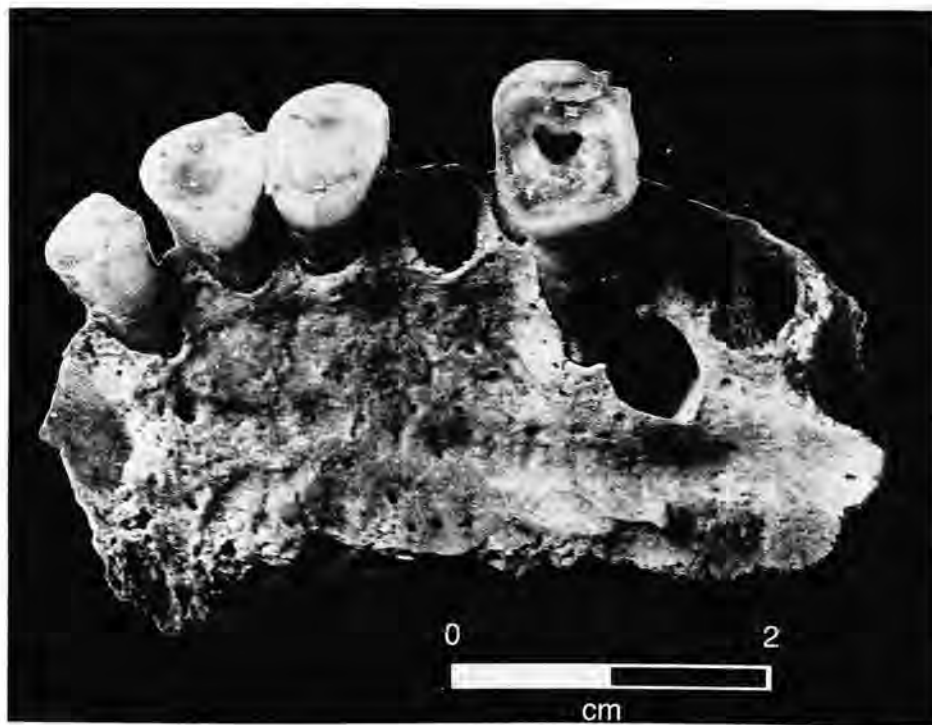


FIGURE 9.—Exposure of pulp cavity through extreme attrition in the maxillary left first molar of the 45- to 50-year-old female, P-3, E-5.

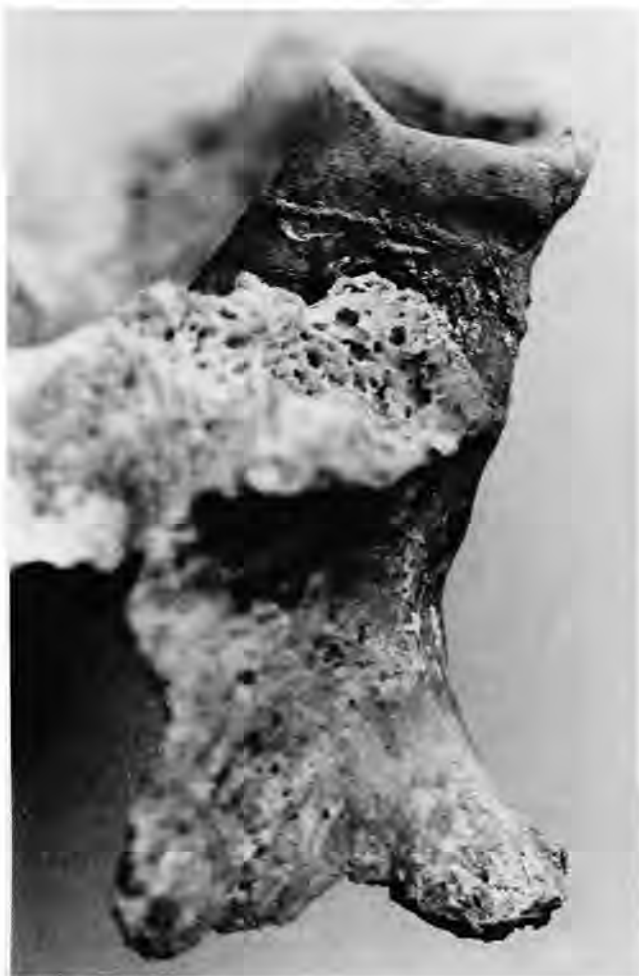

FIGURE 10.—Interproximal groove on the distal buccal surface of the maxillary first molar illustrated in Figure 9, P-3, E-5.

um suggest male sex. The extent of cranial suture closure and dental attrition suggests an age at death of between 22 and 25 years. No evidence of disease was noted. All teeth except the mandibular left second molar are present.

P-3, Bones at Entrance, Cranium 2 (sacrifice): This refers to an isolated, fragmentary cranium and articulated mandible from the upper level. The supraorbital ridges and occipital protuberance both are very large, suggesting male sex, despite moderate to small mastoid processes. The cranium shows pronounced occipital flattening. The extent of dental attrition and other morphology suggests an age at death of between 22 and 25 years. No evidence of disease was noted. All teeth are present except the maxillary left premolars and the mandibular left lateral incisor and left canine.

P-3, Bones at Entrance, Level 3, Cranium 3 (sacrifice): This refers to a small deposit of bone at the tomb entrance. Only several fragments of ribs and long bones are

present. Three mandibular teeth are present, the right second premolar, right first molar, and left first molar. The bones are of adult size, but the extent of dental attrition suggests an age at death of between 15 and 20 years. No estimate of sex can be made. No evidence of disease was noted.

P-3, Other Bones at Entrance: Isolated teeth and bone fragments were found at the entrance. Bones identified were one left temporal, cranial fragments, and 26 teeth. The teeth included all incisors except the mandibular left central, all canines, all premolars except the maxillary left first, and the following molars: maxillary right third; maxillary left first, second, and third; mandibular right first and third; and mandibular left first and third. The third molars have completely formed crowns, but their roots are only one-half to two-thirds formed, suggesting an age at death of between 15 and 18 years. No estimate of sex can be made.

SUMMARY.—Analysis of remains from Tomb P-3 suggested that at least 11 individuals were present. The principal (E-5) and companion (E-6) burials consist of a 45- to 50-year-old female (E-5) and a 14- to 16-year-old male (E-6). The remaining nine individuals include two females likely between 17 and 18 years of age (E-1 and E-2), a 24- to 28-year-old female (E-3 and E-4), a young adult male, perhaps between the ages of 25 and 30 years (E-3 and E-4), a 17- to 20-year-old female (E-7), and four crania likely originating from two males, aged 22 to 25 years, and two individuals of undetermined sex, one aged 15 to 20 years and one aged 15 to 18 years.

TOMB P-4

INVENTORY.—This tomb is unusual in that remains and offerings apparently had been placed on the covering of the central pit. Subsequent collapse caused considerable mixing of individuals. The tomb was 14.6 m deep and about 60.3 m³ in volume. Thirteen groups of remains were available for analysis.

P-4, E-1, A1 (possible severed head): Bones consist of one left clavicle, one right temporal, one right maxilla, one second cervical vertebra, and cranial fragments. Maxillary teeth include the left and right central incisors, right lateral incisor, left and right canines, left and right premolars, and left and right first molars. Mandibular teeth include the right lateral incisor, right canine, right first premolar, and right third molar (not erupted).

The extent of epiphyseal union and dental formation suggest an age at death of between 15 and 18 years. No estimate of sex can be made.

P-4, E-1, A2 (possible severed head): Bones present include the left temporal, left maxilla, both sides of the mandible, and cranial fragments. Teeth present include the maxillary right central incisor and all left maxillary teeth. All mandibular teeth are present except the left central incisor, left canine, and third molars.

The appearance of the cranium suggests male sex. The extent of dental attrition suggests an age at death of between 20 and 25 years.

P-4, E-1, A3 (possible severed head): Bones present include the left maxilla, both sides of the mandible, manubrium, three thoracic vertebrae, and cranial fragments. All teeth from one individual are present except the mandibular left second molar. The third molars show 80% root formation, suggesting an age at death of between 17 and 19 years. No reliable estimate of sex can be made.

P-4, E-1B (principal burial): Bones present represent one adult and consist of both humeri, both radii, left ulna, both femora, both tibiae, both clavicles, left scapula, both temporals, both maxillae, both sides of the mandible, gladiolus, manubrium, right innominate, both patellae, all vertebrae, left lunate, left triquetral, left lesser multangular, left capitate, left hamate, right second metacarpal, right talus, right navicular, left first and left second cuneiforms, right third cuneiform, left second metatarsal, and 22 ribs.

All permanent teeth are present.

Morphology of the innominate and other features strongly indicate male sex.

The extent of dental attrition, morphology of the pubic symphysis, and other features indicate an age at death of between 28 and 33 years.

Maximum length of a left femur (44.2 cm) suggests a living stature of about 166 cm (5 ft, 5 in) using Genovés' formula for Mexican males (Ubelaker, 1989:62).

A well-remodeled healed fracture is located at the sternal end of a right rib (Figure 11).

P-4, E-1C (companion burial): Bones present consist of the left radius, left femur, both clavicles, right scapula, right maxil-

la, both sides of the mandible, gladiolus, manubrium, first cervical vertebra, all thoracic and lumbar vertebrae, both hand naviculars, right greater multangular, left first metacarpal, and 15 ribs. All teeth are present except the maxillary right first premolar, maxillary left first molar, mandibular left lateral incisor, and mandibular left canine.

The small size of the bones generally suggests female sex.

The extent of dental attrition and epiphyseal union suggests an age at death of between 22 and 24 years.

P-4, E-1D (companion burial): One adult is represented by the right humerus; right radius; right ulna; both femora; left tibia; both clavicles; both scapulae; right temporal; right mandible; manubrium; left innominate; both patellae; four cervical vertebrae; eight thoracic vertebrae; three lumbar vertebrae; one sacrum; one coccygeal vertebra; right hand navicular; right triquetral; both lesser multangulars; right capitate; right hamate; left first and second metacarpals; right third, fourth, and fifth metacarpals; eight proximal hand phalanges; six middle hand phalanges; one distal hand phalanx; one second right metatarsal; six ribs; and one hyoid.

Permanent maxillary teeth present consist of the right canine, left premolars, left first molar, and the second and third molars. Permanent mandibular teeth present are the right lateral incisor, right first premolar, left second premolar, both first molars, and the right second and third molars.

Morphology of the right pubis clearly indicates female sex. Slight indentations are located on the dorsal surface of the pubis.

An age at death of between 18 and 19 years is suggested by the extent of epiphyseal union and by dental formation, although slight occlusal wear on the third molars indicates that those teeth had already erupted.



FIGURE 11.—Healed fracture on sternal end of right rib, P-4, E-1B.

The maximum length of a left femur (38.0 cm) suggests a living stature of 148 cm (4 ft, 10 in) using the formula for Mexican females of Genovés (Ubelaker, 1989:62).

Most of the cranial vault is present and shows no deformation. Both orbits display the active porosity of cribra orbitalia (Figure 12).

P-4, E-1, Extra Teeth: Several extra teeth were recovered from E-1. These permanent teeth are the maxillary right incisors, canine, and first premolar, the maxillary left first and third molars, and the mandibular right central incisor, premolars, and first molar.

P-4, E-2 (sacrifice): Bones present are the left humerus, left radius, left ulna, both femora, both tibiae, left temporal, left maxilla, both sides of the mandible, right innominate, both patellae, second cervical vertebra, two other cervicals, and rib fragments. Permanent teeth present are the maxillary right central incisor, canine, and third molar, the maxillary left canine, premolars, and molars, the mandibular right premolars and molars, and the mandibular left incisors and premolars.

The size of the femoral head (38 mm) and a wide sciatic notch and preauricular sulcus on the right innominate indicate female sex. The extent of dental attrition and other morphological indicators suggest an age at death of between 24 and 25 years.

P-4, E-3 (sacrifice): Two adult individuals are indicated by two right temporals and two right mandibles. Other bones present are a left humerus; left ulna; both femora; left tibia; left fibula; left scapula; left temporal; both maxillae; left mandible; both innominates; left patella; one proximal hand phalanx; three middle hand phalanges; three distal hand phalanges; left talus; left second, fourth, and fifth metatarsals; three proximal foot phalanges; and various ribs.

One hundred and ten teeth representing at least four adults are present. All but the following are present from three adults: two mandibular left central incisors, one mandibular left lateral incisor, one mandibular left canine, and one maxillary right first molar. A fourth individual is represented by all maxillary



FIGURE 12.—Cribra orbitalia in both orbits of 18- to 19-year-old female, P-4, E1-D.

teeth except the left third molar and the mandibular right canine, two premolars, and first molar.

Dental attrition suggests the main individual represented in this group was between 24 and 29 years of age. No estimate of sex or stature can be made.

P-4, E-4 (sacrifice): Two individuals are indicated by the presence of two right patellae. Other bones present are both humeri, left radius, both femora, both tibiae, right clavicle, right scapula, one temporal, both sides of the mandible, three thoracic vertebrae, three lumbar vertebrae, one sacrum, one right calcaneus, right talus, left first proximal foot phalanx, two other foot phalanges, and rib fragments. All permanent teeth are present.

The extent of bone maturation suggests an age at death of between 14 and 18 years for one individual. No estimate of sex can be made.

P-4, E-5 (sacrifice): Immature bones present are a right femur, right maxilla, both sides of the mandible, right innominate, right patella, three lumbar vertebrae, a sacrum segment, and nine foot bones. Permanent maxillary teeth present relating to this individual are the central incisors, right lateral incisor, right canine, and both first molars. Permanent mandibular teeth are the right canine, right second premolar, right first molar, and left first molar, as well as other forming maxillary and mandibular teeth imbedded in the alveolus. A deciduous mandibular second molar also is present.

The extent of dental formation suggests an age at death of between nine and 10 years for most of the bones. Some teeth likely originate from a child between the ages of 4.5 and 6 years. A right ilium measuring 72 mm in length represents a young child.

Forty-three adult permanent teeth also are present, representing at least two individuals. The teeth make up one complete

set of adult dentition, lacking only the left maxillary lateral incisor. The rest of the teeth include two maxillary right incisors, two maxillary left premolars, all six maxillary molars, one mandibular right first premolar, and one mandibular right second molar.

P-4, Cranium 1: An isolated group of fragmentary bones was found at the tomb entrance, consisting of a left ulna, right femur, fibula, and innominate. Maxillary teeth present are the incisors, right canine, left premolars, right first premolar, and all six molars. Mandibular teeth present are both central incisors, right canine, right premolars, right molars, and left first and third molars. The extent of dental attrition suggests an age at death of 20 to 23 years. No reliable estimate of sex can be made, and no disease was noted.

P-4, Cranium 2 (severed head): An articulated cranium, mandible, and vertebrae were found near the tomb entrance. Disarticulated long bones also were found associated with the articulated remains. Analysis indicated the following fragmentary bones are present: cranium, both sides of the mandible, first and second cervical vertebrae, one other cervical vertebra, right humerus, right radius, right femur, both tibiae, one fibula, both patellae, and the right calcaneus and talus. Analysis revealed that the right talus and calcaneus were articulated. A circular perforation 8 mm in diameter is located on the sustentaculum tali. The alteration shows no bony response and probably was produced postmortem by associated tree roots.

Also present with this feature is a 74 mm long segment, with a worked proximal end, from the left femoral cortex of a young adult. The modification consists of a polished indentation 3 mm deep and 3 mm wide that extends around the circumference of the bone (Figures 13, 14).



FIGURE 13.—Polished indentation of human femur, P-4, Cranium 2.

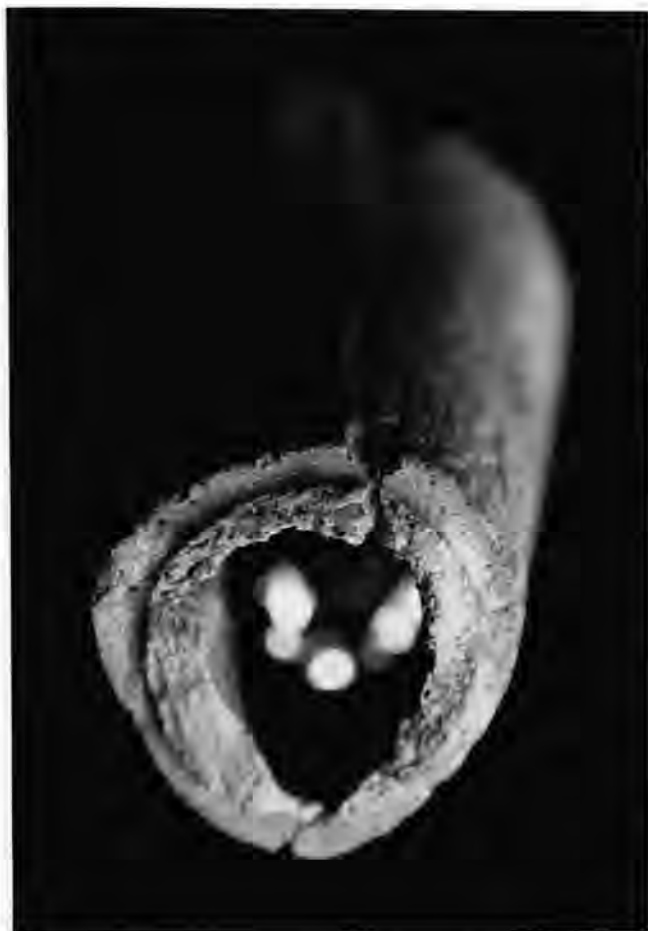

FIGURE 14.—Polished indentation of human femur, P-4, Cranium 2.

No reliable estimate of sex for this individual can be made. The extent of dental attrition suggests an age at death of between 21 and 24 years.

No evidence of disease was noted.

All permanent teeth are present except the mandibular right first premolar.

SUMMARY.—In this tomb, Doyon (pers. comm., 1988) interpreted three individuals as representing high-status burials, the principal burial of E-1B and the two companion burials of E-1C and E-1D. In addition, the three groups of remains recognized by Doyon as possible severed heads (E-1, A-1; E-1, A-2; E-1, A-3) were found in contexts suggesting they also might represent high-status individuals. Because the status of these three units could not be determined with certainty, they were not included in the “high-status” category for biological analysis of this group.

Analysis suggests that at least 13 individuals are present within this tomb. These represent the 28- to 33-year-old male principal burial (E-1B), two female companion burials (E-1C and E-1D) aged 22 to 24 and 18 to 19 years, a 15- to 18-year-

old of undetermined sex (E-1, A-1), a 20- to 25-year-old male (E-1, A-2), a 17- to 19-year-old of undetermined sex (E-1, A-3), a 24- to 25-year-old female (E-2), a 24- to 29-year-old of undetermined sex (E-3), a 14- to 18-year-old of undetermined sex (E-4), a nine- to 10-year-old (E-5), two crania of undetermined sex aged 20 to 23 years and 21 to 24 years, and a child of about five years (E-5).

Test Excavations

Four groups of remains were found within test excavations not associated with tombs.

Test Pit 120 × 258, Level 13: Human remains recovered from this test pit consist solely of one adult lower cervical vertebra.

Test Pit 121 × 258, Level 12: Recovered human remains consist solely of the right superior orbit area of an adult (frontal, right malar, right nasal), right petrous portion of the temporal, and the right parietal.

Test Pit 121 × 258, Level 13: The left and right sides of an adult maxilla, with all teeth except the third molars, are present. Sex cannot be estimated reliably, but the extent of dental attrition suggests an age at death of between 25 and 30 years. These remains, and those of Level 12 described immediately above, likely originate from the same individual.

Test Pit 191 × 264, Level 10. Only a young adult occipital was recovered. Sex cannot be estimated reliably.

Biological Analysis and Interpretation of Human Remains

INDIVIDUAL REPRESENTATION

Assessment of the minimum number of individuals represented in each of the tombs and in the total La Florida sample is possible through careful inventory of the remains present.

Tomb C-1 contains at least eight individuals, two of high status and six others. The two high-status individuals are two young females, aged 17 to 19 years (E-2) and about 15 years (E-5). The other individuals are a female aged about 15 to 16 years (E-1), a 23- to 26-year-old adult of undetermined sex (E-3), a 22- to 26-year-old adult of undetermined sex (E-4), two adults (likely between 20 and 40 years of age) of unknown sex (S-1, S-2), and a 10-year-old child (S-4).

Interpretation of tomb C-2 is complicated by the likely mixing of remains of different individuals. For example, comparison of skeletal inventories of each feature suggests that the postcranial remains of E-3 could belong to the individual of E-2, whereas the cranium could belong with E-4. The cranium and upper arm bones of E-7 likely belong with E-6, whereas leg bones and vertebrae of E-7 probably originated from E-11. Bones of E-10, E-13, and E-14 may be commingled, but they appear to represent three individuals.

Remains from tomb C-2 consist of 21 persons: one severed cranium, four high-status individuals, and 16 others thought to represent sacrifices. The principal and companion high-status

burials in this tomb are from E-19 and consist of two adult males, aged 19 to 22 years and 22 to 30 years, and two adult females, aged 22 to 26 years and 25 to 30 years. At least 17 other individuals are represented in this tomb. These include a 16- to 17-year-old female (E-1), a 22- to 25-year-old adult of undetermined sex (E-2), a 15- to 17-year-old female (E-4), a 14- to 17-year-old female (E-5) (legs only), a 16- to 19-year-old female (E-6), a 25- to 30-year-old female (E-8), a 21- to 24-year-old female (E-9), a 13-year-old of undetermined sex (E-10), a 23- to 26-year-old female (E-11), a 16-year-old of undetermined sex (E-12), a nine-year-old (E-13), an eight-year-old (E-14), a 22- to 25-year-old male (E-15), a seven-year-old (E-16), a 13- to 14-year-old (E-17), a 17- to 20-year-old of undetermined sex (E-20), and the severed cranium of a 12- to 25-year-old.

Remains from tomb P-1 represent at least 20 persons, 14 of which were recognized during excavation. The principal and companion burials from E-8 consist of a male and female, both between the ages of 20 and 24 years. Other individuals present include an 18- to 21-year-old of undetermined sex (E-1); an 18- to 25-year-old of undetermined sex (E-3); a young adult (perhaps between 20 and 24 years of age) of undetermined sex (E-4); two individuals from E-5, a 27- to 32-year-old female and a six- to seven-year-old child; an approximately 30-year-old female (E-6); a 20- to 23-year-old male (E-7); two adults of undetermined sex from E-9, a 16- to 19-year-old and a 21- to 26-year-old; a 20-year-old male represented by severed skull number 1; a 25- to 30-year-old male represented by severed skull number 2; and a 25- to 30-year-old mandible of undetermined sex (level 3).

Excavation of tomb P-1 also produced 457 permanent and 23 deciduous teeth representing at least 20 individuals (Tables 1, 2). These teeth include those found associated with the individuals described above as well as a large quantity of unassociated teeth. At least 18 individuals are represented by permanent teeth and three by deciduous teeth. The minimal number of individuals is 20 because considering the stage of formation of the permanent teeth, it is possible that some individuals were represented by both permanent and deciduous teeth. Of the 18 individuals that were represented by permanent canines, the youngest displayed a degree of root development suggesting an age at death of about eight years. Three individuals were represented by deciduous maxillary left second molars, which usually remain in the mouth until about age 10 or 11. Two individuals were represented by maxillary deciduous lateral incisors, which usually are lost by age 8.

The summary statistics for tomb P1, presented in Table 3, use the age values listed in the text. For the extra individuals indicated by the tooth counts, the ages used for the two children were 8 years (indicated by root development) and 7.25 years (average of other two immature ages). For the four extra adults, the age of 23.38 years was used for each, the mean of all other adult ages from P1.

Only three high-status individuals were found with tomb P-2. These consist of a 17- to 19-year-old female adolescent, a five-year-old child, and a 7.5-year-old child. Unfortunately, these remains were largely commingled.

Remains from tomb P-3 comprise at least 11 individuals. The principal high-status burial is from E-5, a 45- to 50-year-old female missing her lower legs. The companion burial is a 14- to 16-year-old male from E-6, also missing most leg bones. The other individuals, thought to represent sacrifices, are two 17- to 18-year-old females (E-1 and E-2); a 24- to 28-year-old female, and a young adult male, perhaps 25 to 30 years old (E-3 and E-4); a 17- to 20-year-old female (E-7); and four crania representing two males, each aged 22 to 25 years, and two individuals of undetermined sex, aged 15 to 20 years and 15 to 18 years.

Thirteen individuals are represented in tomb P-4. The principal burial is a 28- to 33-year-old male (E-1B). The two companion burials (E-1C and E-1D) are both female, aged 22 to 24 years and 18 to 19 years. Additional individuals are a possible severed cranium of a 15- to 18-year-old, sex undetermined (E-1, A-1), a possible severed cranium of a male aged 20 to 25 years (E-1, A-2), a possible severed cranium of a 17- to 19-year-old of undetermined sex (E-1, A-3), a 24- to 25-year-old female (E-2), a 24- to 29-year-old adult of undetermined sex (E-3), a 14- to 18-year-old of undetermined sex (E-4), a nine- to 10-year-old (E-5), and two severed crania (numbers 1 and 2) of undetermined sex, aged 20 to 23 years and 21 to 24 years. A single incomplete right ilium and several teeth likely representing a young child of about five years of age were found associated with E-5.

The minimum number of individuals present in each tomb ranged from only three (P-2) to 21 (C-2), with a total of 76 individuals (Table 3). Overall, adult females (24) were more common than adult males (13), although sex could not be estimated reliably for 26 adults. Of the 76 individuals, only 13 are less than 15 years of age, and all of these are at least five years of age. The mean age at death of individuals within each tomb ranged from 10 (P-2) to 23 years (P-3). The mean age at death for the entire sample is about 20 years.

Table 4 presents the distribution of ages at death for the entire La Florida sample. Note that no infants are represented, and only one individual more than 35 years old is present. Such an unusual distribution of ages at death, especially the lack of infants, argues strongly against this sample representing a normal accumulation of deaths and argues for a highly selective, ritual interpretation. Most of the individuals are young adults between the ages of 15 and 30, but children and young adolescents also are represented.

Unfortunately, vandalism precluded a clear identification of status for individuals in some tombs. Data available for tombs C-1, P-3, and P-4 indicate likely variability in the high-status individual. In these tombs, the principal burials are a 17- to 19-year-old female (C-1), a 45- to 50-year-old female (P-3), and a

TABLE 3.—Individuals represented within tombs at La Florida.

Tomb	Number of individuals	Number of males	Number of females	Number of adults, sex undetermined	Number of subadults	Age range	Mean age
C-1	8	0	3	4	1	10-40	21
C-2	21	3	9	4	5	7-30	19
P-1	20	4	3	10	3	6-32	21
P-2	3	0	1	0	2	5-19	10
P-3	11	4	5	2	0	14-50	23
P-4	13	2	3	6	2	5-33	20
Total	76	13	24	26	13	5-50	20

TABLE 4.—Distribution of ages at death for each tomb at La Florida.

Tomb	Number of individuals in each five-year interval										Total
	0-4	5-9	10-14	15-19	20-24	25-29	30-34	35-39	40-44	45-49	
C-1	0	0	1	3	2	0	2	0	0	0	8
C-2	0	3	2	7	6	3	0	0	0	0	21
P-1	0	3	0	1	12	2	2	0	0	0	20
P-2	0	2	0	1	0	0	0	0	0	0	3
P-3	0	0	0	6	2	2	0	0	0	1	11
P-4	0	1	1	4	4	2	1	0	0	0	13
Total	0	9	4	22	26	9	5	0	0	1	76

28- to 33-year-old male (P-4). The companion burials for these individuals are a 15-year-old female, a 14- to 16-year-old male, an 18- to 19-year-old female, and a 22- to 24-year-old female. Of the 16 high-status individuals (principal and/or companion burials), including those from C-2, P-1, and P-2, nine are female, five are male, and two are of undetermined sex. Clearly, high-status mortuary treatment was provided to adults of both sexes and to immature individuals as well. In tomb P-4, three additional individuals, a 15- to 18-year-old of undetermined sex, a male between the ages of 20 and 25 years, and a 17- to 19-year-old of undetermined sex also may represent high-status individuals, but this could not be determined with certainty. Because of this uncertainty, these three individuals were included in the lower-status group for comparisons between status groups.

Ten crania were found in archeological contexts suggesting to Doyon (pers. comm., 1988) that they may represent severed heads. All of these likely were young adults. All four crania for which sex could be estimated reliably were male.

CULTURAL ALTERATIONS

Many individuals from these shaft tombs were found as isolated but articulated skeletal segments. Such a pattern indicates that soft tissue had been present, maintaining bone articulation, but that segments of the individual had been removed and isolated, presumably by intentional dismemberment. Examples of such apparent treatment are the articulated cranium, mandible, and first two cervical vertebrae from P-1, Cranium 2; the cranium, mandible, and first two cervical vertebrae from P-1, Cranium 1; and the upper torso from P-3, Cranium 1.

PERIMORTEM SHARP-FORCE TRAUMA.—The cervical vertebrae from P-1, Cranium 1, as well as from those associated with the severed head of P-1, E-7, above, show evidence of perimortem cut marks. Alterations from P-1, Cranium 1, appear to have been sustained by a large blade-type instrument applied with considerable force. The alteration in E-7 represents a fine incision likely made with a sharp blade.

CRANIAL DEFORMATION.—Evidence for occipital flattening was confined to the 22- to 25-year-old adult male from P-3. Although evidence for intentional cranial deformation was definitely lacking among some crania, many were too fragmentary to allow such observations.

INTERPROXIMAL GROOVES.—Interproximal grooves were observed on two individuals, an adult from P-1, Level 3, and the principal burial from P-3, E-5. In the former, the grooves are located between the mandibular first and second right premolars. In the latter, they are located between the maxillary right second premolar and right first molar and on the maxillary left first molar. These grooves appear to represent tooth-pick type abrasions and likely represent the attempt of the individuals to relieve areas of discomfort in their mouths (Ubelaker et al., 1969).

METATARSOPHALANGEAL ALTERATIONS.—Evidence of metatarsophalangeal alterations indicative of prolonged squatting posture with hyperdorsiflexion of the toes (Ubelaker, 1979, 1985) was found in three female skeletons. Alterations were observed on the right fourth metatarsal of E-3 or E-4 from tomb P-3 and on a left third metatarsal from E-1, tomb C-2. Alterations were absent from E-7 of tomb P-3 and from E-8, E-9, and E-11 of tomb C-2. Alterations also were absent from E-15 of tomb C-2, the only male individual with complete metatarsals present.

LIVING STATURE

Living stature was estimated for 13 individuals: nine females, three males, and one individual of undetermined sex. The formulae of Genovés (Ubelaker, 1989:62) were used when the femur or tibia was available. In other cases, the most appropriate of Trotter's formulae (Ubelaker, 1989:61) were employed. The mean stature of the nine females is 151 cm, with a range from 145 cm to 162 cm. Two of these individuals are of high status, with statures estimated at 148 cm and 162 cm (mean stature 155 cm). The low-status females have a mean stature of 150 cm, with a range from 145 cm to 153 cm.

The three male statures range from 159 cm to 166 cm, with a mean of 162 cm. The high-status male statures are estimated at 159 cm to 166 cm, with a mean of 163 cm. The single low-status male stature is 160 cm.

These values fall within the range reported for other pre-Columbian samples from Ecuador (Ubelaker, 1980a, 1980b, 1981, 1983, 1984, 1988a, 1988b, 1988c, 1988d, 1997). For males, the reported range of mean stature from archeological samples is 157 cm to 164 cm, and for females, 148 cm to 161 cm.

PATHOLOGY

TRAUMA.—Evidence for skeletal disease and trauma was minimal in the La Florida sample. Four individuals show indications of skeletal trauma. The high-status young female from tomb C-1 (E-2) shows a large but well-healed depressed fracture on the superior parietals. The fracture produced marked flattening of the superior portion of the cranium associated with a round depression measuring about 45 mm in diameter. The fracture likely resulted in premature closure of the sagittal suture.

The high-status male from tomb P-4 (1-B) shows a well-healed fracture of the sternal end of a right rib. Other fractures are a Colles fracture of the distal end of the right radius of a 20-year-old adult from tomb C-2 (E-7) and a well-healed midshaft fracture of the left radius of the 25- to 30-year-old adult from tomb C-2 (E-8). Thus the four individuals with trauma represent both high- and low-status individuals. The ratio of bones with fractures to the number of individuals in the sample is 0.07. Previous values of this ratio documented from other prehistoric samples from Ecuador range from 0 to 0.19 (Ubelaker, 1997).

POROTIC HYPEROSTOSIS.—Only two individuals in the sample show evidence of porotic hyperostosis. One of the children from tomb P-2 shows slight active porosity in the left orbit. In addition, the 18- to 19-year-old individual from tomb P4 (E-1D) shows porosity in both orbits. Evidence for porotic hyperostosis of the orbits has previously been lacking from prehistoric samples originating in the Ecuadorean highlands (Ubelaker, 1990). Such evidence has been found within coastal prehistoric samples in frequencies that generally show temporal increase. Presumably, the condition results from severe anemia, brought on by low dietary intake of iron and/or loss of iron through loss of blood and other forms of physiological stress. Parasitism, especially hookworm, likely is a contributing factor on the coast. Both of the individuals with this condition were designated high-status.

BONE TUMOR.—One possible bone tumor is present. The mandible from tomb P-1, Level 3, Cranium 2, shows a smooth-walled lesion on the right medial surface.

No evidence of periosteal new bone formation or other indicators of infectious disease were noted. Other prehistoric Ecuadorean samples have presented such evidence. In other such samples, the ratio of the number of bones with periosteal lesions to all individuals in the sample has ranged from 0.02 (Ay-alán, non-urn) to 0.55 (Cumbayá) (Ubelaker, 1997).

LINES OF INCREASED DENSITY.—Only two tibiae were complete enough for radiographic assessment of lines of increased density. Both tibiae originated from tomb P-3. A tibia from E-7 shows lines of increased density at the following distances from the distal articular surface: 6 mm, 12 mm, and 26 mm. These locations suggest the lines were likely formed at about the ages of 10, 15, and 16 years.

A tibia from E-1 shows only one line at a distance of 4 mm from the distal end. This line likely formed at about the age of 15 years.

DECIDUOUS DENTITION.—Only 70 deciduous teeth are present (Table 5). None were abnormally lost antemortem. Observations on the presence or absence of carious lesions were possible on 69 of the teeth. Of these, only two (2.9%) are carious. No alveolar abscesses were noted, and no deciduous teeth are hypoplastic. Dental calculus was mostly either absent or only slightly present on both the buccal and lingual tooth surfaces.

PERMANENT DENTITION.—A total of 2085 fully formed, permanent teeth are present (Table 5). Of 2214 observations on

TABLE 5.—Frequencies of antemortem tooth loss, carious lesions, alveolar abscesses, and hypoplasia in the La Florida samples.

Tooth type	Number of teeth present	Absent antemortem			Carious lesions			Alveolar abscesses			Hypoplasia		
		Absent	Observations	%	Lesions	Observations	%	Lesions	Observations	%	Defects	Observations	%
Deciduous	70	0	70	0.0	2	69	2.9	0	23	0.0	0	69	0.0
Permanent, high status	383	6	423	1.4	3	382	0.8	1	220	0.5	2	394	0.5
Permanent, low status	1702	13	1791	0.7	31	1591	1.9	2	534	0.4	12	1591	0.7
Total permanent	2085	19	2214	0.9	34	1973	1.7	3	754	0.4	14	1985	0.7

antemortem loss, only 19 (0.9%) were lost antemortem. This figure falls at the low end of the values previously reported from prehistoric Ecuador (5%–42%) (Ubelaker, 1997).

Of 1973 observations of tooth crowns for carious lesions, only 34 (1.7%) are carious. This figure is extremely low in consideration of the relatively late date of the sample. Previously recorded caries frequencies of prehistoric Ecuadorean samples range from 0% to 11% (Ubelaker, 1997). Caries frequency appears to be slightly lower among high-status individuals, but values for high- and low-status individuals are both comparatively low. Of the 34 teeth affected, 19 are maxillary and 15 are mandibular. All but seven of the lesions are located on the molars. Two lesions were found on incisor teeth and five were found on premolars.

Of 754 observations for alveolar abscesses, only three lesions were noted (0.4%). Again, this value is comparatively low. Previously reported values for prehistoric samples range from 0% to about 12% (Ubelaker, 1997). Alveolar abscesses were found in similar frequencies among low-status (0.4%) and high-status (0.5%) individuals. All three lesions were associated with first molars. Two lesions resulted from pulp exposure by dental caries, and one resulted from extreme attrition.

Only 14 examples of dental hypoplasia were found out of 1985 observations (0.7%). Again, this frequency falls within the low range of values previously reported from prehistoric Ecuador (0%–6%) (Ubelaker, 1997). These hypoplastic teeth likely originate from eight individuals. Locations of the defects

on the teeth of these individuals suggest they were formed at ages of about 18 months (four individuals), two years, and between three and five years (three individuals). The frequencies are uniformly low among high- and low-status individuals.

Distribution of dental calculus in the deciduous teeth and the permanent teeth of low- and high-status individuals is presented in Table 6. The table reveals similar patterns of distribution between buccal and lingual surfaces of the teeth as well as between high- and low-status individuals.

CRANIAL AND MANDIBULAR MEASUREMENTS AND OBSERVATIONS

As indicated by Tables 7 and 8, relatively few individuals were sufficiently well preserved to allow recording of detailed measurements and observations. Those data recorded fall within the range of values documented from other prehistoric Ecuadorean samples. Meaningful comparison between high- and low-status individuals is not possible due to the small sample size.

STABLE ISOTOPE ANALYSIS

To elucidate additional aspects of the diet of the individuals represented by the remains recovered at La Florida, analysis of stable isotopes was conducted (Ubelaker et al., 1995). Bone samples consisting mostly of rib fragments were obtained from

TABLE 6.—Distribution of dental calculus in La Florida samples.

Tooth type	Buccal				Lingual			
	0	1	2	3	0	1	2	3
Deciduous	37	32	0	0	37	31	1	0
Permanent, high status	1	361	20	0	3	365	14	0
Permanent, low status	277	1245	57	1	279	1270	29	0
Total permanent	278	1606	77	1	282	1635	43	0

TABLE 7.—Cranial and mandibular measurements of high- and low-status males and females from La Florida. (n=samples size.)

Measurement	Female									Male								
	High status			Low status			Combined			High status			Low status			Combined		
	n	Mean	Range	n	Mean	Range	n	Mean	Range	n	Mean	Range	n	Mean	Range	n	Mean	Range
Cranial length	1	170	—	—	—	1	170	—	—	—	—	—	—	—	—	—	—	—
Cranial breadth	1	134	—	—	—	1	134	—	—	—	—	—	—	—	—	—	—	—
Minimum frontal breadth	1	90	—	1	87	—	2	88.5	87–90	—	—	—	—	—	—	—	—	—
Upper facial height	—	—	—	1	69	—	1	69	—	—	—	—	—	—	—	—	—	—
Nasal height	—	—	—	1	48	—	1	48	—	—	—	—	—	—	—	—	—	—
Nasal breadth	—	—	—	1	23	—	1	23	—	1	29	—	—	—	—	1	29	—
Orbital height	—	—	—	1	35	—	1	35	—	—	—	—	—	—	—	—	—	—
Orbital breadth	—	—	—	1	41	—	1	41	—	—	—	—	—	—	—	—	—	—
Maxillo-alveolar breadth	—	—	—	1	55	—	1	55	—	1	70	—	—	—	—	1	70	—
Bicondylar breadth	1	123	—	—	—	1	123	—	—	1	122	—	—	—	—	1	122	—
Bigonial breadth	1	94	—	1	92	—	2	93	92–94	2	100	95–105	—	—	—	2	100	95–105
Height of ascending ramus	1	55	—	2	58	58	3	57	55–58	2	66.5	65–68	—	—	—	2	66.5	65–68
Minimum breadth of ascending ramus	2	34	33–35	5	34.8	30–39	7	34.6	30–39	2	36	33–39	1	34	—	3	35.3	33–39
Height at mandibular symphysis	—	—	—	1	32	—	1	32	—	2	38.5	38–39	—	—	—	2	38.5	38–39
Total facial height	—	—	—	—	—	—	—	—	—	1	126	—	—	—	—	1	126	—

TABLE 8.—Cranial and mandibular observations of high- and low-status males and females from La Florida. Observations on skeletal features that are not sided straddle columns. (L=left, R=right, A=absent, P=present.)

Observation	Female										Male													
	High status				Low status				Combined				High status				Low status				Combined			
	L		R		L		R		L		R		L		R		L		R		L		R	
	A	P	A	P	A	P	A	P	A	P	A	P	A	P	A	P	A	P	A	P	A	P	A	P
Mylohyoid bridge	1	1			4	3			5	4			2	1	1	1	1			3	2	1		
Accessory mental foramen	1	1	1		6	3			7	4	1		2	2	1	1	1	1	3	3	1			
Frontal grooves	1	1			1				2	1			1	1			2	1	1	2	1	1		
Supraorbital foramina					2				2				1	1					1	1	1			
Infraorbital suture			1		1				1	1			2	1					2	1	1			
Os japonicum trace													2	1					2	1	1			
Wormian bones		1 absent							1 absent															
Squamoparietal synostosis	2	2			3	3			5	5			1	1	1				2	1	1			
Auditory exostoses	1	1			5	4			6	5			1	1	1				2	1	1			
Pharyngeal fossa					1 absent				1 absent															
Marginal foramen of tympanic plate	1	1			3	1	2		4	1	3		1	1	1				1	1	1		1	
Tympanic dehiscence	1	1			4	2			5	3			1	1	2				3	1	1			

32 individuals, nine of apparent high status and 23 of apparent low status (Table 9). Collagen was extracted from the samples and was analyzed for stable isotopes of carbon and nitrogen using

TABLE 9.—Age at death, sex, status, and stable carbon (C) and nitrogen (N) isotope data in La Florida samples.

Burial	Age (years)	Sex	C/N	$\delta^{13}\text{C}_{\text{collagen}}$	$\delta^{13}\text{C}_{\text{bioapatite}}$	$\delta^{15}\text{N}$
HIGH STATUS						
C-1, E-2	17-19	F	3.3	-9.0	-3.3	9.0
C-1, E-5	15	F	3.4	-11.8	-5.5	8.4
P-3, E-5	45-50	F	3.1	-9.3	-4.6	9.4
P-3, E-6	14-16	M	3.3	-10.1	-4.7	8.3
P-4, E-1B	28-33	M	3.2	-8.5	-3.1	9.7
P-4, E-1C	22-24	F	3.3	-10.8	-	8.4
P-4, E-1D	18-19	F	3.3	-10.9	-	8.7
P-2, E-1	17-19	F	2.8	-11.2	-	8.3
P-2, E-2	5	?	3.1	-11.1	-	8.7
LOW STATUS						
C-1, E-1	16-17	F	3.6	-12.9	-	8.6
C-2, E-8	25-30	F	3.4	-12.8	-6.5	7.9
C-2, E-1	16-17	F	3.2	-11.1	-	9.1
C-2, E-4	15-17	F	3.4	-14.2	-	7.1
C-2, E-6	16-19	F	3.4	-10.1	-4.3	9.3
C-2, E-11	23-26	F	3.5	-13.0	-6.7	7.6
C-2, E-7	20	?	3.1	-12.9	-	8.0
C-2, E-9	21-24	F	3.7	-10.6	-5.3	8.4
C-2, E-14	8	?	3.5	-11.3	-	8.7
C-2, E-15	22-25	M	3.5	-14.4	-8.3	7.3
C-2, E-16	7	?	3.4	-12.4	-	5.5
C-2, E-17	13-14	?	3.0	-11.7	-	8.0
C-2, E-12	16	?	3.3	-11.5	-	10.4
C-2, E-13	9	?	2.8	-9.7	-	8.2
C-2, E-20	17-20	?	3.2	-11.0	-	10.4
P-4, E-4	14-18	?	3.0	-10.8	-	8.6
P-4, E-5	9-10	?	3.1	-10.5	-	8.0
P-3, E-7	17-20	?	3.2	-10.8	-	9.3
P-1, E-1	18-21	?	3.1	-10.0	-	9.1
P-1, E-2	18-25	?	2.9	-8.9	-	9.6
P-3, E-2	17-18	?	2.7	-11.2	-	7.4
P-1, E-3	18-25	?	3.1	-11.9	-	9.5
P-1, E-7	20-23	M	2.7	-13.8	-	8.5

a mass spectrometer. The protein samples were adequately preserved to provide meaningful information. Samples from five high-status and five low-status individuals also were analyzed for stable carbon isotopes within bioapatite. Procedures employed and background information on isotope analysis are available in the original publication of this work (Ubelaker et al., 1995).

Table 9 summarizes the results of the isotope analysis. Using the *t*-test, no significant differences in isotope values were detected with age or between the sexes. Significant differences were found, however, between high-status and low-status individuals in the carbon isotope values. The carbon values are from both protein and mineral carbon sources. The direction of the differences suggests greater consumption of maize by high-status individuals.

Analysis of nitrogen isotopes failed to reveal significant differences among the samples (Table 10). This suggests that dietary differences were not apparent regarding trophic level. The nitrogen data are especially relevant because when they are combined with the carbon isotope data they indicate that dietary differences with status involved greater consumption of maize by the elite but no differences in relative meat consumption.

As discussed by Ubelaker et al., 1995, the most likely interpretation of the isotope data is greater consumption of maize beer by the elite. This interpretation is supported by a variety of archeological and ethnohistorical data (see Ubelaker et al., 1995, for details). The lack of substantial differences between high- and low-status individuals in dental pathology also argues that the greater maize consumption by the elite was likely in the form of maize beer rather than in nonliquid forms of maize. If the high-status individuals were consuming more maize in the form of tortillas or a related form of food preparation, they might also show greater frequencies of dental caries and related problems. The high-status individuals actually had a slightly lower frequency of dental caries (0.8%) than did low-status individuals (1.9%).

TABLE 10.—Comparison of stable carbon (C) and nitrogen (N) isotope values of high- and low-status individuals from La Florida. (*=means significantly different ($P < 0.05$), n =number of samples, S.D.=standard deviation.)

Status	$\delta^{13}\text{C}_{\text{collagen}}\text{‰}$			$\delta^{13}\text{C}_{\text{bioapatite}}\text{‰}$			$\delta^{15}\text{N}\text{‰}$		
	n	Mean*	S.D.	n	Mean*	S.D.	n	Mean	S.D.
High status	9	-10.30	1.14	5	-4.2	1.01	9	8.77	0.51
Low status	23	-11.63	1.46	5	-6.2	1.51	23	8.46	1.11

Summary

Analysis of human remains from La Florida supports the archaeological interpretation of the site as representing a highly ritualized mortuary procedure. Not all segments of the population are present (the very young are absent), and those represented demonstrate variable mortuary treatment, likely including dismemberment and ritual sacrifice for some individuals. The status distinctions, so clearly marked in burial position and associated artifacts, were not well marked in the biological characteristics of the people. All of the crania identified archeologically as "trophy heads" are of young adults, and those for which sex could be estimated reliably are male. Two of these crania show evidence of perimortem cut marks, one from a large blade and another from a very fine, knife-like instrument. The high-status individuals represent adults of both sexes and varied ages at death. High- and low-status individuals show similar frequencies of skeletal trauma, dental disease, and skeletal measurements and observations. Analysis of stable carbon

isotopes suggests greater high-status consumption of maize, likely in the form of beer (chicha).

Various indicators suggest exceptionally good health for both high- and low-status individuals within the La Florida sample, although this interpretation could be influenced to some extent by the poor preservation and fragmentation of much of the remains. Frequencies of porotic hyperostosis (two examples), antemortem tooth loss (0.9%), and dental hypoplasia (0.7%) fall within the low range of values previously reported from ancient Ecuador (Ubelaker, 1997). No evidence of infectious disease was noted. This absence, as well as frequencies of skeletal trauma (0.07), antemortem tooth loss (0.9%), dental caries (1.7%), and alveolar abscesses (0.4%), also is comparatively low. These data argue that the individuals represented in the La Florida sample enjoyed exceptionally good health and nutrition, in contrast to most other populations from ancient Ecuador studied to date. Perhaps the high-status individuals represented here, as well as those who immediately served them, reaped health and nutritional benefits from their positions in the social hierarchy of that time.

Literature Cited

- Doyon, Leon G.
1988. Tumbas de la nobleza en La Florida. In Iván Cruz Cevallos, editor, *Quito Antes de Benalcazar*, pages 51–66. Quito: Centro Cultural Artes.
1995. La secuencia cultural Carchi-Nariño vista desde Quito. In C. Gnecco, editor, *Perspectivas Regionales en la Arqueología del Suroccidente de Colombia y Norte del Ecuador*, pages 59–84. Popayán, Colombia: Editorial Universidad del Cauca.
- Ubelaker, Douglas H.
1979. Skeletal Evidence for Kneeling in Prehistoric Ecuador. *American Journal of Physical Anthropology*, 51:679–685.
- 1980a. Human Skeletal Remains from Site OGSE-80, a Pre-ceramic Site on the Sta. Elena Peninsula, Coastal Ecuador. *Journal of the Washington Academy of Sciences*, 70(1):3–24.
- 1980b. Prehistoric Human Remains from the Cotocollao Site, Pichincha Province, Ecuador. *Journal of the Washington Academy of Sciences*, 70(2):59–74.
1981. The Ayalán Cemetery: A Late Integration Period Burial Site on the South Coast of Ecuador. *Smithsonian Contributions to Anthropology*, 29: 175 pages, 119 figures, 170 tables.
1983. Human Skeletal Remains from OGSE-172, an Early Guangala Cemetery Site on the Coast of Ecuador. *Journal of the Washington Academy of Sciences*, 73(1):16–26.
1984. Prehistoric Human Biology of Ecuador: Possible Temporal Trends and Cultural Correlations. In Mark N. Cohen and George J. Armelagos, editors, *Paleopathology at the Origins of Agriculture*, pages 491–513. New York: Academic Press.
1985. Evidencia esquelética de postura arrodillada en el Ecuador. *Miscelánea Antropológica Ecuatoriana, Boletín de los Museos del Banco Central del Ecuador*, 5:35–46.
- 1988a. Human Remains from OGSE-46, La Libertad, Guayas Province, Ecuador. *Journal of the Washington Academy of Sciences*, 78(1):3–16.
- 1988b. Prehistoric Human Biology at La Tolita, Ecuador, a Preliminary Report. *Journal of the Washington Academy of Sciences*, 78(1):23–37.
- 1988c. A Preliminary Report of Analysis of Human Remains from Agua Blanca, A Prehistoric Late Integration Site from Coastal Ecuador. *Journal of the Washington Academy of Sciences*, 78(1):17–22.
- 1988d. Skeletal Biology of Prehistoric Ecuador: An Ongoing Research Program. *Journal of the Washington Academy of Sciences*, 78(1):1–2.
1989. *Human Skeletal Remains: Excavation, Analysis, Interpretation*. Second edition, xi+172 pages. Washington, D.C.: Taraxacum.
1990. Porotic Hyperostosis, Parasitism and Sedentism in Ancient Ecuador. [Abstract.] *American Journal of Physical Anthropology*, 81: 309–310.
1997. Skeletal Biology of Human Remains from La Tolita, Esmeraldas Province, Ecuador. *Smithsonian Contributions to Anthropology*, 41: 53 pages, 28 figures, 31 tables.
- Ubelaker, D.H., M.A. Katzenberg, and L.G. Doyon
1995. Status and Diet in Precontact Highland Ecuador. *American Journal of Physical Anthropology*, 97(4):403–411.
- Ubelaker, Douglas H., T.W. Phenice, and William M. Bass
1969. Artificial Interproximal Grooving of the Teeth in American Indians. *American Journal of Physical Anthropology*, 30(1):145–150.